

# SID



ابزارهای  
پژوهش



سرویس ترجمه  
تخصصی



کارگاه های  
آموزشی



بلاگ  
مرکز اطلاعات علمی



سامانه ویراستاری  
STES



فیلم های  
آموزشی

## کارگاه های آموزشی مرکز اطلاعات علمی



آموزش مهارت های کاربردی در تدوین و چاپ مقالات ISI

آموزش مهارت های کاربردی  
در تدوین و چاپ مقالات ISI



روش تحقیق کمی

روش تحقیق کمی



آموزش نرم افزار Word برای پژوهشگران

آموزش نرم افزار Word  
برای پژوهشگران

## The Histopathological Survey of Uterine Tissue in Holstein Dairy Cows with or without Recorded Reproductive Disorders

Massoud Talebkhan Garoussi<sup>1\*</sup>, Farhang Sasani<sup>2</sup> and Parviz Hovareshti<sup>3</sup>

<sup>1</sup> Department of Clinical Sciences, Faculty of Veterinary Medicine, Ferdowsi University of Mashhad, Mashhad, Iran  
<sup>2</sup> Departments of Pathobiology and <sup>3</sup> Clinical Sciences, Faculty of Veterinary Medicine, University of Tehran, Tehran, Iran

Received: July 30, 2010

Accepted: October 11, 2010

### Abstract

The objective of the study was to evaluate the uterine histopathological changes in Holstein dairy cows, within the range of 90-145 day in milk, with or without clinical history of reproduction system disorders. Lactating Holstein cows (n =133) with (n=92, 69.17%) or without (n= 41, 30.82%) recorded clinical signs of reproduction diseases were examined for uterine histopathological lesions. The cows in treatment group were inseminated artificially for 3 times after calving or did not have any recorded estrus signs. The cows in control group were not inseminated. Biopsy of the endometrium and submucosa were obtained using a sterile alligator-jawed (rounded) biopsy forceps. The inseminated cows were at various stages of the estrus cycle. The results showed that 64.13% and 46.34% of cows with or without recorded clinical reproductive disorder had histopathological lesions, respectively. There were no significant differences in histopathological changes between cows with or without reproductive disorder history ( $P \geq 0.05$ ). Chronic endometritis was the most common microscopic lesion in cows with (34.61%) or without (17.94%) recorded reproductive disease. Clinical endometritis was the most common reproductive disorder (20.65%). The rate of histopathological lesions in repeat breeder cows was 16.3%.

In conclusion, endometrial biopsy could be a useful diagnostic tool to evaluate future fertility of the dairy cows because, cows with or without reproductive disorders may show histopathological lesions.

**Keywords:** dairy cow, endometritis, histopathology, reproductive disorders, uterus.

---

\*Corresponding author: Massoud Talebkhan Garoussi  
Email: garoussi@um.ac.ir  
Tel: +98 511 876 3851  
Fax: +98 511 876 3852

## Introduction

The main aim of reproduction management in dairy cattle herds is to get animals pregnant at a suitable interval after calving (Plazier *et al.*, 1986). Endometritis is the inflammation of endometrium without systemic signs due to pathogenic agents (Bondurant *et al.*, 1999). In order to treat and to quantify the severity of the disease, it is crucial to diagnose uterine problems as soon as possible to have a good subsequent fertility. There are many factors causing reproductive inefficiency in dairy cows (Radostitis *et al.*, 1994), particularly managerial factors such as inefficient estrus detection (Ferguson and Galligan, 1999). Uterine disorders, primarily nonspecific uterine infections, reduce the reproductive efficiency of dairy cows. In some herds, significant postpartum cows may be diagnosed and treated for uterine infections. Uterine infections usually increase herd health costs, often reduce feed consumption, cause an appreciable reduction in milk production, and increase culling rate. Clearly, uterine dysfunction can have a major impact on the profitability of a dairy operation. Timely and accurate diagnosis is essential to ensure appropriate management of uterine infections. Some researchers suggest that diagnosis of uterine infections are too subjective and often are inaccurate (Paisley *et al.*, 1986; Gilbert, 1992). Rectal palpation of the uterus, examination of the vagina with a speculum, culture of uterine secretions and evaluation of uterine biopsies are the techniques available for diagnosing uterine infections. Uterine biopsies can provide meaningful prognostic information about the reproductive health (Bonnett *et al.*, 1993).

Since reproduction system disorders including uterine infections are so important, therefore, much more scientific reports have been published especially in fields such as metritis, endometritis and pyometra which are the most common uterine disorders. Following parturition, natural mating, artificial insemination and infusion of irritant materials into the uterus, endometritis may occur.

Endometritis can be diagnosed by rectal examination, ultrasonography, vaginoscopy, cytology evaluation, and uterine biopsy. Evaluation of uterine biopsy samples is not a common practice in cows as compared to mares. However, it is a useful procedure at 26-40 days postpartum (Etherington *et al.*, 1988; Youngquist and Threlfall., 2007).

The aim of this study was to evaluate the uterine histopathological changes in Holstein dairy cows with or without any history of reproduction system disorders.

## Materials and Methods

### Animals

The study population consisted of 133 lactating Holstein cows from eight industrial commercial dairy herds in Tehran and Khorassan Razavi province in North-east of Iran, including 92 (69.17%) cows with recorded reproductive diseases and 41 (30.82%) cows without any recorded clinical signs assigned as treatment and control groups, respectively. Herd size ranged 80 to 950 Holstein milking cows and all cows were in their 90-145 days in milk. Treatment group cows had been inseminated artificially 3 times in standing heat without success or, had not shown any signs of estrus 90 days postpartum. The treatment group had a history of reproductive diseases including: abortion ( $n=11$ , 11.95%), stillbirth ( $n=10$ , 10.86%), dystocia ( $n=9$ , 9.78%), retention of fetal membranes (RFM) ( $n=14$ , 15.21%), clinical endometritis ( $n=19$ , 20.65%), metritis ( $n=5$ , 5.43%), repeat breeder (animal that had a regular estrus cycle but failed to conceive after three consecutive inseminations) ( $n=17$ , 18.47%), vaginitis ( $n=4$ , 4.34%) and cervicitis ( $n=3$ , 3.26%). They were treated using routine local, systemic and supportive techniques. At examination, cows were first inspected for the presence of discharge on the vulva, perineum, or tail.

Control group cows were healthy cows without any clinical signs of reproductive diseases and had not been inseminated postpartum.

*Biopsy and pathological evaluation*

At the time of biopsy, the perineal area and vulva were washed with soap and rinsed 3 times with water. The vulva was then disinfected with a 2% solution of povidone Iodine and then cows were restrained for sampling. The specimens were obtained using a sterile alligator-jawed (rounded) biopsy forceps 55 to 70 cm in length with a basket 20 X 4 X 3 mm in size. The vulvar lips were pulled apart and forceps was inserted into the anterior vagina with one hand, and the other hand was inserted into the rectum. The forceps was guided through cervix into the uterine horns. The jaws of the forceps were opened and medial wall of the uterine horns were gently pushed laterally into the jaws by the hand which was in the rectum and jaws were shut gently. The biopsy forceps was withdrawn from the genital system. In order to prevent the secondary infection, after withdrawal of the forceps, a 5% Oxytetracycline solution (Razak Co, Iran) was infused into the uterus.

The uterine specimen was removed from the forceps with a needle, placed in 10% formalin and sent for histopathological examinations. 6µm thick tissue sections were stained with Hematoxylin & eosin and evaluated by light microscope.

*Histopathological assessment*

Subjective and quantitative histological assessments were performed by a pathologist who had no history of the cows.

*Statistical analysis*

Data were analyzed by Chi-square statistical method using SPSS software version 9. P values equal or smaller than 0.05 were considered significant.

**Results**

Totally, 78 cows in the treatment (n= 59, 64.13%) and control (n=19, 46.34%) groups showed histopathological lesions of different types, (Table 1 and 2). There were no significant differences regarding the histopathological changes of treatment and control groups (P≥0.05). Endometritis was the main cause of lesions as indicated in the histopathological evaluation and chronic endometritis was the most frequent pathological finding in both groups (Table 2 and Fig. 1). It was shown that cows with a history of repeat breeding were mostly affected by histopathological lesions (16.3%) (Table 3), but, 14.13% of cows with clinical endometritis showed microscopic changes. Cows with cervicitis did not show uterine lesions, histopathologically.

**Discussion**

The goal of reproduction management in dairy herds is to get cows become pregnant at a biologically optimal time at an economically profitable interval after calving. In an effort to improve diagnosis of bovine infertility in postpartum cows endometrial biopsy is suggested to be performed (Skjerven, 1956). Over 50 years later there are still no explicitly defined criteria which, when assessed from endometrial biopsies, are known to be predictive of reproductive performance. Time of sampling has ranged from early postpartum to immediately prior to breeding to hundreds of days following the preceding parturition (repeat breeders) (Brenda *et al.*, 1991).

Most of uterine histopathological studies are more relevant to humans than to livestock, and most of the animal references are relevant

**Table 1: The frequency of uterine histopathological lesions in Holstein dairy cows.**

Cows	Histopathological lesions		Total (%)
	+	-	
With reproductive disorders	59 (64.13)	33 (35.86)	92 (69.17)
Without reproductive disorders	19 (46.34)	22 (53.65)	41 (30.82)
Total	78 (58.64)	55 (41.35)	133

Non-significant (P≥0.05).

**Table 2: Distribution of different uterine histopathological lesions in Holstein dairy cows with or without reproductive diseases.**

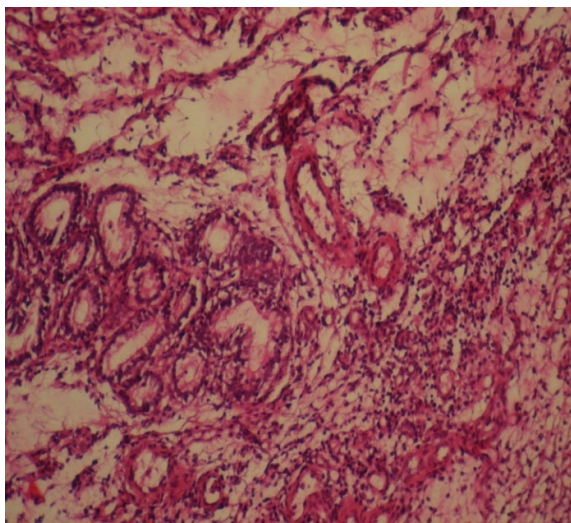
Uterine histopathological lesions	Experimental groups	
	No. of control cows (%)	No. of treatment cows (%)
Chronic endometritis	14(17.94)*	27 (34.61)*
Chronic follicular endometritis	1 (1.28)	5 (6.41)
Chronic proliferative endometritis	-	2 (2.56)
Acute proliferative endometritis	-	1 (1.28)
Acute endometritis	2(2.56)	6 (7.69)
Acute secretional endometritis	-	4 (5.12)
Acute papillar hyperplastic endometritis	-	2 (2.56)
Pustular endometritis	-	2 (2.56)
Acute fibrosis and atrophy of endometrial glands	-	1 (1.28)
Acute fibrinous endometritis	1(1.28)	2(2.56)
Metritis	-	2 (2.56)
Fibrosis of endometrium	-	4 ((5.12)
	1(1.28)	1 (1.28)
Total	19	59

\*Significant difference between groups (P≤0.05).

**Table 3: Distribution of different reproductive diseases and histopathological lesions in Holstein dairy cows**

Reproductive disease	No. of tested cows (%)	Uterine histopathological changes	
		+ (%)	- (%)
Abortion	11 (11.95)	7 (7.6)	4 (4.34)
Stillbirth	10 (10.86)	6 (6.52)	4 (4.34)
Dystocia	9(9.78)	7 (7.6)	2 (2.17)
RFM*	14(15.21)	9 (9.78)	5 (5.43)
Clinical endometritis	19(20.65)	13 (14.13)	6 (6.52)
Metritis	5(5.43)	1 (1.08)	4 (4.34)
Repeat breeder	17(18.47)	15 (16.3)	2 (2.17)
Vaginitis	4(4.34)	1 (1.08)	3 3.26)
Cervicitis	3(3.26)	-	3 (3.26)
Total	92	59	33

\*RFM: Retained fetal membranes



**Figure 1: Chronic proliferative endometritis showing heavy infiltration of lymphoblastic cells in endometrium (H&E X 320).**

to mares than to food animals. Endometrial biopsy is the most definitive diagnostic tool for endometritis in the mare which is recognized as time consuming and expensive (Sheldon and Dobson, 2004; Gilbert *et al.*, 2005). This study showed that 46.34% of healthy cows had uterine lesions in biopsy evaluation. Moreover, it was demonstrated that endometritis was the most common lesion in the postpartum cows. The clinical signs of uterine disorders, such as endometritis, often can not be demonstrated by rectal or vaginal examination. In more severe cases, mucopurulent discharge from the uterus may be present in the vagina. For the detection of uterine exudates and endometritis, vaginal examination is an indicative tool (Youngquist and Threlfall, 2007).

At the time of estrus, flakes of pus in the estrual mucus, indicates presence of a possible

endometritis. The source of these flakes may be difficult to delineate clinically as much as they may come from the vagina, cervix or uterus. However, uterine disorders diagnosis on the basis of clinical examination is not reliable. A careful examination and biopsy may eliminate other possible causes of infertility. Diagnosis of possible uterine problem(s) may be performed by examination of biopsy material. The present study showed that even healthy cows without any history of reproductive disorders had uterine histopathological changes (Table 1 & 2). On the other hand, some cows with different reproductive diseases also had no histopathological changes (Table 3).

It is important to be able to diagnose the presence of bovine uterine infection to facilitate timely and appropriate treatment and to quantify the severity of disease, which allows a prognosis to be given for subsequent fertility. Unfortunately, a golden standard for diagnosis of bovine uterine disorders is not available, making it difficult to measure the sensitivity and specificity of clinical definitions (Skjerven, 1954). There is little information about the correlation of clinical and histopathological observations, although the presence of pus in the vagina was correlated with the presence of pathogenic agents in the uterus (Dohmen *et al.*, 1995; Williams *et al.*, 2005).

The present study showed that cows in  $\geq 90$  days postpartum with or without reproductive disorders had uterine histopathological changes (Table 1, 2 and 3). There are different degrees of endometrial inflammation associated with normal involution. However, we must be able to identify the truly diseased cows so that appropriate treatments may be administered (Sheldon and Dobson, 2004). Endometritis has been divided into two categories including clinical and subclinical (Sheldon *et al.*, 2006). Clinical endometritis is characterized by the presence of mucopurulent or purulent uterine discharge 21 days, or more, postpartum. Subclinical endometritis is defined as inflammation of the uterus without uterine exudates. These reproductive disorders

are not accompanied with systemic signs (Youngquist and Threlfall, 2007). The incidence of clinical and subclinical endometritis has been reported 53% at 34-47 days postpartum. In our study, the prevalence of histopathological uterine changes with or without recorded reproductive disorders was 64.13% and 46.34%, respectively (Tables 1 & 2), including different kinds of endometritis. In this study, it was shown that endometritis is the most common pathological lesion in healthy animals and those with impaired reproduction system. The above mentioned lesions are not life-threatening but the inflammation may influence embryo survival (Gilbert *et al.*, 1995; Hansen *et al.*, 2004). Affected cows may conceive after AI, but they are not able to keep the conceptus. Uterine pathological lesion may be accompanied with establishment of uterine bacterial infection which may depend on the endocrine environment; in particular, progesterone seems to suppress uterine immunity. It has been found that chronic uterine infection and increased plasma concentration of lipopolysaccharide were associated with disruption of the LH surge and failure of ovulation (Karsch *et al.*, 2002; Sheldon and Dobson, 2004). Bacterial contaminations of the uterus may originate from outside, faulty AI and/or uterine infusions in most of the postpartum cows. Elimination of this contamination is dependent on endometrial regeneration and uterine defense mechanisms. Non-infectious causes such as: mismanagement of dairy cattle herds, heat detection, AI in wrong time, high milk production, and malnutrition may be the reasons of unsuccessful conception and low reproductive performance. However, the cleanness of the farm, particularly the calving area and proper hygiene during assisted calving are thought to influence the uterine postpartum problems (Youngquist and Threlfall, 2007).

The definitive diagnosis of endometritis can be made on the basis of histopathological examination of endometrial biopsies and could be predictive for next fertility (Bonnett *et al.*, 1993).

Cows in the present study did not get

pregnant after 3 times AI or  $\geq 90$  days postpartum. Cows with endometritis had a longer period to pregnancy. Affected cows can reduce pregnancy rate up to 30% at the first insemination. Clinical endometritis can reduce pregnancy rate and correspondingly 70% more likely to be culled due to reproductive failure (LeBlanc *et al.*, 2002). In a study, cows with endometritis had a hazard ratio for pregnancy of 0.83, which the median days open was increased from 110 to 125 days (Lee *et al.*, 1989). However, they measured risk of culling due to non-pregnancy which is most likely the true cause of removal from the herds.

In the present study, it was found that cows with reproductive disorders had histopathological lesions (Table 3) but surprisingly, out of 16.3% of cows that were repeat breeders, only 1.08% had a history of endometritis. All of these defects may be associated with reduced pregnancy rate. Frazer (2005) has concluded that embryo mortality rate is high in repeat breeder cows during development in early stages, i.e. 6 to 7 days after breeding. Uterine trauma such as, dystocia, manual removal of retained placenta and intra-uterine infusions reduce the uterine defense mechanism activities (Paisley *et al.*, 1986; Hussain, 1989). The majority of dairy cattle experience bacterial contamination of the uterus at the time of parturition. If these bacteria are not cleared by the cow's defense mechanisms, a uterine infection ensues. Inflammation of multiple tissue layers including the endometrium and myometrium that can extend beyond the puerperal period, is known as metritis (Youngquist and Threlfall, 2007). However, the presence of histopathological changes may be due to incomplete treatment of metritis. Proper attention to facilities maintenance and sanitation quality, periparturient hygiene, especially during assisted calving may be the best way for prevention of reproductive system infection (Lewis, 1997).

In this study, chronic endometritis was the major lesion of the cows. It was shown that there were strong association between reproductive diseases and endometritis

(Sheldon and Dobson, 2004). However, subclinical endometritis can affect conception rates to first service and overall pregnancy (Gilbert, 2004). Therefore, the absence of pus in the vagina does not always reflect the absence of inflammation in the uterine lumen (Sheldon and Dobson, 2004). However, biopsy technique is expensive and time consuming, not clinically accessible in most conditions, and may have a negative effect on the future fertility (Sheldon *et al.*, 2006).

In conclusion, this study showed that uterus with or without disorders might have histopathological lesions. The most common lesion of uterus was endometritis in  $\geq 90$  day postpartum cows. However, results must be interpreted with regard to the days postpartum. Further research is needed to refine the inputs into economic decision-making tools to answer these questions under a variety of management conditions.

## References

- Bondurant, R. H. (1999) Inflammation in the bovine female reproductive tract. *Journal of Dairy Science* **82** (Suppl. 2), 101-110.
- Bonnett, B. N., Martin, S. W. and Meek, A. H. (1993) Associations of clinical findings, bacteriological and histological results of endometrial biopsy with reproductive performance of postpartum dairy cows. *Preventive Veterinary Medicine* **15**, 205-220.
- Brenda, N., Bonnett, R. B., Miller, W. G., Etherington, S., Wayne, M. and Walter, HJ. (1991) Endometrial biopsy in Holstein-Friesian dairy cows I. technique, histological criteria and results. *Canadian Journal of Veterinary Research* **55**, 155-161.
- Dohmen, M. J. W, Lohuis, JACM., Huszwnicza, G., Nagy, P., and Gacs, C. (1995) The relationship between bacteriological and clinical findings in cows with subacute/chronic endometritis. *Theriogenology* **43**, 1379-1388.
- Etherington, WG., Martin, SW., Bonnett, BN., Johnson, WH., Miller, RB., Savage, NC., Walton, JS., and Montgomery, ME. (1988) Reproductive performance of dairy cows

- following treatment with cloprostenol 26 and/or 40 days postpartum: A field trial. *Theriogenology* **29**, 565-575.
- Ferguson, JD. and Galligan, DT. (1999) Assesement of reproductive efficiency in dairy herds. *Compendium on Continuing Education for the Practicing Veterinarian* **22**, S150-S158.
- Frazer, GS. (2005) Bovine Theriogenology, *Veterinary Clinics of North America, Food Animal Practice* **21**, 441-442.
- Gilbert, RO. (2004) Uterine disease in the postpartum period. In: *Proceedings of the 15th International Congress on animal reproduction*. Porto Seguo, Brazil, 66-73,
- Gilbert, RO. (1992) Bovine endometritis: the burden of proof, *Cornell Veterinary Medicine* **82**, 11.
- Gilbert, RO., Shin ST., Guard CL, Erb, HN., and Frajblat, M. (2005) Prevalence of endometritis and its effects on reproductive performance of dairy cows. *Theriogenology* **64**, 1879-1888.
- Gilbert, RO., Yang, X., Jiang, S., Schlafer, DHV., Saluste, V. and Scheytt, A. (1995) Effects of aseptic inflammation on development of bovine embryos in vivo and in vitro. In: *Proceedings of the Annual Meeting of the Society for Theriogenology*. San Antonio, Texas, USA, 312.
- Hansen, PJ., Soto, P. and Natzke, RP. (2004) Mastitis and fertility in cattle, possible involvement of inflammation or immune activation in embryonic mortality, *American Journal of Reproductive Immunology* **51**, 294-301.
- Hussain, AM. (1989) Bovine uterine defense mechanisms: a review. *Journal of Veterinary Medicine, Ser B* **36**, 641-651.
- Karsch,FJ.,Battaglia, DF., Breen, KM., Debus, N. and Harris, TG. (2002) Mechanisms for ovarian cycle disruption by immune/inflammatory, *Stress*, **5**, 101-112.
- LeBlanc, SJ., Duffield, TF., Leslie, KE., Bateman, KG., Keefe, GP., Walton, JS. and Johnson, WH. (2002) Defining and diagnosing postpartum clinical endometritis and its impact on reproductive performance in dairy cows, *Journal of Dairy Science* **85**, 2223-2236.
- Lee, LA., Ferguson, JD. and Galigan, DT. (1989) Effect of disease on days open assessed by survival analysis, *Journal of Dairy Science* **72**, 1020-1026.
- Lewis, GS. (1997) Symposium: health problems of the postpartum cow, uterine health and disorders. *Journal of Dairy Science* **80**, 984-994.
- Paisley, LG., Mickelsen, WD. and Anderson, PB. (1986) Mechanisms and therapy for retained fetal membranes and uterine infections of cows: a review, *Theriogenology* **25**, 353-381.
- Plazier, JCB., King, GJ., Dekkers, JCM. and Lissemore, K. (1997) Estimation of economic values of indices for reproductive performance in dairy herds using computer simulation, *Journal of Dairy Science* **80**, 2775-2783.
- Radostitis, OM., Leslie, KE. and Fetrow, J. (1994) *Herd health –food animal production medicine*, 2nd edn., W. B. Saunders Co., Philadelphia, PA, USA.
- Sheldon, M., Lewis, GS., Leblanc, S. and Gilbert, RO. (2006) Defining postpartum uterine disease in cattle, *Theriogenology* **65**, 1516-1530.
- Sheldon, IM. and Dobson, H. (2004) Postpartum uterine health in cattle. *Animal Reproductive Science* **82-83**, 295-306.
- Skjerven, O. (1956) Discussion on biopsy techniques and histological structure of the uterus, *Acta Endocrinology [suppl]* **26**, 1-9.
- Williams, EJ., Fisher, DP., England, GCW., Dobson H, Pfeiffer, DU. and Sheldon, IM. (2005) Clinical evaluation of postpartum vaginal mucus reflects uterine bacterial infection and the inflammatory response to endometritis in cattle. *Theriogenology* **63**, 102-117.
- Youngquist, RS. and Threlfall, WR. (2007) *Current Therapy in Large Animal Theriogenology*, Saunders, Elsevier, USA.





## بررسی هیستوپاتولوژیکی بافت رحم در گاوهای شیری هلشتاین با و یا بدون اختلالات تولید مثلی

مسعود طالب خان گروسی<sup>۱\*</sup>، فرهنگ ساسانی<sup>۲</sup>، پرویز هورشتی<sup>۳</sup>

<sup>۱</sup> گروه علوم درمانگاهی، دانشکده دامپزشکی، دانشگاه فردوسی مشهد، مشهد، ایران  
<sup>۲</sup> گروه های<sup>۲</sup> پاتوبیولوژی و<sup>۳</sup> علوم درمانگاهی، دانشکده دامپزشکی، دانشگاه تهران، تهران، ایران

پذیرش نهایی: ۱۹/۷/۱۹

دریافت مقاله: ۱۹/۵/۱۸

### چکیده

هدف از انجام این مطالعه ارزیابی تغییرات هیستوپاتولوژیک رحم گاوهای شیری، با و یا بدون داشتن سابقه اختلالات تولید مثلی بود. گاوهای شیری نژاد هلشتاین (۱۳۳ رأس) با (۹۲ رأس، ۶۹/۱۷٪) یا بدون (۴۱ رأس، ۸۲/۳۰٪) علائم بالینی ثبت شده به منظور بررسی ضایعات هیستوپاتولوژیک رحمی مورد معاینه قرار گرفتند. گاوهای گروه درمان پس از زایمان ۳ بار تلقیح مصنوعی شده و یا بدون بروز علائم فحلی بودند. دوره پس از زایمان آنها بین ۹۰ الی ۱۴۵ روز بود. گاوهای گروه شاهد تلقیح نشده بودند. بیوپسی از آندومترיום و بافت های زیر مخاطی با استفاده از پنس بیوپسی با دهانه سوسماری (گرد) صورت گرفت. دامهای تلقیح شده در مراحل مختلف چرخه استروس بودند. نتایج نشان داد که به ترتیب ۶۴/۱۲٪ و ۴۶/۳۴٪ از گاوها با و یا بدون سابقه اختلالات تولید مثلی دارای ضایعات هیستوپاتولوژیک بودند. اختلاف معنی داری در تغییرات هیستوپاتولوژیک بین گاوهای با و یا بدون سابقه تولید مثلی وجود نداشت ( $P > 0.05$ ). آندومتریس مزمن بیشترین ضایعه میکروسکوپی در گاوهای دارای بیماریهای تولید مثلی (۳۴/۶۱٪) و یا بدون آن (۱۷/۹۴) بود. آندومتریس بالینی بیشترین اختلال ثبت شده بود (۲۰/۶۵٪). میزان ضایعات هیستوپاتولوژیک در گاوهایی با فحلی مکرر ۱۶/۳٪ بود. نتایج حاصله نشان می دهد که بیوپسی از آندومترיום می تواند در ارزیابی وضعیت تولید مثلی گاوهای شیری برای ارزیابی باروری بعدی مفید باشد و گاوها با و یا بدون اختلالات تولید مثلی ممکن است ضایعات هیستوپاتولوژیک رحمی داشته باشند.

واژگان کلیدی: گاو شیری، آندومتریس، هیستوپاتولوژی، اختلالات تولید مثل، رحم

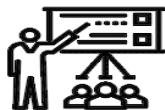# SID



ابزارهای  
پژوهش



سرویس ترجمه  
تخصصی



کارگاه های  
آموزشی



بلاگ  
مرکز اطلاعات علمی



سامانه ویراستاری  
STES



فیلم های  
آموزشی

## کارگاه های آموزشی مرکز اطلاعات علمی



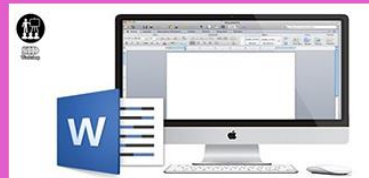کارگاه آموزشی  
آموزش مهارت های کاربردی در تدوین و چاپ مقالات ISI

آموزش مهارت های کاربردی  
در تدوین و چاپ مقالات ISI



کارگاه آموزشی  
روش تحقیق کمی

روش تحقیق کمی



کارگاه آموزشی  
آموزش نرم افزار Word برای پژوهشگران

آموزش نرم افزار Word  
برای پژوهشگران