

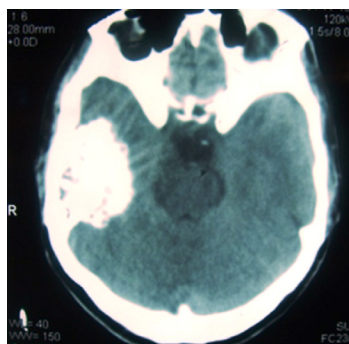
Photoclinic

Figure 1. Brain CT scan showed a round and relatively hyperdense lesion.

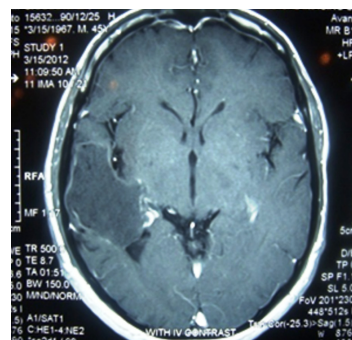


Figure 3. Post-contrast enhancement of cyst wall was observed in the T1 weighted image.

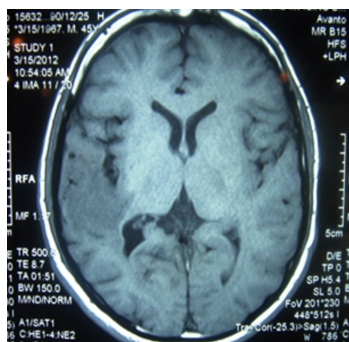


Figure 2. MRI findings in T1 weighted view revealed a mass with low intensity.

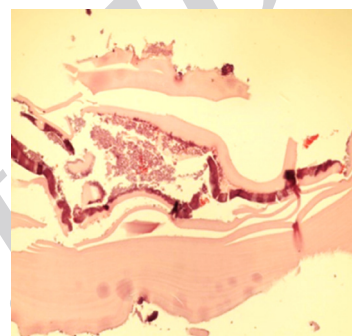


Figure 4. Histologic examination showed degenerated calcified material and the laminated layer.

A 45-year-old shepherd from the south-eastern province of Iran was hospitalized due to two generalized tonic-clonic seizure attacks during the previous 2 years. He gave a history of close contact with sheep and stray dogs. He took phenytoin after the first seizure. Clinical examination was normal and revealed no neurological deficit. Laboratory tests including blood sugar, electrolytes, liver function tests and renal function tests were normal. Electroencephalography (EEG) demonstrated generalized slowing of brain activity and diffuse epileptiform waves. Brain computerized tomography (CT) scan showed a calcified, rather round mass at the parietal and temporal lobes. Magnetic resonance imaging (MRI) revealed a large lesion (53 × 44 × 38 mm) at temporoparietal lobes. The lesion was low signal on T1 weighted images and showed only mild peripheral enhancement on post-contrast images (Figures 1–3).

According to clinical presentation and radiologic findings, several differential diagnoses were suggested including slow growing brain tumors like oligodendroglioma, tuberculoma, old infectious cysts and calcified hematoma. Therefore, the patient underwent surgical resection of the lesion through craniotomy and microscopic surgery of the lesion.

Grossly, the specimen appeared to be a calcified shell partially lined by a grayish creamy cystic wall with a gelatinous consistency. It contained semisolid necrotic material. Microscopic examination of the specimen revealed a cyst wall composed of an outer acellular laminated layer and inner degenerated germinal layer. The cyst ingredients were calcified necrotic material mimicking psammoma bodies. The cyst wall was surrounded by palisading histiocytes which focally formed foreign body type giant cells. No protozoa or hooklets were observed (Figure 4).

**What is your diagnosis?
See the next page for your diagnosis.**

Received: August 18, 2018, Accepted: December 24, 2018, ePublished: February 1, 2019

Moeinadin Safavi, MD^{1,2*}; Shariar Dabiri, MD²

¹Pathology Department, School of Medicine, Tehran University of Medical Sciences, Tehran, Iran. ²Pathology and Stem Research Center, Pathology Department, Afzalipour Medical School, Kerman University of Medical Sciences, Kerman, Iran.

*Corresponding Author: Moeinadin Safavi, MD. Pathology Department, School of Medicine, Tehran University of Medical Sciences, Tehran, Iran. Email: safavi_moeinadin@yahoo.com, moein.safavi@gmail.com, msafavi@sina.tuma.ac.ir

Cite this article as: Safavi M, Shariar Dabiri S. Photoclinic. Arch Iran Med. 2019;22(2):102-103.

■ Photoclinic Diagnosis

Calcified Cerebral Hydatid Cyst Presenting with Seizure

Hydatid disease is a human parasitic infection caused by larval stages of tapeworms of the genus *Echinococcus*. The 2 main types of hydatid disease are unilocular and alveolar echinococcosis which are caused by *Echinococcus granulosus* and *Echinococcus multilocularis*, respectively. It is endemic in the Middle East, Mediterranean countries, South America, North Africa and Australia with a prevalence of 1-150/100000. Hydatid cysts may occur in the liver in 75% of patients, lung in 15% of patients and other organs in 10% of patients. Brain involvement happens in 1%–4% of cases while only 1–5% of cerebral hydatid cysts undergo calcification. Less than 20% of intracranial hydatidosis happens in the context of other organ involvement.^{1,2} Cerebral hydatid cyst is rare and happens in around in 1%–2% of cases. Contrary to the present case, it is more common in childhood. Cerebral hydatid cyst is usually solitary and located in the middle cerebral artery territory especially in the parietal lobe.³

Calcification of an intracerebral hydatid cyst is extremely rare and constitutes only 1%–4% of cerebral hydatid cysts. Calcification usually happens in the outer fibrous layer. Although calcification in the pericyst does not confirm death of the parasite, but it indicates inactivation of disease, especially in the liver. However complete calcification of the cyst reveals parasite death. Exact association of calcification and inactivity of the brain hydatid cyst is not determined due to small number of the cases.⁴ However, in the present case, the calcified cyst was completely inactive and did not contain a viable germinal layer and lacked protoscolices.

Non-contrast CT scan findings in calcified cerebral hydatid cysts include an isodense to hyperdense cyst wall encircling an isodense fluid with cerebrospinal fluid (CSF). It shows no enhancement with contrast. However, this case was densely calcified and the central fluid was not seen. MRI characteristics of brain hydatid cysts are similar. T1 and T2 weighted images show low signal intensity rim with isointense contents with CSF. Pathognomonic features on

CT and MRI are membrane detachment and daughter cysts. Cyst wall and intracystic membrane calcification are also indicative for a hydatid cyst.³

Surgery is the treatment of choice in hydatid cyst cases. Surgery of the calcified liver cysts is not recommended and a wait and observe policy is indicated. This rule is not true for calcified brain lesions, as almost all of them, including our case, present with seizure.⁵

In conclusion, although a calcified cerebral cyst is a very rare entity, we must always take it into consideration in the differential diagnosis of brain calcified lesions, especially in endemic areas.

Authors' Contribution

Images and Data: MS; Manuscript perpetration: MS, SD.

Conflict of Interest Disclosures

The authors have no conflicts of interest.

Ethical Statement

An informed consent was obtained from the patient for photographs, documentation and publication of this photoclinic.

References

1. Dakkak A. Echinococcus/hydatidosis: a severe threat in Mediterranean countries. *Vet Parasitol*. 2010;174(1-2):2-11. doi: 10.1016/j.vetpar.2010.08.009.
2. Daskas N, Aggelopoulos E, Tzoufi M, Kosta P, Siamopoulou A, Argyropoulou MI. Accidental drainage of a cerebral hydatid cyst into the peritoneal cavity. *Pediatr Infect Dis J*. 2004;23(7):685-6.
3. Bukte Y, Kemaloglu S, Nazaroğlu H, Ozkan U, Ceviz A, Simsek M. Cerebral hydatid disease: CT and MR imaging findings. *Swiss Med Wkly*. 2004;134(31-32):459-67. doi: 2004/31/smw-10711
4. WHO Informal Working Group. International classification of ultrasound images in cystic echinococcosis for application in clinical and field epidemiological settings. *Acta Trop* 2003; 85(2): 253-61
5. Choukri M, Bertal A, Lakhdar A, Achouri M, Ouboukhlik A, el Kamar A, et al. Calcified cerebral hydatid cyst. Report of a case. *J Neuroradiol*. 2001; 28(4): 261-263.



© 2019 The Author(s). This is an open-access article distributed under the terms of the Creative Commons Attribution License (<http://creativecommons.org/licenses/by/4.0>), which permits unrestricted use, distribution, and reproduction in any medium, provided the original work is properly cited.

Surf and download all data from SID.ir: www.SID.ir

Translate via STRS.ir: www.STRS.ir

Follow our scientific posts via our Blog: www.sid.ir/blog

Use our educational service (Courses, Workshops, Videos and etc.) via Workshop: www.sid.ir/workshop