

Case Report

Massive Hemoptysis, A Presentation of Invasion of Aneurysm of Descending Aorta to Bronchopulmonary tree

Zargham Hossein Ahmadi MD¹, Zahra Ansari Aval MD², Seyed Reza Saghebi MD², Amir Abbas Kianfar MD³, Seyed Mohammad-Reza Hashemian MD⁴, Shahram Kahkouee MD², Sepehr Roozdar MD⁵, Hadi Naderi MD⁶

Abstract

Aortobronchial (AB) fistula is a rare disease, which is presented with massive hemoptysis; lethal if not treated. It should be suspected in any patient who presents with massive hemoptysis and had previous aortic thoracic surgery, but even it may be seen in patients without any history of operation on the thoracic aorta.

Although, today in many centers endovascular therapy is done for these patients, but it is not the standard approach. Surgery in urgent situations has an essential role in saving the patients. Operative management consists of double lumen intubation and one lung ventilation, followed by femoral artery and vein cannulation. Then Posterolateral thoracotomy and achieving proximal and distal control on the aorta, applying cardiopulmonary bypass (CPB), separation the lesion, and bypass the segment of the diseased aorta by a synthetic graft.

Keywords: Aneurysm of thoracic aorta, aortobronchial fistula, cardiopulmonary bypass, endovascular therapy, massive hemoptysis

Cite this article as: Ahmadi ZH, Ansari Aval Z, Saghebi SR, Kianfar AA, Hashemian SMR, Kahkouee S, et al. Massive hemoptysis, a presentation of invasion of aneurysm of descending aorta to bronchopulmonary tree. *Arch Iran Med.* 2014; **17(11)**: 786 – 788.

Introduction

Due to invasion of the aorta, aortobronchial (AB) fistula is a rare, but serious entity, which presents with massive hemoptysis and is nearly always fatal if not treated surgically.¹ High degree of suspicious to this entity is the key for appropriate management. Nowadays treatment is performed by new endovascular techniques via implantation of stents,² However it is not a standard approach, and in centers with the lack of the above facilities and unstable patient surgery should be kept in mind.

This is the report of two cases who had an aneurysm of the aorta with invasion to the pulmonary tree caused aortobronchial (AB) fistula, presented with massive hemoptysis and workups were suggestive for AB fistula by CT angiography. Patients were undergone an urgent surgery. Postoperative course of both patients were uneventful and they were discharged from the hospital.

Authors' affiliations: ¹Lung Transplantation Research Center, National Research of Tuberculosis and Lung Diseases (NRITLD), Shahid Beheshti University of Medical Sciences, Tehran, Iran, ²Chronic Respiratory Diseases Research Center, National Research Institute of Tuberculosis and Lung Diseases (NRITLD), Shahid Beheshti University of Medical Sciences, Tehran, Iran, ³Tracheal Diseases Research Center, National Research Institute of Tuberculosis and Lung Diseases (NRITLD), Shahid Beheshti University of Medical Sciences, Tehran, Iran, ⁴Clinical Tuberculosis and Epidemiology Research Center, National Research Institute of Tuberculosis and Lung Diseases (NRITLD), Shahid Beheshti University of Medical Sciences, Tehran, Iran, ⁵Tobacco Prevention and Control Research Center, National Research Institute of Tuberculosis and Lung Diseases (NRITLD), Shahid Beheshti University of Medical Sciences, Tehran, Iran, ⁶Telemedicine Research Center, National Research Institute of Tuberculosis and Lung Diseases (NRITLD), Shahid Beheshti University of Medical Sciences, Tehran, Iran

Corresponding author and reprints: Zargham Hossein Ahmadi MD, Lung Transplantation Research Center, National Research of Tuberculosis and Lung Diseases (NRITLD), Shahid Beheshti University of Medical Sciences, Tehran, Iran. Address: Masih Daneshvari Medical Center, National Research Institute of Tuberculosis and lung disease (NRITLD), Darabad, Niavaran, Tehran 1956944413, Iran. Tel: +98-21-27122590-1, Fax: +98-21-22037591, E-mail: zarghamahmadi@hotmail.com, ahmadiz@sbmu.ac.ir
Accepted for publication: 20 August 2014

Case Report

Case 1

An 82-year-old male was presented to the ER of this center due to a sudden expectoration of about 300cc fresh blood, accompanied with decreased level of consciousness of hypotension and shock state. After resuscitation and stabilization of the patient, an emergency CT scan performed which showed an aneurysm of the distal of descending thoracic aorta with adhesion to the lower lobe of left lung. Due to fresh blood expectorations, which were repeated for a second time, surgical resection of the aneurysm was decided.

In operation, in semi-left lateral position, first heparin 3mg/kg/min was given, and then cannulation of the left femoral artery and vein was performed by the Seldinger technique. Then the patient was turned to semi lateral position and the left chest was opened by posterolateral thoracotomy via left 6th intercostals space. There was a 5 cm aneurysm. Proximal and distal control was applied. Gradual releasing of the aneurysm was done, which suddenly the aneurysm was ruptured. Immediately CPB was established. The proximal and distal controlled was achieved. The aneurysm was separated of the lung completely, resected and bypassed by a 22 mm collagen coated knitted polyester vascular graft (INTERGARD®). The bronchial opening of the lung was ligated with silk sutures. No lung resection was performed. The samples sent for pathology and culture. The result of pathology was atheroma and the culture was negative for aerobic and anaerobic microorganisms. The postoperative course was uneventful and the patient was discharged in the 8th post operation day.

Case 2

A 42-year-old female was admitted in our center due to expectoration of 250cc blood and decreased level of consciousness. Due to hypoxia, intubation and mechanical ventilation were started for her. CT scan showed an aneurysm in the proximal of the descending aorta with extravasation of its content to the lung parenchyma

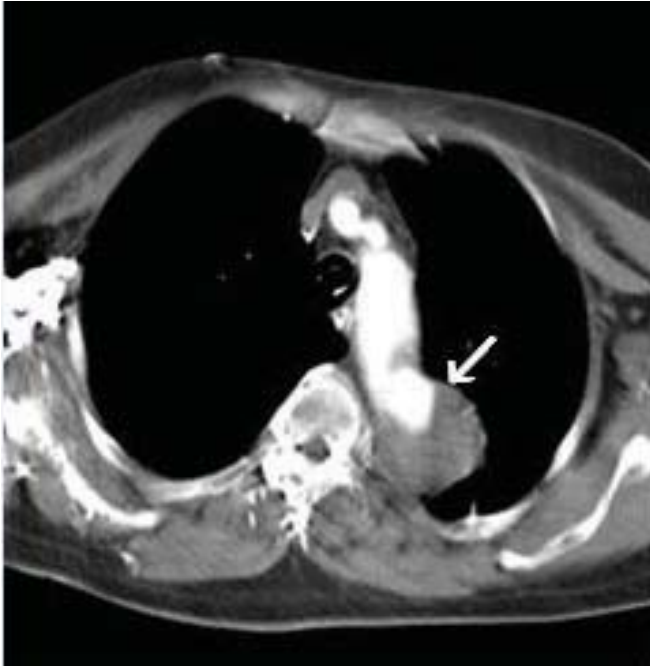


Figure 1. Leakage of intra aortic contrast in the proximal of descending aorta, formed a soft tissue mass

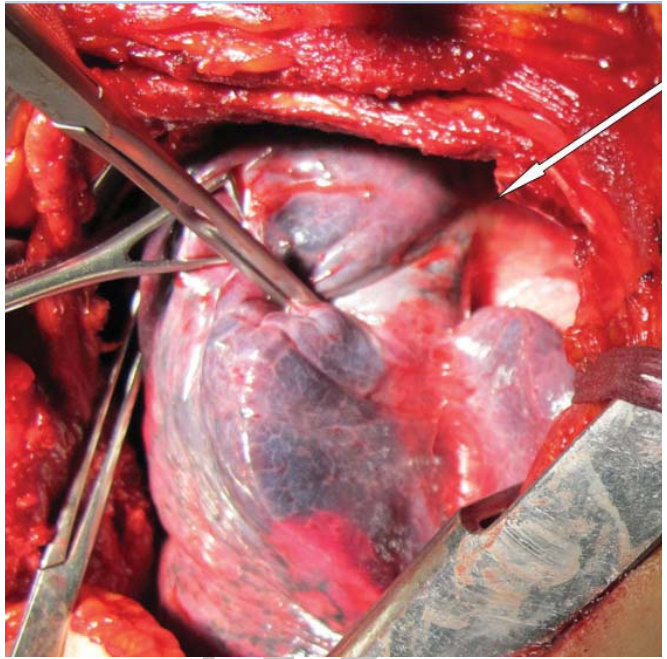


Figure 2. Lung tissue is adhered to the aneurysmal segment of the aorta with no evidence of any gross leakage of blood

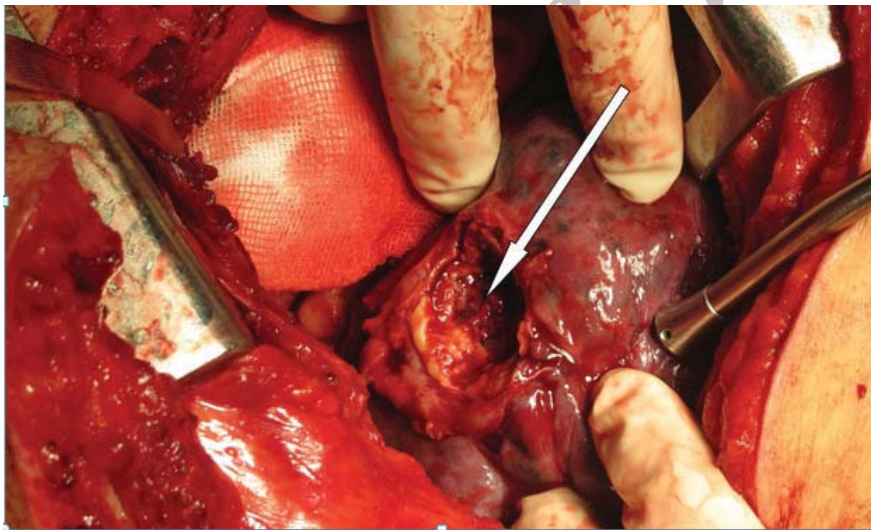


Figure 3. Fish-mouth appearance of the lung tissue after separation of the aneurysm. Open bronchial trees was seen obviously

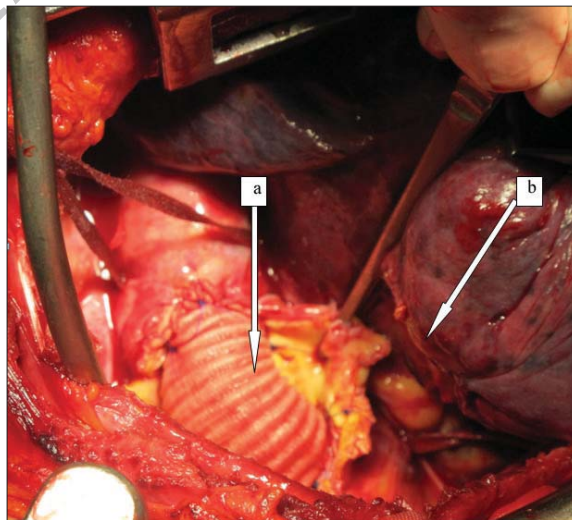


Figure 4. The end of the surgical procedure; **a)** the segment of the interposed aorta, **b)** lung tissue after segmentectomy

(Figure 1). The patient was undergone an emergency operation. Cannulation was done as the previous case, but the chest was opened by a posterolateral thoracotomy via left fourth intercostals space. There was an aneurysm of aorta with the diameter of 6 cm, which was attached to the lung just after the arch and the lung was engorged at that region (Figure 2). CPB was established. After distal and proximal control of the aorta, it was separated from the lung. It seemed that the lung being invaded and digested by the aneurysm, and lungs likely have an opening mouth (Figure 3). That part of the aorta was interposed by #24mm. collagen coated knitted polyester vascular graft (INTERGARD®) (arrow a in Figure 4) as well as wedge resection of the lung was done by Stapler (arrow b in Figure 4). Samples were sent for culture and pathology. The result of culture was negative and atheromatous plaques were found in the aortic sample. Post op. course was uneventful. The patient was weaned of ventilator in the 3rd post op. day and was discharged in the 12th postoperative day. One year follow-up was done. The patient had normal activity and was asymptomatic.

Discussion

It is estimated that 5% of patients who present with hemoptysis, has massive hemoptysis,³ a life-threatening condition that may cause airway obstruction and exsanguinations. Its mortality is 30% – 70%.³

AB fistula as a rare cause of massive hemoptysis, should always be suspected in every patient who had a history of previous surgery in the thoracic aorta presented with massive hemoptysis.⁴ However, AB fistula may also be seen without any history of any disease, as our patients. It may also be associated with typical symptoms such as back pain; chest pain, cough, and shortness of breath.⁵ In both patients immediately after stabilization and adequate resuscitation, CT angiography were done (Figure 1). It showed proximal part of descending aorta is in continuity with a soft tissue mass in the left lung and leakage of intra aortic contrast to this mass is notable.

Otherwise, scattered nodular infiltrations in the lungs field due to aspirated blood to bronchioles are visible.

This finding was suggestive of AB fistula, and indicative of possible extravasation of blood from the aorta to the pulmonary tissues. However, demonstration of fistula by CT is rare.⁶

MRI is a useful diagnostic tool for this entity.⁶ The main limitation of this tool was that it was not available in our center. It is also a time consuming procedure and is not logic to be applied in the setting of an emergent and potentially unstable patient.

Surgery consists of a major, complicated operation, including cannulation of the femoral artery and vein, thoracotomy, applying CPB, and correction of pathology.

Although, endovascular techniques has become a safe minimally invasive procedure in management of these cases, but it should be considered that still the standard procedure for these cases is surgery, especially when the patient is unstable and needs urgent treatment. Meanwhile aortobronchial and aortoesophageal fistulas are potentially infected and applying endovascular stents in a clean contaminated area may not be logical.

In many centers in our country and also in developing countries, the setup for endovascular device is not available everywhere, therefore surgery should always be kept in mind.

In the operation room, just after induction of anesthesia rigid and fiberoptic bronchoscopy were done. All the airways were cleansed of blood as possible. This procedure was performed cautiously to prevent the removal of the clots, because removing of the clots may cause mobilization, dislodgment or lysis of thrombi and sub-

sequent massive bleeding. In both cases bronchoscopy could only show the side of bleeding, but could not locate the point of bleeding. Double lumen intubation and single lung ventilation were performed for both patients.

The best exposure was achieved by thoracotomy rather than midsternotomy; although in the former (thoracotomy) cannulation of great vessels was challenging problem. In both patients cannulation of the femoral artery and femoral vein were done by Seldinger technique at semi-right lateral position. In both patients posterolateral thoracotomy were done, because of good exposure of thoracic aorta. After observing the pathology, CPB was established, distal and proximal control of the aorta was applied. Then proximal and distal aorta were clamped and the aorta was opened. There was a gross communication of the aorta and lung tissue. A segment of lung tissue as well as aorta were removed. The aorta was substituted by a Dacron graft and the lung was repaired. The operation was done under normothermia, although deep hypothermia and total circulatory arrest were done in some studies.⁷ Thoracotomy was done in these cases; in both cases only a small segment of the aorta was clamped that there was no worry about disturbing the vascular supply of the spinal cord, so hypothermia was not induced. We believed that with femoral cannulation and thoracotomy, the operation could be done simply. Meanwhile achieving exposure of descending thoracic aorta in thoracotomy is much easier than midsternotomy.

Pathologic finding showed only atheroma with no evidence of any vasculitis or infectious diseases such as Tuberculosis, which is endemic in our region.⁸ These findings may suggest that obliteration of pulmonary vasculature by expanding aneurysm and pressure necrosis of causes rupture of lung parenchyma and/or erosion of bronchus, and subsequent hemoptysis.⁴

AB fistula is a rare but lethal condition if remains untreated. Presentation is usually by an episode of massive hemoptysis. Definite diagnosis is by MRI, but CT angiography is helpful for suspicion and beginning the management.

The choice of treatment is implantation endovascular stent grafts, but in areas in which above facility is not available, surgery should be done promptly. CPB is mandatory for surgical treatment.

References

1. Falode T, Alphonso N, Austin C, Anderson D. Aortobronchial fistula: the hidden connection. *Asian Cardiovasc Thorac Ann.* 2006; **14**: e74 – e75.
2. Kokotsakis J, Mithos P, Athanasiou T, Romana C, Skouteli E, Lioulis A, et al. Endovascular stenting for primary aortobronchial fistula in association with massive hemoptysis. *Tex Heart Inst J.* 2007; **34**: 369 – 372.
3. Phang LY, Wong D, Agasthian T. Management of life threatening hemoptysis. *Asian Cardiovasc Thorac Ann.* 2001; **9**: 200 – 203.
4. Amirghofran AA, Mollazadeh R, Kojuri J. Hemoptysis Due to Aortic Aneurysm at the Site of Coarctation Repair. *Asian Cardiovascular and Thoracic Annals.* 2008; **16**: 88.
5. Yoo JH, Lee CT, Shim YS, Chung JW, Ahn H, Kim KW. Aortobronchial fistula presenting as recurrent hemoptysis and successfully treated with an endovascular stent graft. *Respiration.* 2001; **65**: 20 – 22.
6. Algaba Calderón A, Jara Chinarro B, Abad Fernández A, Isidoro Navarrete O, Ramos Martos A, Juretschke Moragues MA. Recurrent hemoptysis secondary to an aortobronchial fistula. *Arch Bronconeumol.* 2005; **41**(6): 352 – 354
7. Bhuyan RR, Rajendran S, Unnikrishnan M, Jayakumar K. Successful repair of aortobronchial fistula using circulatory arrest. *ANZ J Surg.* 2007; **77**: 398 – 399
8. Suresh K, Kurian VM, Sankar NM, Patel A, Joseph P, Cherian KM. Repair of Tuberculous Aneurysm of Distal Aortic Arch. *Asian Cardiovasc Thorac Ann.* 2003; **11**: 346 – 348.