

## Case Report

## Cryptogenic Myocardial Infarction in Young Patients: Which is the Optimal Diagnostic and Therapeutic Management?

Cristina Giglioli MD<sup>1</sup>, Serena Fatucchi MD<sup>1</sup>, Miroslava Stolcova MD<sup>1</sup>, Roberto Mercuri MD<sup>2</sup>, Rosanna Abbate MD<sup>1</sup>, Giorgio Galanti MD<sup>2</sup>, Emanuele Cecchi MD<sup>1</sup>

### Abstract

A 31-year-old athlete was admitted to our hospital for previous inferior myocardial infarction (MI), diagnosed by transthoracic echocardiography, myocardial scintigraphy, and cardiac magnetic resonance, while coronary angiography revealed normal coronary arteries. Laboratory investigations excluded acquired or inherited thrombophilia, immunologic disorders, cardiotropic agents infection, and drug abuse. Antiplatelet therapy was started but, after 15 days, he was rehospitalized with diagnosis of multiple left renal infarctions. A transesophageal echocardiography (TEE) was so performed which excluded a right-to-left shunt, suggestive of patent foramen ovale, or other cardioembolic sources in heart chambers and valve apparatus. Antiplatelet therapy was replaced with oral anticoagulants without any further embolic event at one-year follow-up. This case raises two important questions regarding young patients with cryptogenic MI. First, if TEE should be part of a complete diagnostic pathway; second, if oral anticoagulants should be preferred over antiplatelets for secondary prevention particularly when the cause of MI remains unknown.

**Keywords:** Cryptogenic myocardial infarction, oral anticoagulant therapy, transesophageal echocardiography

**Cite this article as:** Giglioli C, Fatucchi S, Stolcova M, Mercuri R, Abbate R, Galanti G, et al. Cryptogenic myocardial infarction in young patients: Which is the optimal diagnostic and therapeutic management? *Arch Iran Med.* 2013; **16(5)**: 308 – 311.

### Introduction

Myocardial infarction (MI) with normal coronary arteries (NCA) is a well-recognized clinical entity and the overall prevalence ranges from 1% to 12%.<sup>1,2</sup> Data from the literature suggest that patients with MI and NCA are usually under 50 years of age, men and women are equally affected, there is no history of chest pain or cardiovascular risk factors, with the exception of cigarette smoking.<sup>3-6</sup> Although symptoms and electrocardiographic findings are quite similar to those found in patients with coronary obstruction, the infarct area is usually smaller and the prognosis is better,<sup>6</sup> even if it remains strictly dependent on etiopathogenesis, with a high risk of reinfarction or other ischemic events in patients with congenital coagulation disorder.<sup>7</sup> Several mechanisms have been proposed for MI with NCA: coronary vasospasm, artery dissection, acquired or inherited thrombophilia, myocardial bridges, toxic conditions like recreational or performance-enhancement drugs abuse, and embolization from a distal source, including paradoxical embolism through a venous-arterial shunt.<sup>4,6,8,9</sup> However, at present MI with NCA still represents a challenge in medical practice since scarce data are available on a possible diagnostic and therapeutic algorithm, particularly concerning secondary prevention therapy, since in about two thirds of patients the cause of MI remains unknown.<sup>4,8</sup>

**Authors' affiliations:** <sup>1</sup>Department of Heart and Vessels, Azienda Ospedaliero-Universitaria Careggi, Florence, Italy, <sup>2</sup>Sports Medicine Center, University of Florence, Florence, Italy.

**Corresponding author and reprints:** Emanuele Cecchi MD, Dipartimento del Cuore e dei Vasi, Azienda Ospedaliero-Universitaria Careggi, Viale Morgagni 85, 50134, Florence, Italy. Tel: +390557949577, Fax: +390557947617, E-mail: emanuelececchi@virgilio.it.

Accepted for publication: 28 December 2012

### Case Report

We report the case of a 31-year-old man, elite water polo player, in whom an electrocardiogram (ECG) registered on the occasion of a routine sport-eligibility certificate (required by law in Italy for professional athletes, yearly) revealed pathologic Q waves and negative T waves in inferior and lateral leads and a right intraventricular conduction delay, this latter already present in a previous ECG. A subsequent transthoracic echocardiography showed an area of hypo-akinesia at the interventricular septum and inferior wall and a mild reduction in systolic function (estimated ejection fraction of 49%); myocardial scintigraphy confirmed the presence of a perfusion defect and hypo-akinesia of the inferior wall. The patient was so hospitalized in the cardiac step down unit of our department. At admission, he was asymptomatic and physical examination did not reveal any abnormality: the heart rate was 40 beats/min and the other vital parameters were within normal limits. He had no cardiovascular risk factors, except for hypercholesterolemia (total cholesterol 254 mg/dL) and denied any assumption of recreational or performance-enhancement drugs. Laboratory tests, including biomarkers of myocardial damage, were all within normal limits. Serologic assays for the detection of the main cardiotropic agents and specific studies for the presence of congenital or acquired thrombophilia were negative. Immunologic disorders were also excluded with specific tests. Urine test was negative for recent amphetamine, cocaine, benzodiazepine, and cannabinoids abuse.

The ventricle-coronary angiography revealed NCA and akinesia of the diaphragmatic wall; cardiac magnetic resonance with contrast medium was also performed, confirming the ischemic nature of myocardial damage and excluding myocarditis.

The patient was then discharged and a drug regimen of aspirin,

statin, angiotensin receptor blocker, and proton pump inhibitor was started, according to the guidelines for the management of MI.<sup>10,11</sup> Fifteen days after discharge, he was readmitted to another hospital for abdominal pain in the left iliac pit. Laboratory investigations revealed increased lactic dehydrogenase levels (1851 U/L at the peak). An abdominal computed tomography (CT) with contrast medium showed absence of opacification of the superior, inferior, and external equatorial region of the left kidney, leading to the diagnosis of multiple small renal infarctions which was confirmed by an echo-color doppler of renal arteries and renal sequential scintigraphy, both suggestive of an embolic origin of the lesions detected. After this further ischemic event a transesophageal echocardiography (TEE) was carried out and did not reveal any cardioembolic source both in heart chambers and valve apparatus or a right-to-left shunt, even during Valsalva maneuver, so excluding also the presence of PFO (Figure 1). The patient was then discharged and anticoagulant therapy was started first with low molecular weight heparin and then with warfarin.

### **Myocardial Infarction with Normal Coronary Arteries**

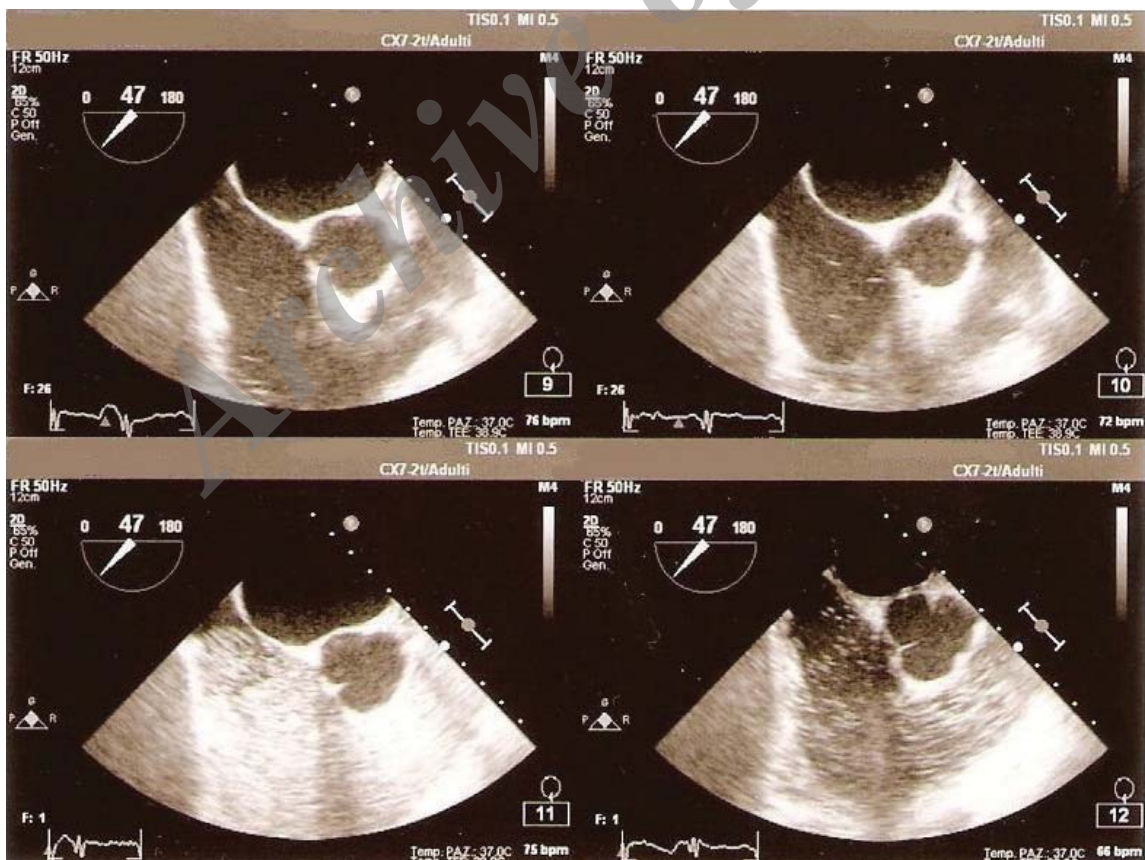
#### **Epidemiology**

MI with NCA is a well-recognized clinical entity that occurs in a small percentage of the general population. Its prevalence is estimated between 1% and 12%,<sup>1,2</sup> although actually it is highly dependent on the definition used for NCA, including both cases where the coronary tree appears completely free of irregularities, and cases with some degree of stenosis, even if not hemodynamically significant (< 30%). For this reason the analysis of data from

the literature allow to consider a prevalence of 3% in the general population.<sup>3,8,12</sup> MI unlike sudden cardiac death is rare particularly in young adults and athletes: under 35 years of age a great part of sudden cardiac death is caused by cardiac congenital abnormalities, above 35 years of age MI and myocardial ischemia are responsible for the most cases of sudden cardiac death.<sup>13</sup> In a Swiss registry an analysis of 1101 cases of sudden death in athletes younger than 35 years showed that 90% were due to cardiovascular disease, 50% presented congenital heart disease and cardiomyopathies, and only 10% of patients had an early coronary artery disease (CAD).<sup>14</sup> MI with NCA is typically diagnosed in young people under 50 years of age, with a higher prevalence in younger patients, men and women are equally affected, usually there is no history of chest pain or other traditional cardiovascular risk factors, with the exception of cigarette smoking.<sup>3-6,15</sup> Although symptoms and electrocardiographic findings are quite similar to those found in patients with obstructive CAD, the infarct area is usually smaller and the prognosis is better.<sup>6</sup>

#### **Etiopathogenesis**

It is not possible to identify a single cause for MI with NCA; therefore, over the years several pathogenic mechanisms have been proposed: coronary vasospasm supported by an endothelial dysfunction, possibly associated with systemic vasospastic disorders (Raynaud's phenomenon or vasospastic migraine); acquired or inherited coagulation disorders that can result in thrombophilia, favoring coronary artery thrombosis; spontaneous coronary dissection or aortic dissection extended to coronary arteries; myo-



**Figure 1.** Transesophageal echocardiography with ultrasound contrast medium. This examination allowed to exclude cardioembolic sources both in heart chambers and valve apparatus or a right-to-left atrial shunt, even during Valsalva maneuver.

cardial bridges; toxic conditions like recreational or performance-enhancement drugs abuse; and embolization from a distal source, including paradoxical embolism of thrombus or vasoactive substances that can induce coronary vasospasm, through a venous-arterial shunt, related to the presence of a patent foramen ovale (PFO) or a pulmonary artero-venous malformation. For their clinical presentation, similar to an acute MI, also myocarditis and Tako-tsubo cardiomyopathy should be considered in the differential diagnosis.<sup>4,6,8,9</sup> Among other possible causes that can be hypothesized to determine MI with NCA, acute alcohol intoxication has also been reported.<sup>16,17</sup>

#### Diagnostic pathway

In young patients presenting with MI obstructive CAD or coronary vasospasm must be properly excluded by performing a ventricle-coronary angiography, possibly associated with a provocative test with selective intracoronary injection of acetylcholine or ergonovine,<sup>18</sup> that has not been performed in the present case, given the high risk of complications such as acute MI, bradi- or tachyarrhythmias, and hypotension associated with this test.<sup>19</sup> A further diagnostic approach can be represented by the hyperventilation test, that has been proved capable of causing coronary vasospasm that can result in angina, ST elevation or depression, and life-threatening arrhythmias.<sup>20</sup> Acquired or inherited coagulation disorders must be properly investigated, particularly lupus anticoagulant and anticardiolipin antibodies, protein C and S deficiencies, activated protein C resistance (caused by factor V mutation or high levels of factor VIII), von Willebrand factor, serum homocysteine, plasminogen activator inhibitor-1, lipoprotein (a) levels, antithrombin III levels, prothrombin G20210A, and factor IX Padua mutations.<sup>21</sup>

Also immunologic disorders with particular regard to those causing vasculitides must be properly excluded as causes of MI with NCA.<sup>4,6,8,9</sup> Assumption of recreational or performance-enhancement drugs can be assessed with urine and blood tests as well as hair analysis, that can be useful to obtain as retrospective information.<sup>22</sup> Among the possible causes of cryptogenic MI include embolization from a distal source, such as paradoxical embolism of thrombus or vasoactive mediators, that can induce coronary vasospasm through a venous-arterial shunt. However, studies performed in pediatric and young patients have not definitively demonstrated a higher prevalence of PFO in patients with MI and NCA, at variance with cryptogenic stroke for which the association with paradoxical embolism through a PFO is well documented.<sup>23-25</sup> Therefore, also in patients with MI and NCA, TEE should be helpful for excluding the presence of intracardiac shunts or other possible embolic sources both in heart chambers and valve apparatus in order to reduce the risk of embolic recurrences. To date, TEE is the most sensitive diagnostic method for diagnosing PFO, along with transcranial doppler, equally sensitive and less invasive, but unable to detect minor defects.<sup>26</sup> An additional method for the risk and prognosis assessment of young patients with no high-risk profile for CAD, may be represented by the multislice computed tomography (CT), that can provide high resolution coronary angiograms with a noninvasive technique.<sup>27</sup>

#### Therapeutic management

Even after a careful analysis of any related condition, in about two thirds of patients with cryptogenic MI a specific cause is not found, as in the present case, although the prognosis, usually con-

sidered good, is highly dependent on etiopathogenesis.<sup>4,8</sup> When a specific cause is not found, a therapy similar to that of patients with CAD including aspirin, beta-blocker, statin, and ACE-inhibitor is started and cardiovascular risk factors control and smoking cessation are advised.<sup>3,4,28</sup> However, patients with cryptogenic MI and inherited or acquired thrombophilia, seem to have an increased risk of recurrent thrombotic events either venous or arterial,<sup>7</sup> despite antiplatelet therapy, usually administered according to guidelines (class I, LOE A),<sup>10,11</sup> so that anticoagulant therapy can be useful for secondary prevention,<sup>7</sup> (class IIa, LOE B)<sup>11</sup> in patients with cryptogenic MI and suspected or proven coagulation disorders, or documented potential embolic sources.

#### Long-term prognosis and recurrence of ischemic events

Few studies have been carried out regarding long-term prognosis of young patients with MI and NCA. However, from the first large studies emerged that these patients have a better prognosis compared to those with moderate CAD, with a lower rate of cardiovascular death and reinfarction.<sup>29</sup> In one of the first large follow-up studies, a survival rate of 85% at a 10-year follow-up has been reported in patients with MI and NCA versus 73% in patients with occlusive CAD.<sup>30</sup> On the other hand, a more recent study has shown a mortality of 1.8% at 30 days and 4.0 % at one year follow-up in patients with MI and NCA; these mortality rates were significantly lower than those observed in patients with high-risk CAD, but similar to those of patients with coronary stenosis < 50% or at low risk.<sup>10</sup> Although the prognosis is generally excellent for patients with MI and NCA, a small portion of them during follow-up presents adverse events. Recurrence of angina, heart failure, and reinfarction are the most frequent events and a depressed left ventricular ejection fraction has shown as an independent predictor of cardiac events and death in these patients.<sup>31,32</sup> Moreover, recurrence of ischemic events, including venous thrombosis or pulmonary embolism, reinfarction, and stroke appears three-fold higher in patients with proven inherited coagulation abnormalities than in patients without after the onset of a first MI with NCA.<sup>7</sup>

#### Discussion

In the present review, we report the main available evidences regarding patients with MI and NCA. However, the case here reported raises two important questions regarding the optimal diagnostic and therapeutic management of these patients: first if TEE should be routinely performed as part of the diagnostic pathway; second, if oral anticoagulation should be preferred over antiplatelet therapy for secondary prevention of patients in whom the cause of MI remains unknown. In fact, among the possible causes of cryptogenic MI, also the presence of PFO should be considered even if studies performed in pediatric and young patients have not definitively demonstrated a higher prevalence of PFO in patients with MI and NCA, at variance with cryptogenic stroke for which the association with paradoxical embolism through a PFO is well documented.<sup>23-25</sup> Therefore, we wonder if TEE should be routinely performed also in patients with cryptogenic MI to exclude the presence of intracardiac shunts or other possible embolic sources both in heart chambers and valve apparatus, even if no guidelines, at present, suggest that this examination should be part of the diagnostic pathway of these patients. To date, TEE is the most sensitive diagnostic method for diagnosing



PFO, along with transcranial doppler, equally sensitive and less invasive, unable however to detect minor defects.<sup>26</sup> Yet, even after a careful analysis of any related condition, in about two thirds of patients with cryptogenic MI a specific cause is not found, as in the present case, although the prognosis, usually considered good, is highly dependent on etiopathogenesis. When a specific cause is not found, a therapy similar to that of MI patients with obstructive CAD, including aspirin as antithrombotic regimen is started and cardiovascular risk factors control and smoking cessation are advised.<sup>3,4,28</sup> However, patients with cryptogenic MI and inherited or acquired thrombophilia seem to have an increased risk of recurrent thrombotic events either venous or arterial<sup>7</sup> despite antiplatelet therapy, usually administered according to guidelines.<sup>10,11</sup> Even in our patient antiplatelet therapy was initially started but failed in preventing further ischemic events and oral anticoagulant therapy was started with no further embolic events at one-year follow-up. This latter observation led us to wonder which could be the optimal antithrombotic therapy for these patients and if a subgroup of them should clearly benefit from anticoagulation. However, further studies are needed in a larger number of patients to evaluate whether oral anticoagulant therapy over aspirin should be recommended for secondary prevention of patients with cryptogenic MI.

## References

- Ammann P, Marschall S, Kraus M, Schmid L, Angehrn W, Krampf R, et al. Characteristics and prognosis of myocardial infarction in patients with normal coronary arteries. *Chest*. 2000; **117**: 333 – 338.
- Alpert JS. Myocardial infarction with angiographically normal coronary arteries. *Arch Intern Med*. 1994; **154**: 265 – 269.
- Pinney SP, Rabbani LE. Myocardial infarction with normal coronary arteries: Proposed pathogenesis and predisposing risk factors. *J Thromb Thrombolysis*. 2001; **11**: 11 – 17.
- Chandrasekaran B, Kurbaan AS. Myocardial infarction with angiographically normal coronary arteries. *JR Soc Med*. 2002; **95**: 398 – 400.
- Ahmar W, Lefkowitz J. Acute ST elevation infarction with angiographically normal coronary arteries: causes and outcome. *Int J Cardiol*. 2008; **128**: 131 – 133.
- Kardasz I, De Caterina R. Myocardial infarction with normal coronary arteries: a conundrum with multiple aetiologies and variable prognosis: an update. *J Intern Med*. 2007; **261**: 330 – 348.
- Da Costa A, Tardy B, Haouchette K, Mismetti P, Cerisier A, Lamaud M, et al. Long-term prognosis of patients with myocardial infarction and normal coronary angiography: impact of inherited coagulation disorders. *Thromb Haemost*. 2004; **91**: 388 – 393.
- Da Costa A, Isaaq K, Faure E, Mouro S, Cerisier A, Lamaud M. Clinical characteristics, aetiological factors and long-term prognosis of myocardial infarction with an absolutely normal coronary angiogram. *Eur Heart J*. 2001; **22**: 1459 – 1465.
- Dao CN, Tobis JM. PFO and paradoxical embolism producing events other than stroke. *Catheter Cardiovasc Interv*. 2011; **77**: 903 – 909.
- Kushner FG, Hand M, Smith SC Jr, King SB 3rd, Anderson JL, Antman EM, et al. 2009 Focused Updates: ACC/AHA Guidelines for the Management of Patients with ST-Elevation Myocardial Infarction (Updating the 2004 Guideline and 2007 Focused Update) and ACC/AHA/SCAI Guidelines on Percutaneous Coronary Intervention (Updating the 2005 Guideline and 2007 Focused Update): A Report of the American College of Cardiology Foundation/American Heart Association Task Force on Practice Guidelines. *J Am Coll Cardiol*. 2009; **54**: 2205 – 2241.
- Antman EM, Anbe DT, Armstrong PW, Bates ER, Green LA, Hand M, et al. ACC/AHA Guidelines for the Management of Patients With ST-Elevation Myocardial Infarction- Executive Summary: A Report of the American College of Cardiology/American Heart Association Task Force on Practice Guidelines (Writing Committee to Revise the 1999 Guidelines for the Management of Patients With Acute Myocardial Infarction). *Circulation*. 2004; **110**: 588 – 636.
- Larsen AI, Galbraith PD, Ghali WA, Norris CM, Graham MM, Knudtson ML. Characteristics and outcomes of patients with acute myocardial infarction and angiographically normal coronary arteries. *Am J Cardiol*. 2005; **95**: 261 – 263.
- Ferreira M, Santos-Silva PR, de Abreu LC, Valenti VE, Crispim V, Imaizumi C, et al. Sudden cardiac death athletes: a systematic review. *Sports Med Arthrosc Rehabil Ther Technol*. 2010; **2**: 19.
- Bille K, Figueiras D, Schamasch P, Kappenberger L, Brenner JJ, Meijboom FJ, et al. Sudden cardiac death in athletes: the Lusanne Recommendations. *Eur J Cardiovasc Prev Rehabil*. 2006; **13**: 859 – 875.
- Betriu A, Pare JC, Sanz GA, Casals F, Magriña J, Castañer A, et al. Myocardial infarction with normal coronary arteries: a prospective clinical-angiographic study. *Am J Cardiol*. 1981; **48**: 28 – 32.
- Altura BM, Altura BT, Carella A. Ethanol produces coronary vasospasm: evidence for a direct action of ethanol on vascular muscle. *Br J Pharmacol*. 1983; **78**: 260 – 262.
- Moreyre AE, Kostis JB, Passannante AJ, Kuo PT. Acute myocardial infarction in patients with normal coronary arteries after acute ethanol intoxication. *Clin Cardiol*. 1982; **5**: 425 – 430.
- Sueda S, Kohno H, Fukuda H, Ochi N, Kawada H, Hayashi Y, et al. Clinical impact of selective spasm provocation tests: comparisons between acetylcholine and ergonovine in 1508 examinations. *Coron Artery Dis*. 2004; **15**: 491 – 497.
- Lee KJ, Lee SH, Hong KP, Park JE, Seo JD, Gwon HC. Feasibility and safety of the transradial approach for the intracoronary spasm provocation test. *Catheter Cardiovasc Interv*. 2005; **65**: 240 – 246.
- Nakao K, Ohgushi M, Yoshimura M, Morooka K, Okumura K, Ogawa H, et al. Hyperventilation as a specific test for diagnosis of coronary artery spasm. *Am J Cardiol*. 1997; **80**: 545 – 549.
- Simioni P, Tormene D, Tognin G, Gavasso S, Bulato C, Iacobelli NP, et al. X-linked thrombophilia with a mutant factor IX (Factor IX Padua). *N Engl J Med*. 2009; **361**: 1671 – 1675.
- Midio AF, de Moraes Moreau RL, Silva OA. The possibilities of hair analysis in the determination of involuntary doping in sports. *Sports Med*. 2001; **31**: 321 – 324.
- Crump R, Shandling AH, VanNatta B, Ellestad M. Prevalence of patent foramen ovale in patients with acute myocardial infarction and angiographically normal coronary arteries. *Am J Cardiol*. 2000; **85**: 1368 – 1370.
- Carano N, Agnetti A, Hagler DJ, Tchana B, Squarcia U, Bernasconi S. Acute myocardial infarction in a child: Possible pathogenic role of patent foramen ovale associated with heritable thrombophilia. *Pediatrics*. 2004; **114**: 255 – 258.
- Sastry S, Riding G, Morris J, Taberner D, Cherry N, Heagerty A, et al. Young adult myocardial infarction and ischemic stroke: the role of paradoxical embolism and thrombophilia (The YAMIS Study). *J Am Coll Cardiol*. 2006; **48**: 686 – 691.
- Hara H, Virmani R, Ladich E, Mackey-Bojack S, Titus J, Reisman M, et al. Patent foramen ovale: Current pathology, pathophysiology, and clinical status. *J Am Coll Cardiol*. 2005; **46**: 1768 – 1776.
- Iuliano L, Micheletta F, Napoli A, Catalano C. Myocardial infarction with normal coronary arteries: a case report and review of the literature. *J Med Case Rep*. 2009; **3**: 24.
- Bugiardini R, Bairey Merz CN. Angina with “normal” coronary arteries: a changing philosophy. *JAMA*. 2005; **293**: 477 – 484.
- Proudfit WL, Brusckhe VG, Sones FM Jr. Clinical course of patients with normal or slightly or moderately abnormal coronary arteriograms: 10 year follow-up of 521 patients. *Circulation*. 1980; **62**: 712 – 717.
- Raymond R, Linch J, Underwood D, Leathermann J, Razavi M. Myocardial infarction and normal coronary arteriography: A 10-year clinical and risk analysis of 74 patients. *J Am Coll Cardiol*. 1988; **11**: 471 – 477.
- Terefe YG, Niraj A, Pradhan J, Kondur A, Afonso L. Myocardial infarction with angiographically normal coronary arteries in the contemporary era. *Coron Artery Dis*. 2007; **18**: 621 – 626.
- Golzio PG, Orzan F, Ferreo P, Bobbio M, Bergerone S, Di Leo M, et al. Myocardial infarction with normal coronary arteries: A ten-year follow-up. *Ital Heart J*. 2004; **5**: 732 – 738.