

Original Article

Anterior Scoring Approach for Prominent Ear Anomaly: A Modified Chongchet Technique

Farhad Hafezi MD FACS¹, Bijan Naghibzadeh MD FACS², Amir Hossein Nouhi MD³, Ghazal Naghibzadeh⁴

Abstract

Background: One of the most common facial anomalies is the presence of a prominent ear. Numerous surgical techniques have been introduced in the literature for correction of this anomaly, which include suturing and sculpturing the ear cartilage. However, each has different complications. The modified Chongchet technique is one of the less invasive methods and can correct the above abnormality with satisfying results.

Methods: From July 2001 to March 2011, 19 cases of prominent ear were corrected using the modified Chongchet technique. The mean follow-up period was approximately 4.5 years. We employed an anterior approach and partial-thickness scaphal cartilage scoring in these cases.

Results: We observed no recurrences and no sharp cartilage protrusions following the surgeries. Additionally, all patients expressed satisfaction with the results.

Conclusion: We propose that the modified Chongchet approach is less aggressive and has improved surgical outcomes. One of the adverse effects of this procedure is unpredictable warping of the cartilage, which may result in asymmetry.

Keywords: Cartilage, ear auricle, plastic surgery

Cite the article as: Hafezi F, Naghibzadeh B, Nouhi AH, Naghibzadeh G. Anterior Scoring Approach for Prominent Ear Anomaly: A Modified Chongchet Technique. *Arch Iran Med.* 2013; **16**(4): 225 – 228.

Introduction

One of the most common facial and external ear anomalies is a prominent ear, with an incidence of 5% of normal deliveries.¹ Its pattern of inheritance is autosomal-dominant with varying degrees of penetration.²⁻⁵ This deformity occurs in utero at approximately ten weeks of gestation.⁶ Because 85% of auricular growth is completed by three years of age, this abnormal appearance presents in early life.⁷ The male to female ratio for incidence is approximately one to one, and the condition is more common in Caucasians.^{8,9} Prominauris, or prominent ear, produces a deformed appearance in young children most often when they begin school. Since it is accompanied by distress, therefore prominauris may cause psychological troubles throughout a person's life.⁹⁻¹² In the Western world, parents are sensitive to this deformity and refer to the physician as soon as the problem becomes detectable. Interestingly in the Eastern world, including Iran, people are less concerned and either ignore the condition or seek professional advice at later ages.

The three-dimensional position of the auricle in relation to the face and mastoid bone is a 17–21 mm distance of the helical rim from the mastoid bone¹³ with a 20–30 degree auriculomastoid angle.¹⁴ These characteristics are usually seen bilaterally although unilateral involvement is not rare. These parameters are consid-

ered normal for the ear position, and measurements beyond these criteria are theoretically considered lop ears. However, the opinions of the parents, patient and surgeon are more crucial when making the decision to intervene.³ Anatomically, a prominent ear lacks the antihelix fold or the big conchal bowl, or a combination of both.^{15,16} A successful surgical plan is based on the detection of degree of involvement of these components.^{13,14,16,17}

The first successful prominent ear surgery was performed by Dieffenbach in 1845.¹⁸ Subsequently, more than 200 various techniques have been introduced by different authorities. This diversification means that no single successful procedure has satisfied all surgeons. These techniques are based on two main categories, or their combination. Suturing, pioneered by Mustarde's mattress sutures or Furnas' concha-mastoid sutures, and sculpting as presented by Stenstrom¹⁹ and Chongchet,²⁰ are the most commonly performed cartilage scoring procedures.

Suture procedures are considered for permanent suturing of different auricular parts to create a helical fold or fixate the auricle to the mastoid bone. The sculpting technique consists of making incisions and excisions, followed by scoring. Numerous surgeons prefer to merge the suturing and sculpting technique.^{8,14} The Nolst Trenité²¹ and modified Becker²² techniques are examples of this combination.²³

In this paper, we introduce the modified Chongchet technique, which includes scoring of the antihelical area to produce a fold, remove the excess concha (if present), and use concha-mastoid sutures. In our opinion, this technique is easy to learn, with its less steep learning curve, and offers less post-operative complications.

Materials and Methods

To prevent psychological stress, as caused by peer teasing in pri-

Authors' affiliations: ¹Department of Plastic Surgery, Tehran University of Medical Sciences, Hazrat-e-Fatemeh Hospital, Tehran, Iran. ²Department of Otolaryngology and Head and Neck Surgery, Shahid Beheshti University of Medical Sciences, Loghman-e Hakim Hospital, Tehran, Iran. ³Department of Pathology, Kowsar Private Laboratory, Tehran, Iran. ⁴Tehran University of Medical Sciences, Tehran, Iran.

Corresponding author and reprints: Farhad Hafezi MD FACS, ¹Department of Plastic Surgery, Tehran University of Medical Sciences, Hazrat-e-Fatemeh Hospital, Tehran, Iran. Telefax +98212-225-0623
Accepted for publication: 6 February 2013

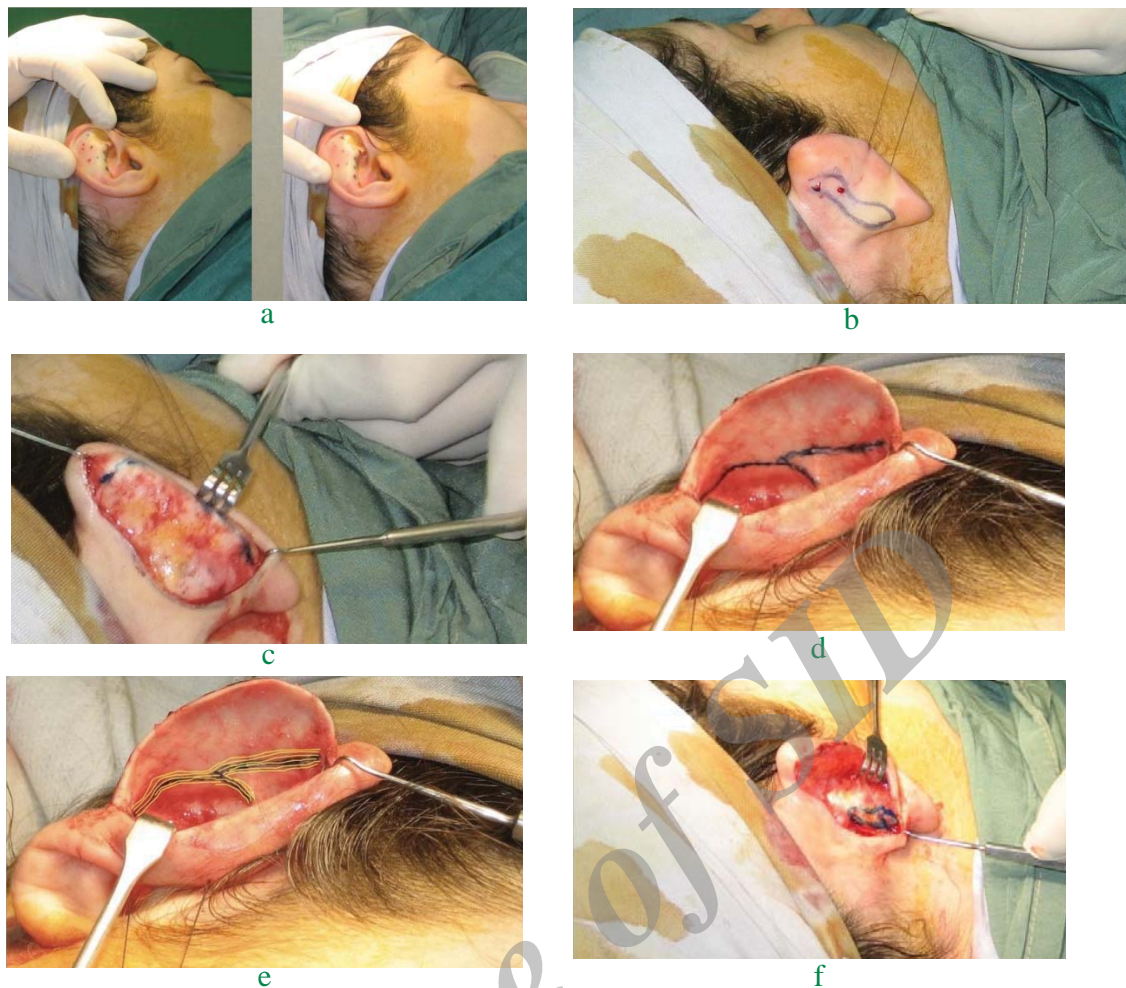


Figure 1. **a)** Future antihelix fold marked with methylene blue. **b)** S-shaped skin excision at the post-auricular. **c)** Posterior view of concha and scapha. **d)** The future antihelix based on previous markings. **e)** Multiple longitudinal partial-thickness cuts to produce a smooth antithetical fold. **f)** Excess concha is marked for excision.

mary school,^{3,14} we prefer to begin surgical correction during the preschool years (4–6 years) because 85% of ear growth is completed by age three.⁵

From July 2001 to March 2011, 19 cases of prominent ear (17 bilateral and 2 unilateral) were corrected using the modified Chongchet technique by FH and BN (Table 1).

The surgery was performed with the patient under local anesthesia and intravenous sedation. In young children, general anesthesia is required. In each case, the posterior surface of the ear and anterior surface over the antihelix and concha were infiltrated with 1% xylocaine and adrenaline (1:200,000). This produced a bloodless field, which made it easier to undermine the skin.²⁴ The operation began by marking the future antihelix fold with needle-pierced deep methylene blue (Figure 1a). An S-shaped skin excision was made at the post-auricular area approximately 1.5 cm lateral to the auriculo-mastoid sulcus (Figure 1b). Complete exposure of the anterior auricle was achieved by meticulous skin undermining through this incision. At this point, an incision was made to separate the helix from the scapha; then, we accessed the anterior side of the scapha by anteriorly undermining the skin. At this point, we had an almost complete view of the antihelix (Figure 1c). The future antihelix was based on previous markings and scored by multiple longitudinal partial-thickness cuts to produce a

smooth antithetical fold (Figures 1d and 1e). Parallel-line hatching of the concave antihelix cartilage releases the interlocking forces and results in deviation toward the convex surface. To decrease the conchal bowl (if necessary), we excised the oval-shaped piece of cartilage from the posterior side of the auricle (Figure 1f). A permanent suture (nylon 4–0) was applied to approximate the concha-to-mastoid periosteum. Then, the skin was closed by running stitches (Monocryl 5–0). The dressing was allowed to remain in place for 24 hours. We have recommended that patients use an elastic headband for four weeks.

The follow-up period for these patients ranged from 3 months to 8 years with a mean of 4.5 years. We found no recurrences, sharp cartilage protrusions, telephone or reverse telephone deformities in any of the above cases. No complications of hematoma or skin necrosis were detected in the above series (Figures 2a and 2b).

Results

The adverse effects include unpredictable warping of the cartilage, which might result in asymmetry. This complication occurred in two cases, although it was not detected by the patients. All patients were satisfied with the procedure.

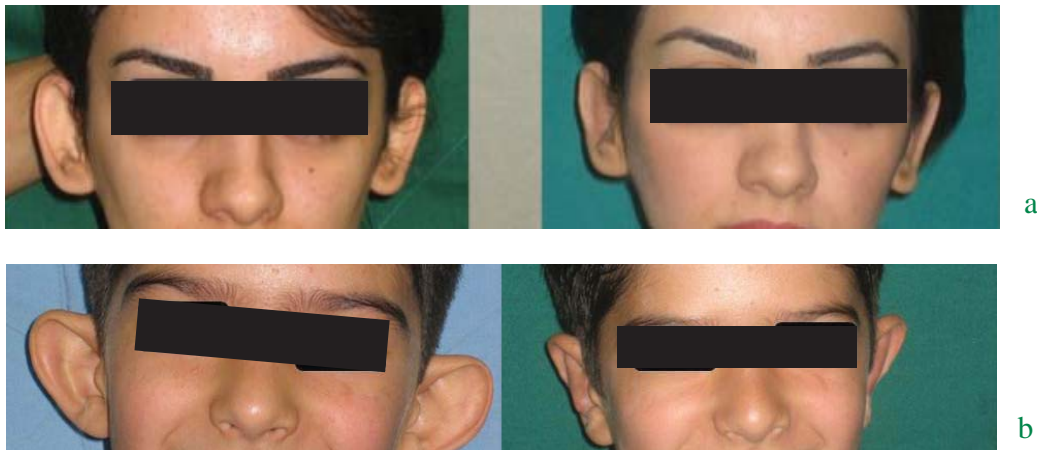

Figure 2. a) Pre- and 18 months post-operative photos in a 23-year-old female. b) Severe bilateral lop ear deformity in an eight-year-old boy. Antero-posterior view, pre- and 14 month post-operative photos.

Discussion

The performance of a successful prominent ear surgery includes the following aims^{23,24}: i) a visible, well-defined antihelix fold (compared with the helix from an anterior view); ii) decreased conchal prominence; iii) decreased concha-mastoid angle; and iv) reduced cephalo-auricular distances.

Initially, prominent ear surgery was divided between two different approaches, the sculpting-only technique^{25,26} and the suturing-only technique.^{27,28} Of the surgical techniques, the majority include an elliptical excision of the retro-auricular skin. Many involve fixation of the concha to the mastoid. These techniques use various methods to create the antihelical fold. Suture-only techniques are usually favored because of precise control, but Tan has reported²⁹ a significantly higher revision rate when using Mustardé sutures. However, sculpting techniques permanently alter the structure of the auricular cartilage, but it is not possible to predict the final result.

Cutting and sculpting will permanently change the form and shape of the ear. Sculpting techniques have the risk of cartilage irregularities and the production of sharp edges.^{3,21,30,31,32} Because of these problems, different combinations of the above techniques have been developed to decrease the rate of complications and achieve better results.

Unsatisfactory aesthetic complications resulting from conventional prominent surgery encompass a wide variety of sequelae, including overcorrection, undercorrection, reprotrusion, telephone deformities due to undercorrection of the superior helix and lobule, or overcorrection of the middle third of the ear. All can result in relatively prominent superior and inferior poles. The reverse telephone deformity is characterized by a prominent concha and is caused by inadequate correction of the prominent conchal bowl or overcorrection of the superior and inferior poles and cartilage irregularities.^{8,14,15,33}

Late complications of prominent ear surgery may include suture extrusion, scarring, hypersensitivity, asymmetry and unaesthetic results. Cumulative late complication incidences have varied from 0% to 47.3%.^{8,34} Full-thickness cartilage incisions may produce permanent visible irregularities, pointed tips and sharp edges on the auricles. In 1961, Strombeck has reported a follow-up study of a full-thickness cartilage-cut technique with 25% of patients disappointed because of sharp, unnatural folds.³⁵

In 1958, an important finding by Gibson and Davis has proven that unilateral cutting or scoring of the costal cartilage releases the force produced by a taut outer layer, which is intended to keep the cartilage straight.³⁶ Cutting this taut layer and releasing these invisible bands causes the force on the other side of cartilage to bend toward the intact side, resulting in a so-called warping effect. This phenomenon has been proved to be applicable in both septal and ear cartilage. Thus, this finding became the basis for septal deviation surgeries and ear cartilage reshaping.

The partial-thickness scoring keeps cartilage integrity but changes its shape permanently with minimum deformity and, if performed properly, without sharp edges. This shape change begins immediately on the operating table, and it has been observed that pieces of cartilage cut from the nasal septum warped within 15 to 30 minutes to approximately 90 percent of their end warpage.⁴⁷

Chongchet's method of anterior scoring, which employs the above concept of helical fold reconstruction is a commonly used procedure in many centers in the UK. Some centers have claimed good aesthetic outcomes using a modification of Chongchet's method, such as closed anterior scoring or anterior scoring combined with posterior rolling methods.^{38,39} Calder and Naasan have reviewed their experiences with 562 otoplasties performed via the anterior scoring technique.⁴⁰ The most common complication was recurrence (8%), followed by infection, keloid scarring, hemorrhage and anterior skin necrosis. Jeffery reported a complication rate of 23.75% with anterior scoring⁴¹; however, the repeat operation rate for recurrence was low (3.3%).⁴² The comparatively low rate of complications and good surgical outcomes (including less damage to scaphal cartilage) have encouraged us to use this method over the past decade.

Conclusion

The ultimate goal for prominent ear correction surgery is the reproduction of natural, symmetrical-looking ears with no obvious signs of surgery and minimal complications or recurrences. The learning curve of the discussed technique is not steep; furthermore, there is no chance of suture extrusion or rupture and no return to the preoperative position due to loss of cartilage memory. The shortcomings of this approach include its less predictable results.

References

1. Panettiere P, Marchetti L, Accorsi D, Del Gaudio GA. Otoplasty: a comparison of techniques for antihelical defects treatment. *Aesth Plast Surg*. 2004; **27**: 462 – 465.
2. Kompatscher P, Schuler CH, Clemens S, Seifert B, Beer GM. The cartilage-sparing versus the cartilage-cutting technique: a retrospective quality control comparison of the Francesconi and Converse otoplasties. *Aesth Plast Surg*. 2003; **27**: 446 – 453.
3. Kelley P, Hollier L, Stal S. Otoplasty: evaluation, technique, and review. *J Craniofac Surg*. 2003; **14**: 643 – 653.
4. Bartkowski SB, Szuta M, Zapala J. Pitanguy's method of protruding ear correction from our own experience: review of 80 cases. *Aesthetic Plast Surg*. 2001; **25**: 103 – 110.
5. Sclafani AP, Ranaudo J. Otoplasty. eMedicine. Available from: URL: <http://www.emedicine.com/ent/topic110.htm> (Accessed 2006).
6. Porter CJW, Tan ST. Congenital auricular anomalies: topographic anatomy, embryology, classification and treatment strategies. *Plast Reconstr Surg*. 2005; **115**: 1701 – 1712.
7. Adamson JE, Horton CE, Crawford HH. The growth pattern of the external ear. *Plast Reconstr Surg*. 1965; **36**: 466.
8. Campbell AC. Otoplasty. *Facial Plast Surg*. 2005; **21**: 310 – 316.
9. Adamson PA, Strecker HD. Otoplasty techniques. *Facial Plast Surg*. 1995; **11**: 284 – 299.
10. Wood-Smith D. Otoplasty. In: Rees T, ed. *Aesthetic Plastic Surgery 2*. Philadelphia: WB Sanders; 1980: 833.
11. Bogetti P, Boltri M, Spagnoli G, P Balocco. Otoplasty for prominent ears with combined techniques. *Eur J Plast Surg*. 2003; **26**: 144 – 1448.
12. Macgregor FC. Ear deformities: social and psychological implications. *Clin Plast Surg*. 1978; **5**: 347 – 350.
13. Preuss S, Eriksson E. Prominent ears. In: Van der Kolk E, ed. *Plastic surgery: indicators, Operations and Outcomes*. St Louis: Mosby; 2000: 1057 – 1065.
14. Nachlas NE. Otoplasty. In: Papel ID, ed. *Facial Plastic and Reconstructive Surgery*. 2nd ed. New York, Stuttgart: Thieme; 2002: 309e21.
15. Furnas DW, Lin SJ. Ear, prominent ear. eMedicine. Available from: URL: <http://www.emedicine.com/plastic/topic454.htm> (Accessed 2007)
16. Elliott Jr RA. Complications in the treatment of prominent ears. *Clin Plast Surg*. 1978; **5**: 479 – 490.
17. Janis JE, Rohrich RJ, Gutowski KA. Otoplasty. *Plast Reconstr Surg*. 2005; **115**: 60e – 72e.
18. Dieffenbach JF. *Die Operative Chirurgie*. Leipzig: F.A. Brockhaus; 1845.
19. Stenstrom SJ. A natural technique for correction of congenitally prominent ears. *Plast Reconstr Surg*. 1963; **32**: 509.
20. Chongchet V. A method of antihelix reconstruction. *Br J Plast Surg*. 1963; **16**: 268.
21. Nolst Trenite' GJ. Otoplasty: a modified anterior scoring technique. *Facial Plast Surg*. 2004; **20**: 277 – 285.
22. Lee D, Bluestone CD. The Becker technique for otoplasty: modified and revisited with long-term outcomes. *Laryngoscope*. 2000; **110**: 949 – 954.
23. Limandjaja GC, Breugem CC, Mink van der Molen AB, Kon M. Complications of otoplasty: a literature review. *J Plast Reconstr Aesthet Surg*. 2009; **62**: 19 – 27.
24. Salgarello M, Gasperoni C, Montagnese A, Farallo E. Otoplasty for prominent ears: a versatile combined technique to master the shape of the ear. *Otolaryngol Head Neck Surg*. 2007; **137**: 224 – 227.
25. Stenström SJ. A natural technique for correction of congenitally prominent ears. *Plast Reconstr Surg*. 1963; **32**: 509 – 518.
26. Stenström SJ. A simple operation for prominent ears. *Acta Otolaryngol*. 1966; **27**: 393.
27. Mustarde JC. The correction of prominent ears using simple mattress sutures. *Br J Plast Surg*. 1963; **16**: 170 – 176.
28. Furnas DW. Correction of prominent ears by concha-mastoid sutures. *Plast Reconstr Surg*. 1968; **42**: 189 – 193.
29. Tan KH. Long-term survey of prominent ear surgery: a comparison of two methods. *Br J Plast Surg*. 1986; **39**: 270 – 273.
30. Horlock N, Misra A, Gault DT. The postauricular fascial flap as an adjunct to Mustarde' and Furnas type otoplasty. *Plast Reconstr Surg*. 2001; **108**: 1487 – 1490.
31. Vuyk HD. Cartilage-sparing otoplasty: a review with long-term results. *J Laryngol Otol*. 1997; **111**: 424 – 430.
32. Adamson PA, McGraw BL, Tropper GJ. Otoplasty: critical review of clinical results. *Laryngoscope*. 1991; **101**: 883 – 888.
33. Adamson PA, Strecker HD. Otoplasty techniques. *Facial Plast Surg*. 1995; **11**: 284 – 299.
34. Ohlse'n L, Vedung S. Reconstructing the antihelix of protruding ears by perichondrioplasty: a modified technique. *Plast Reconstr Surg*. 1980; **65**: 753e – 762e.
35. Strombeck JO. Results of surgery for protruding ears. A follow-up study of two series, one treated with a modification of Luckett's operation and one with a "new" technique. *Acta Chir Scand*. 1961; **122**: 138 – 146.
36. Gibson T, Davis WB. The distortion of the autogenous cartilage grafts: its cause and prevention. *Br J Plast Surg*. 1958; **10**: 257.
37. Harris S, Pan Y, Peterson R, Stal S, Spira M. Cartilage warping: an experimental model. *Plast Reconstr Surg*. 1993; **92**: 912 – 915.
38. Peker F, Celikoz B. Otoplasty: anterior scoring and posterior rolling techniques in adults. *Aesthetic Plast Surg*. 2002; **26**: 267.
39. Thomas SS, Fatah F. Closed anterior scoring for prominent ear correction revisited. *Br J Plast Surg*. 2001; **54**: 581.
40. Calder JC, Naasan A. Morbidity of otoplasty: a retrospective review of 562 consecutive cases. *Br J Plast Surg*. 1994; **47**: 170.
41. Jeffery S. Complications following correction of prominent ears: an audit review of 122 cases. *Br J Plast Surg*. 1999; **52**: 588.
42. Mandal A, Bahia H, Ahmad T, Stewart KJ. Comparison of cartilage scoring and cartilage sparing otoplasty--A study of 203 cases. *J Plast Reconstr Aesthet Surg*. 2006; **59**: 1170 – 1176.