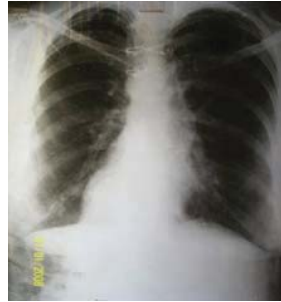
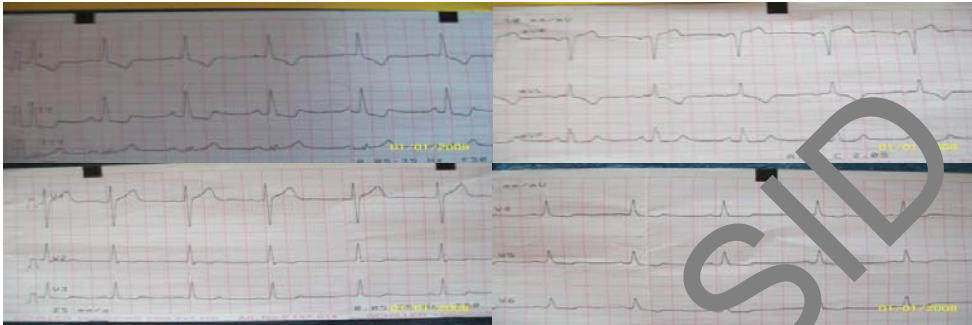
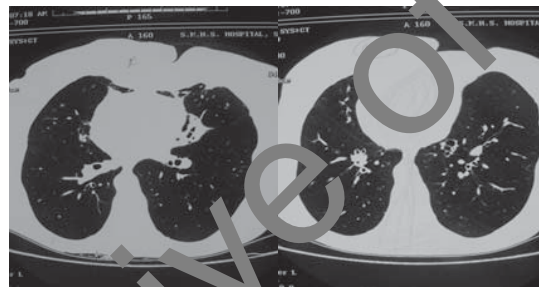
## Photoclinic



**Figure 1.** Chest X-ray showed not only the presence of bronchiectasis, particularly in the lower zones, but also dextrocardia.



**Figure 2.** ECG of the patient remarkable for a T wave inversion in II, III, and aVL.



**Figure 3.** HRCT of the chest showed the presence of dextrocardia and bronchiectasis in the lingula and signet ring sign.

**Cite the article as:** Siraj F, Hussain MM, Showkat H, Sarmast AH, Dar NA, Bhat GM. Photoclinic. *Arch Iran Med.* 2013; **16**(2): 129 – 130.

A 50-year-old female patient presented with productive cough, rhinorrhea, and headaches for the past 16 years. She had episodic fever and worsening of symptoms. Her previous record showed numerous medical tests, including those for tuberculosis (such as repeat chest X-rays) and sputum examination. Her medical record revealed that she received several courses of antibiotics, antihistamines, and bronchodilators, in addition to inhaled and oral corticosteroids, however, the response was only partial and temporary. Considering her ill health, the duration of symptoms, and uncertainty about the cause of the disease, the patient was

**Farhana Siraj MD<sup>1</sup>, Mir Mohammad Hussain MD<sup>1</sup>, Hakim Irfan Showkat MD<sup>2</sup>, Arif Hussain Sarmast MD<sup>3</sup>, Nazir Ahmad Dar MD<sup>4</sup>, Gull Mohammad Bhat MD<sup>5</sup>**

**Authors' affiliations:** <sup>1</sup>Department of Internal Medicine, Sheri-i-Kashmir Institute of Medical Sciences, Srinagar, India. <sup>2</sup>Department of Internal Medicine Sheri-i-Kashmir Institute of Medical Sciences, Srinagar, India. <sup>3</sup>Department of Surgery, Sheri-i-Kashmir Institute of Medical Sciences, Srinagar, India. <sup>4</sup>Department of Internal Medicine, Sheri-i-Kashmir Institute of Medical Sciences medical college Srinagar, India. <sup>5</sup>Department of Medical Oncology, Sheri-i-Kashmir Institute of Medical Sciences, Srinagar, India.

**•Corresponding author and reprints:** Hakim Irfan Showkat MD, Post Graduate Scholar Internal Medicine SKIMS Srinagar Kashmir India 190001. Tel:+91-941-902-8326, E-mail: docirfanshahi512@gmail.com.

Accepted for publication: 1 August 2012

admitted to the hospital. On examination she was febrile with nasal discharge, a wheezy chest, and bilateral coarse crackles. Her heart sounds were heard best on the right side of her chest. There was no digital clubbing. Initial suspicion was that of bronchial asthma with recurrent chest infections; there was a possibility of cystic fibrosis. However, chest X-rays showed not only bronchiectasis (particularly in the lower zones), but also dextrocardia (Figure 1). Sinus radiographs showed mucosal thickening, opacified sinus cavities, and other features of chronic sinusitis. ECG of the patient remarkable for a T wave inversion in II, III, and aVL (Figure 2). HRCT of the chest showed the presence of dextrocardia and bronchiectasis in the lingula and signet ring sign (Figure 3).

Considering the clinical picture of the patient, sinusitis, bronchiectasis, and situs inversus, the clinical diagnosis of Kartagener's Syndrome was made. The condition was explained to the patient and she was treated with antibiotics, antipyretics, mucolytics, and inhaled bronchodilators.

**What is your diagnosis?  
See the next page for diagnosis.**

Kartagener's Syndrome is a rare, autosomal recessive disorder<sup>1</sup> characterized by dextrocardia, bronchiectasis, and sinusitis.<sup>2</sup> Siewert initially described this condition in 1904; thus this disorder is sometimes called Siewert Syndrome. However, the details of this condition have been provided by Kartagener in 1933, thus it is commonly known as Kartagener's Syndrome. Sinusitis, situs inversus, bronchiectasis, and male infertility that occur with this condition are attributed to abnormal ciliary motility. Cilia may be either immotile or show uncoordinated, inefficient movement patterns. Ciliary movement disorders may be congenital or acquired. Congenital ciliary disorders are labeled as primary ciliary dyskinesia (PCD). Approximately one half of the patients with PCD have situs inversus. Those patients having PCD with situs inversus are known to have Kartagener's Syndrome.<sup>3</sup>

It has been proposed that abnormal ciliary beating is necessary for visceral rotation during embryonic development. In patients that have PCD half will have situs inversus and will become cases of Kartagener's Syndrome; the other half will have normal situs due to random rotation.<sup>4</sup> Abnormal ciliary motility results in the general impairment of respiratory defense mechanisms due to problems with bacterial clearance leading to recurrent upper and lower respiratory tract infections. Among cilia abnormalities, the structural abnormalities of dynein arms are the most common.<sup>5</sup> Abnormalities of the radial spokes and microtubules can also account for this condition. In rare cases no structural ciliary abnormality is detected even though ciliary function is abnormal and the clinical syndrome is typical.<sup>6,7</sup> Patients with Kartagener's Syndrome may only have either situs solitus (dextrocardia) or situs inversus totalis, where all the viscera are on the opposite side<sup>4</sup> (including a left-sided appendix).<sup>8</sup> The patient in this case had situs inversus totalis.

A lung CT-scan demonstrates peribronchial thickening and bronchiectasis, which is mostly marked in the lower zones.<sup>9</sup> High resolution CT shows that pulmonary disease related to PCD predominantly involves the middle and lower lung lobes.<sup>10</sup> Although pneumonia is frequently seen in Kartagener's Syndrome, lung abscess infrequently accompanies it.<sup>11</sup>

Cutaneous lesions in Kartagener's Syndrome are nummular eczema, recurrent deep folliculitis, and pyoderma gangraenosum.<sup>12</sup> There were no cutaneous lesions observed in our patient.

The diagnosis of Kartagener's Syndrome is made clinically and confirmed through transmission electron microscopy.<sup>13</sup> Screening test for PCD includes nasal nitric oxide and *in vivo* tests of ciliary motility, such as the saccharin test. Specific diagnosis requires examination of cilia by light and electron microscopies, with epithelial culture in doubtful cases.<sup>14</sup> Since there is no specific therapy for PCD, it is recommended that upon diagnosis secondary infections be treated with potent antibiotics and prophylactic interventions.<sup>15</sup>

Combined heart-lung transplantation has been introduced as an effective treatment modality. This procedure is performed in a limited number of patients because of the low probability of

finding a suitable donor with situs inversus and the absence of situs solitus, which imposes major surgical difficulties.<sup>16</sup> Double-lung transplantation offers the potential advantages of preserving the native heart, thereby optimizing the organ's use and allowing a shorter lung ischemic time.<sup>17</sup>

In conclusion, prompt and appropriate treatment of respiratory infections can minimize irreversible lung damage in such cases.

## References

- Gorham GW, Merselis JG, Jr Kartagener's triad: a family study. *Bull Johns Hopkins Hosp.* 1959; **104**: 11 – 16.
- Kartagener M, Horiacher A. Situs Viscerum inversus and polyposis nasi in einem Falle familiaerer Bronchiectasien. *Beitr Klin Tub.* 1936; **87**: 331 – 333.
- Olbrich H, Haffnax K, Kipert A, Volkel A, Volz A, Sasmaz G, et al. Mutation in DNAH5 cause primary ciliary dyskinesias and randomization of left-right symmetry. *Nature Genet.* 2002; **30**: 143 – 144.
- None PG, Bali D, Carlson JL, Simpson A, Gipson CL, Ostrowski LE, et al. Discordant organ laterality in monozygotic twins with primary ciliary dyskinesia. *Am J Med Genet.* 1999; **82**: 155 – 600.
- Eavey RD, Holmas LB Jr, Holmas LB, Laird NM, Lapey A, Joseph MP, et al. Kartagener's Syndrome: a blinded controlled study of cilia ultrastructure. *Arch Otolaryngol Head Neck Surg.* 1986; **112**: 646 – 650.
- Herman F, Murphy S. Normal ciliary ultrastructure in children with Kartagener's syndrome. *Ann Otol Rhinol Laryng.* 1980; **89**: 81 – 83.
- Stollow DV, Katz SM. Immotile cilia syndrome. *New Eng J Med.* 1982; **308**: 895.
- Jonsson MS, Mc Cormick JR, Gillies CG, Gondos B. Kartagener's syndrome with motile spermatozoa. *New Eng J Med.* 1982; **307**: 1131 – 1133.
- Jain K, Padley SP, Goldstraw EJ, Kidd SJ, Hogg C, Biggart E, et al. Primary ciliary dyskinesia in the paediatric population: range and severity of radiological findings in a cohort of the patients receiving tertiary care. *Clin Radio.* 2007; **62**: 986 – 993.
- Kennedy MP, Noone PG, Leigh MW, Zariwala MA, Minnick SL, Knowles MR, et al. High resolution CT of patients with primary ciliary dyskinesia. *AJR Am J Roentgenol.* 2007; **188**: 1232 – 1238.
- Masaki H, Ahmad K, Eujishita M, Takasugi M, Rikitomi N, Twagaki A, et al. A case of Kartagener's syndrome with *S. pneumoniae* lung abscess. *Kansenshogaku Zasshi.* 1993; **67**: 355 – 360.
- Vazquez J, Fernandez-Redondo V, Sanchez-Aguilar D, Toribiu J. Cutaneous manifestation in Kartagener's syndrome: folliculitis, nummular eczema, and pyoderma gangraenosum. *Dermatology.* 1993; **186**: 269 – 271.
- Ortega HA, Vega Nde A, Santos BQ, Maia GT. Primary ciliary dyskinesia consideration regarding six causes of Kartagener's syndrome. *J Bras Pneumol.* 2007; **33**: 602 – 608.
- Bush A, Chodhari R, Collins N, Copeland F, Hall P, Harcourt J, et al. Primary ciliary dyskinesia: current state of the art. *Arch Dis Child.* 2007; **92**: 1136 – 1140.
- Gomez de Terreros Cara FS, Gomez-Stern Aguilar C, Alvarez-Sala Walther R, Prados Sanchez C, Garcia Rio F, Villamor Lean J. Kartagener's syndrome diagnosis in a 75-year-old woman. *Arch Bronconeumol.* 1999; **35**: 242 – 244.
- Macchiarini P, Chapelier A, Vouhe P, Cerrina J, Ladurie FL, Parquin F, et al. Double lung transplantation *in situs* inversus with Kartagener's syndrome. Paris-Sud University Lung Transplant Group. *J Thorac Cardiovasc Surg.* 1994; **108**: 86 – 91.
- Patterson GA, Cooper JD, Goldman B, Weisel RD, Pearson FG, Waters PF, et al. Technique of successful clinical double-lung transplantation. *Ann Thorac Surg.* 1988; **45**: 626 – 633.

Surf and download all data from SID.ir: [www.SID.ir](http://www.SID.ir)

Translate via STRS.ir: [www.STRS.ir](http://www.STRS.ir)

Follow our scientific posts via our Blog: [www.sid.ir/blog](http://www.sid.ir/blog)

Use our educational service (Courses, Workshops, Videos and etc.) via Workshop: [www.sid.ir/workshop](http://www.sid.ir/workshop)