

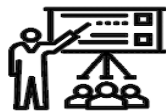SID



سرویس های ویژه



سرویس ترجمه تخصصی



کارگاه های آموزشی



بلاگ مرکز اطلاعات علمی



سامانه ویراستاری STES



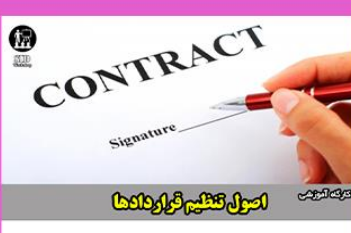فیلم های آموزشی

کارگاه های آموزشی مرکز اطلاعات علمی



مقاله نویسی علوم انسانی

مقاله نویسی علوم انسانی



اصول تنظیم قراردادها

اصول تنظیم قراردادها



آموزش مهارت های کاربردی در تدوین و چاپ مقاله

آموزش مهارت های کاربردی در تدوین و چاپ مقاله

Modified Intraoperative Saline Injection Leak Test to Assess Mitral Valve Repair

Mohammad Abbasi¹, Mahmood Hosseinzadeh Maleki², Hadi Javan³, Ahmad Amouzeshi⁴, Ali Asghar Moeinipour⁵, Alireza Sepehri Shamloo⁶, Nahid Zirak^{7*}

Abstract

Background: Intraoperative trans-esophageal echocardiography (TEE) and Saline injection pressurization of the left ventricle are the most popular methods to evaluate the repaired mitral valve during mitral valve repair surgery. We describe a simple and reliable intraoperative saline injection leak test method for mitral valve repair which has multiple benefits over the conventional method.

Materials and methods: Twenty patients with mitral regurgitation who met the inclusion criteria for mitral valve repair were enrolled in the study. When the repair procedure is done, a balloon catheter (12 Fr Foley catheter) is inserted into the left ventricle through the site of cardioplegia cannula on ascending aorta and inflated at the level of left ventricular outflow tract inferior to the aortic valve. The valve's competency is then evaluated by saline injection into the left ventricle through the balloon catheter.

Results: Intra operative TEE revealed trivial and mild MR in 12 and 7 patients and moderate MR in one patient. No significant discrepancy was found between the intra-operative TEE findings and the described intra-operative leak test results (p value >0.05).

Conclusion: The intraoperative saline leak test described here is a simple, safe and reliable method to assess the efficacy of mitral valve repair before chest closure. (*Iranian Heart Journal 2012; 13(2):20-23*).

Keywords: Mitral valve ■ Intraoperative period ■ Transesophageal Echocardiography

Introduction

Intraoperative assessment of the competency of the repaired mitral

valve before the closure of the atrium is an important step in a successful mitral valve repair surgery [1]. Intraoperative transesophageal echocardiography (TEE)

Received September 2012; Accepted for publication October 2012

1. Assistant Professor of Cardiovascular Surgery, Imam Reza Hospital, Mashhad University of Medical Sciences, Mashhad
2. Cardiovascular Surgery Fellow, Imam Reza Hospital, Mashhad University of Medical Sciences, Mashhad
3. Research Administrator, Imam Reza Hospital, Mashhad University of Medical Sciences, Mashhad, Iran
4. Cardiovascular Surgery Fellow, Imam Reza Hospital, Mashhad University of Medical Sciences, Mashhad
5. Assistant Professor of Cardiovascular Surgery, Imam Reza Hospital, Mashhad University of Medical Sciences, Mashhad
6. Student of Medicine, Mashhad University of Medical Sciences, Mashhad, Iran
7. Assistant Professor of Anesthesiology, Imam Reza Hospital, Mashhad University of Medical Sciences, Mashhad

*Corresponding Author: Nahid Zirak .MD,

Mailing address: Department of Anesthesiology, Imam Reza Hospital, Mashhad University of Medical Sciences, Mashhad, Iran.
Postal code: 9137913316 ,Tel: (+98)511-852-5209 Fax: (+98)511-843-7840, Email: zirakn@mums.ac.ir

and forced injection of saline into the left ventricle are the most popular methods to evaluate the repaired mitral valve after and before weaning from cardiopulmonary bypass (CPB), respectively.

TEE is the most accurate tool for the assessment of the mitral valve function, but it requires that the patient be re-warmed and weaned from CPB. In addition, if the valve function is not acceptable, the repair procedure must be reconsidered. Re-institutions of CPB may increase the side effects of extra corporal circuit due to increased pump time and multiple cooling-rewarming cycles. On the other hand, the standard saline injection test becomes unreliable when aortic valve insufficiency (AI) is present and filling of the left ventricle via the traditional method is difficult.

We here in describe a simple and reliable intraoperative saline injection leak test method for mitral valve repair which has multiple benefits over the conventional method.

Methods

Twenty patients with mitral regurgitation who met the inclusion criteria for mitral valve repair were enrolled in the study. All the patients underwent mitral valve repair through median sternotomy by means of CPB, under the monitoring of intraoperative TEE for the assessment of mitral valve repair efficacy.

Standard CPB was instituted with bicaval venous cannulation and ascending aortic return, and cardioplegia was infused within the aortic root after the cross-

to the lesions. When the repair procedure was done, the cardioplegia cannula was removed and a balloon catheter (12 Fr Foley catheter) was inserted into the left ventricle through the site of cardioplegia cannula on the ascending aorta. The balloon was inflated at the level of left ventricular outflow tract right before the aortic valve to provide a retrograde access to the left ventricular cavity while occluding the left ventricular outflow tract simultaneously (Figure 1). The competency of the valve was subsequently evaluated by saline injection into the left ventricle through the balloon catheter. The left ventricle was filled with saline such that it was filled at the end diastolic phase (as reported by pre-op echocardiography).

If the coaptation of the leaflets and the valve function were satisfactory, the repair procedure was considered successful; otherwise, the repair technique was modified until an acceptable valve function was achieved (Figure 2).

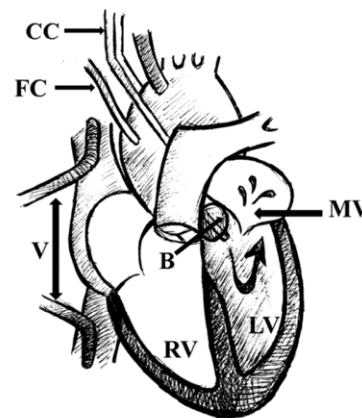


Figure 1: Catheter is inserted into the left ventricle through an incision of the cardioplegia cannula and the left ventricular outflow tract is occluded by the inflation of the balloon. CC= Cross Clamp, FC= Foley Catheter, V = Venous cannulas, B= Inflated Balloon, MV = Mitral Valve, RV= Right Ventricle, LV= Left Ventricle

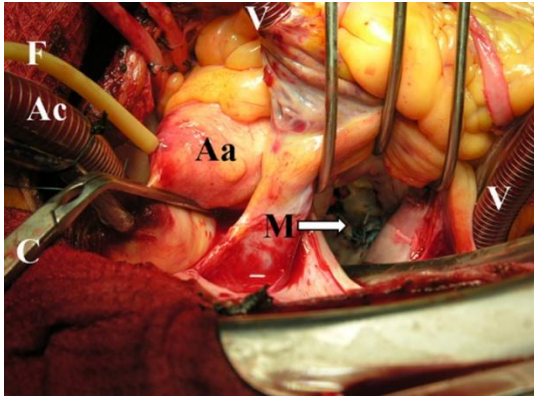


Figure 2: Post-repair competent mitral valve. **F**= Foley Catheter, **V**= Venous Cannulas, **Ac**= Aortic Cannula, **C**= Cross Clamp, **Aa**= Ascending Aorta, **M**= Repaired Mitral Valve

Results

Twenty patients, comprised of 8 men and 12 women, at a mean age of 38.3 ± 4.3 years met the inclusion criteria of mitral valve repair. The etiology of mitral lesion was degenerative in 5 and ischemic in 15 patients. Posterior ring annuloplasty plus triangular or quadrangular resection techniques were utilized to repair the mitral valve. The mean CPB and aortic cross-clamp time was 55.3 ± 16.4 and 42.0 ± 13.5 minutes, respectively. All the patients were weaned easily from CPB.

The intraoperative function of the mitral valve was evaluated based on the guidelines of the American Association for Echocardiography for the Evaluation of the Severity of Native Valvular Regurgitation with two-dimensional and Doppler echocardiography, in 2003 [2]. Intraoperative TEE revealed trivial and mild mitral regurgitation (MR) in 12 and 7 patients along with moderate MR in one patient. Consequently, the repair technique in that patient was modified and he left the operating room after a second TEE showed mild MR.

The Wilcoxon test was used to compare the intraoperative TEE findings with the described intraoperative leak test results; it showed no significant discrepancy between these two techniques (p value > 0.05).

A pre-discharge echocardiogram disclosed no significant mitral regurgitation in any of the patients included in the series. There were neither major morbidities nor mortalities.

Discussion

Conventional methods do not usually provide a precise assessment of the valve competency during the mitral valve repair procedures [1-3]. When attempting mitral valve repair, intraoperative assessment of the competency of the mitral valve is important before the closure of the atrium. Saline injection pressurization of the left ventricle through the valve or the left ventricular wall, and infusion of cardioplegic solution within the aortic root are considered to be the most common and reliable techniques used to inspect the repaired valve [4,5]. These traditional fluid-filling tests which have been accepted as standard are still useful for morphologic assessment of the integrity of the mitral apparatus during the procedure, but fail to provide a consistently precise and truly quantitative evaluation of regurgitant volume [6,7]. The left ventricular pressurization through the ventricular wall requires a small incision in the muscular wall and would leave a scar, which possibly can be a source of aneurysm formation and arrhythmia. It also fails to provide an accurate evaluation while any degree of

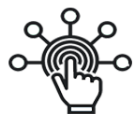aortic insufficiency is present. Our technique confers some benefits over traditional methods, as follows: 1) decreasing pump time and cooling-rewarming cycles; 2) obviating the need for aortic root venting during left ventricular filling; 3) offering reliable left ventricle filling even with an insufficient aortic valve; 4) leaving no muscular scar; and 5) affording accurate assessment of the repaired valve compared to the post-cardiopulmonary TEE.

We found a significant correlation between the intraoperative saline leak test and TEE for the evaluation of the regurgitation after mitral valve reconstruction. These findings suggest that the intraoperative saline leak test described here is a simple, safe, and reliable method to evaluate the efficacy of mitral valve repair.

References

- 1 . Nakajima M, Tsuchiya K, Okamoto Y, Suetsugu F. Intraoperative saline injection leak test--a simple method to assess mitral valve repair when a simultaneous aortotomy does not allow pressurization of the left ventricle. *Interact Cardiovasc Thorac Surg.* 2007;6:580-1.
2. Zoghbi WA, Enriquez-Sarano M, Foster E, Grayburn PA, et al.; American Society of Echocardiography. Recommendations for evaluation of the severity of native valvular regurgitation with two-dimensional and Doppler echocardiography. *J Am Soc Echocardiogr.* 2003; 16:777-802.
3. Takamoto S, Kyo S, Adachi H, Matsumura M, Yokote Y, Omoto R. Intraoperative color flow mapping by real-time two-dimensional Doppler echocardiography for evaluation of valvular and congenital heart disease and vascular disease. *J Thorac Cardiovasc Surg.* 1985;90:802-12.
- 4.Kouchoukos NT, Blackstone EH, Doty DB, Hanley FL, Karp RB. In: Kirklin JW, Barratt-Boyes BG. *Cardiac Surgery 3rd ed.* Churchill Livingstone2003; 483–554.
- 5.Muehrcke DD, Cosgrove DM. Cohn LH, Edmunds Jr LH, eds. *Cardiac Surgery in the Adult.* 2nd ed. New York, NY: McGraw-Hill;2003: 991–1025.
6. Carpentier A. Cardiac valve surgery--the "French correction". *J Thorac Cardiovasc Surg.* 1983 ;86:323-37.
7. Ross JK. Assessment of mitral valve function at operation and the prevention of systemic embolism. *Thorax.* 1971;26:306-8.

SID



سرویس های ویژه



سرویس ترجمه تخصصی



کارگاه های آموزشی



بلاگ مرکز اطلاعات علمی



سامانه ویراستاری STES



فیلم های آموزشی

کارگاه های آموزشی مرکز اطلاعات علمی



مقاله نویسی علوم انسانی



اصول تنظیم قراردادها



آموزش مهارت های کاربردی در تدوین و چاپ مقاله