

Spontaneous Recanalization of a Stenotic Lesion before Stent Deployment

Hashemi Arash** MD, Maleki Majid MD FACC , Madani Mohsen MD

Abstract

Spontaneous recanalization of a stenotic atherosclerotic lesion is a rare finding. We report a 66-year-old man with severe discrete stenosis at the distal part of the left anterior descending candidate for percutaneous intervention. However, before stent deployment, the patient showed complete relief of the stenotic lesion (*Iranian Heart Journal 2011; 12 (2):52-54*).

Keywords : Spontaneous recanalization ■ Percutaneous intervention

Case report

We report a 66-year-old man with exacerbation of typical chest pain of two months' duration. He had typical angina and dyspnea on exertion, which escalated from NYHA function class 1 to 3 within the two-month period prior to his admission.

His physical exam was unremarkable except for S 4 best heard at the apical region, and the laboratory data showed no abnormality.

He had a history of previous inferior wall myocardial infarction twenty years before, for which he had undergone coronary angiography. The diagnosis then was normal left system with normal ejection fraction and a totally cut-off RCA with poor run-off; he was, therefore, candidate for medical follow-up. The patient's cardiac risk factors were a history of past myocardial infarction, cigarette smoking, and a positive family history. Due to his new symptoms, he underwent myocardial perfusion scan, which showed moderate to severe reversible ischemia in the anterior and antero-lateral wall of the left ventricle. Echocardiography demonstrated mild left ventricular hypertrophy with grade 1 diastolic dysfunction, anterior wall and inferior wall mild hypokinesia, and mildly reduced ejection fraction of about 40 to 45 % in the left ventricle.

Received Apr. 17, 2011; Accepted for publication Jun. 9, 2011

Corresponding author : Majid Maleki MD FACC ,Professor in cardiology Shaheed Rajaie Cardiovascular, Medical and Research Center , Iran

*Interventional cardiologist , Assistant Professor of Cardiology , Shaheed Rajaie Cardiovascular Medical Center , Iran

** Resident of Cardiology , Shaheed Rajaie Cardiovascular, Medical and Research Center , Iran

candidate for coronary intervention on the LAD lesion.

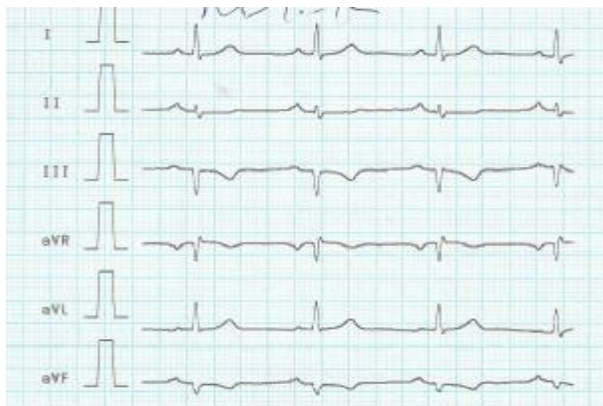After passing of the guide wire and TNG injection, decision was made to deploy a 2.5 - 8 mm stent. A suitable guidewire was negotiated through the lesion and the stent was seated at a proper position.

Nevertheless, before its deployment, interestingly, the stenosis was relieved. The stent was thereafter withdrawn, and a reinjection of the coronary artery surprisingly showed no stenosis.

The diagnosis was stenosis most probably due to previous soft atherosclerotic plaque or thrombosis and spasm.

Discussion

Likely explanations for this kind of stenosis include coronary artery spasm, pseudo-narrowing caused by mechanical deformation of a tortuous coronary artery, and a soft atherosclerotic plaque.



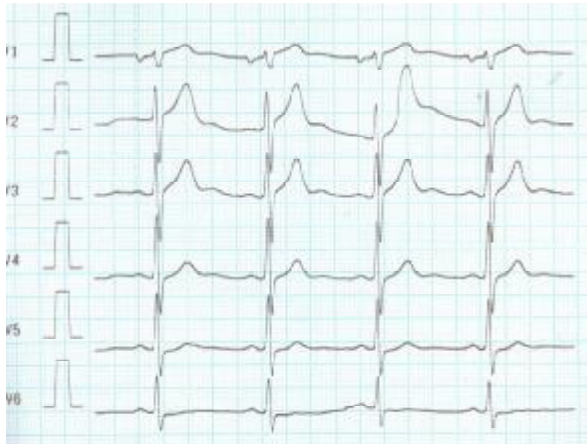

Fig.1. Base line ECG

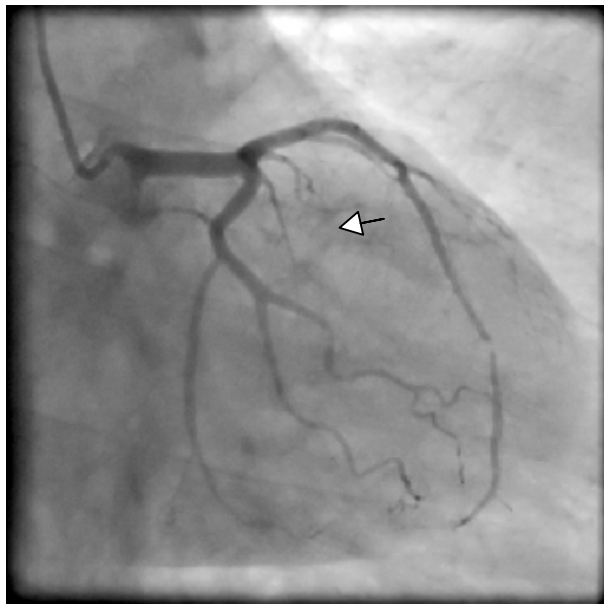


Fig.2. Coronary injection showing severe discrete stenosis in the LAD

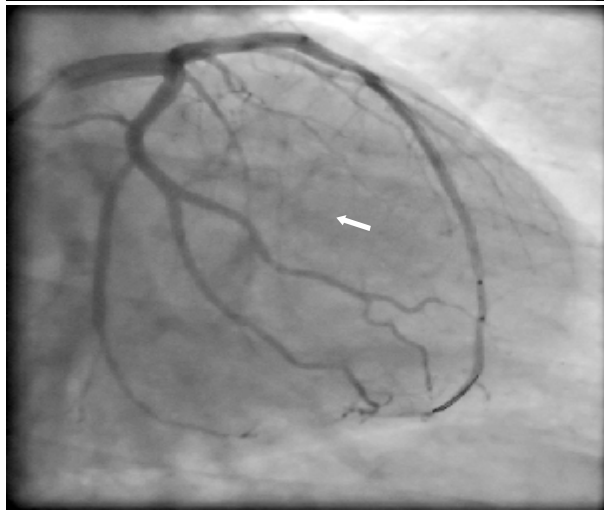


Fig. 3. Crossing the stent over the guidewire

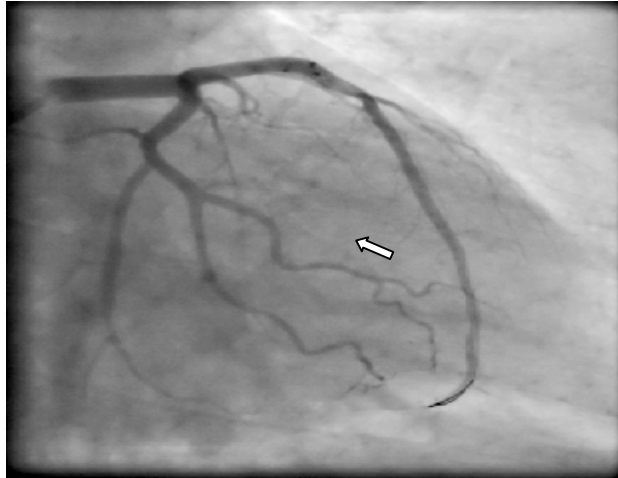


Fig. 4. Spontaneous relief of the stenosis before starting

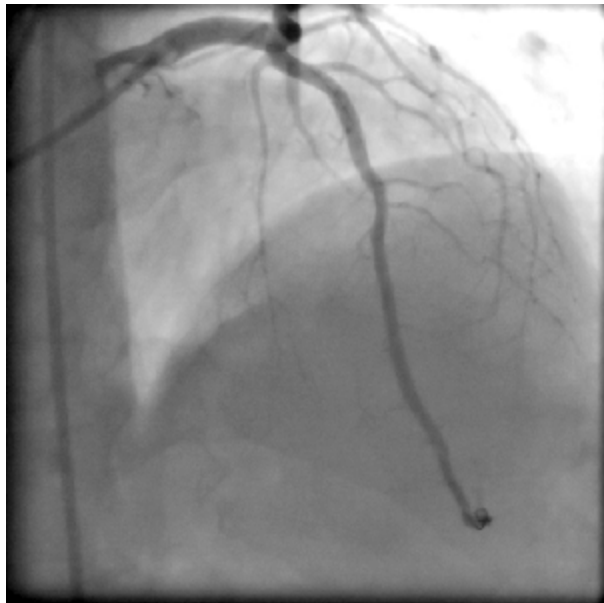

Fig. 5. Final injection after stent withdrawal showing no stenosis

Coronary artery spasm is a relatively common finding during percutaneous coronary intervention. This finding is usually relieved by an intracoronary administration of vasodilators like nitroglycerin. In case of pseudo lesions, there are features that can be used to differentiate them from true stenosis: the "web-like" eccentric appearance of the lesions, the presence of a tortuous coronary artery, and the changing angiographic appearance of the lesions after nitroglycerin or mechanical manipulation. Our case is unique in that the stenosis was found before passing the guidewire and persisted after nitroglycerin injection and was suddenly gone before the deployment of the stent.

References

1. Delayed spontaneous recanalization of a totally occluded right coronary artery following failed percutaneous coronary intervention with associated Type F dissection: case report and review. Stinis CT, Ahsan CH, Movahed MR.
2. Undefeatable coronary lesion. Farman MT, Sial JA, Khan NU, Masood T, Saghir T.
3. Spontaneous recanalization of chronic internal carotid artery occlusions: report of 3 cases. Buslovich S, Hines GL.

4. Vortex formation and recirculation zones in left anterior descending artery stenoses: computational fluid dynamics analysis .
5. D G Katritsis^{1,2,6}, A Theodorakakos³, I Pantos^{1,4}, A Andriotis³, E P Efstathopoulos⁴, G Siontis², N Karcianas⁵, S Redwood² and M Gavaises⁵.
6. [Spontaneous and heparin-induced recanalization of the completely occluded internal carotid artery--a neglected phenomenon? 2 case reports and review of the literature]. [Article in German] Schelp R, Bickel A, Kolominsky P, Schweiger H.
7. Cardiogenic Shock Caused by Severe Coronary Artery Spasm Immediately after Coronary Stenting Aaron Wong, MBBS, Alfred Cheng, MD, Charles Chan, MB, ChB, and Yean-Leng Lim, MBBS, PhD

Surf and download all data from SID.ir: www.SID.ir

Translate via STRS.ir: www.STRS.ir

Follow our scientific posts via our Blog: www.sid.ir/blog

Use our educational service (Courses, Workshops, Videos and etc.) via Workshop: www.sid.ir/workshop