

SID



سرویس های ویژه



سرویس ترجمه تخصصی



کارگاه های آموزشی



بلاگ مرکز اطلاعات علمی



عضویت در خبرنامه



فیلم های آموزشی

کارگاه های آموزشی مرکز اطلاعات علمی جهاد دانشگاهی



مباحث پیشرفته یادگیری عمیق؛
شبکه های توجه گرافی
(Graph Attention Networks)



کارگاه آنلاین آموزش استفاده از
وب آو ساینس



کارگاه آنلاین مقاله روزمره انگلیسی

Congenital Partial Absence of Trapezius with Variant Pattern of Rectus Sheath

Sarika Rachel Tigga¹, Preeti Goswami², and Jugesh Khanna³

¹ Department of Anatomy, Esic Medical College and Hospital, Rohtak University, Delhi, India

² Department of Anatomy, Azad Medical College, Delhi University, New Delhi, India

³ Department of Anatomy, University College of Medical Sciences, Delhi, India

Received: 06 Jun. 2014; Accepted: 24 Dec. 2014

Abstract- Musculocutaneous pedicled/ free flaps are an essential prerequisite for reconstructive surgery. Amongst the trunk muscles commonly harvested for flaps, the trapezius and rectus abdominis provide satisfactory coverage for cranial and trunk defects. unilateral/ bilateral or partial congenital absence of trapezius muscle is well documented and may result in muscular imbalances compromising posture and limb movements. During routine cadaveric dissection, we encountered a case of bilateral partial absence of occipital part of the trapezius muscle. Concurrently, the ventral abdominal musculature displayed the aponeurosis of transversus abdominis muscle solely forming the posterior wall of the rectus sheath. These conjointly occurring anomalies advocate a compensatory strengthening of the anterior wall of rectus sheath in response to the congenital absence of occipital part of the trapezius, probably to counteract the postural instability. The present study focuses on recognition of compensatory mechanisms resulting from congenital variations as identification of such processes may prevent chronic debilitating conditions.

© 2016 Tehran University of Medical Sciences. All rights reserved.

Acta Med Iran, 2016;54(4):280-282.

Keywords: Congenital variations; Rectus sheath; Trapezius; Transversus abdominis

Introduction

The trapezius is an extrinsic immigrant muscle in the dorsal cervical region and upper back, connecting the upper limb with the vertebral column. The muscle is divisible into three parts: superior, middle and inferior. The fibres have a linear origin from the occipital bone, ligamentum nuchae, spinous process of seventh cervical to twelve thoracic vertebrae. The muscle inserts into the posterior border of the lateral third of the clavicle, medial margin of the acromion, superior lip of the crest of the scapular spine and inferior fibres onto a tubercle at the apex of the spine of the scapula. The trapezius with other adjunct muscles produces scapular movements and maintains posture (1). On the ventral abdominal wall, three aponeurotic laminae of decussating fibres originating from the external oblique (EO), internal oblique (IO) and transverses abdominis (TA), form the rectus sheath (RS) enclosing the rectus abdominis (RA) muscle. The EO aponeurosis with an anterior lamina of IO forms the anterior wall while the TA with the posterior lamina of IO forms the posterior wall of the sheath above the umbilicus. The posterior

sheath is absent below the umbilicus as all laminae join to form the anterior sheath (2). Abdominal muscles with their aponeuroses produce trunk movements and cause compression of the abdomen (3). We report a case of bilateral partial absence of trapezius muscle presumably resulting in the modification of the rectus sheath. The inability to recognize postural defects resulting from morphological variations impede rehabilitative measures.

Case Report

During routine, region-wise dissection conducted for undergraduate medical students, variations of the trapezius muscle and rectus sheath were observed in an embalmed 55-year-old male cadaver. The cervical part of trapezius in its upper half was bilaterally replaced by a thin fibrous lamina up to the fourth cervical vertebra, thereafter, muscle fascicles originating from the ligamentum nuchae were found embedded in this fascia. The origin of middle and inferior fibers was aponeurotic. The muscle had a normal mode of insertion (Figure 1) and was supplied by the spinal accessory nerve. External

Corresponding Author: S. Rachel Tigga

Department of Anatomy, University College of Medical Sciences, Dilshad Garden, Delhi, India
Tel: +91 11 23237962, Fax: +91 11 23234416, E-mail address: sarika.rachel@gmail.com

examination of the dorsal cervical contour did not reveal the underlying variation, as the levator scapulae, semispinalis and splenius capitis muscles were sufficiently enlarged to compensate for the partial absence of trapezius muscle. Concurrently, on dissection of the anterior abdominal musculature, a variant pattern of rectus sheath formation was also encountered. In the upper five-sixths, aponeurosis of the EO and IO muscles formed the anterior wall, while the TA formed its posterior wall with an intervening thin sheet of fascia separating the RA and TA. In the lower one-sixth, a slip of TA aponeurosis merged with fibers of the EO and IO to form the anterior wall of the sheath while the posterior wall was formed by the fascia transversalis (Figure 2). The arcuate line formed at this level provided a passageway for the inferior epigastric artery to enter the RA.

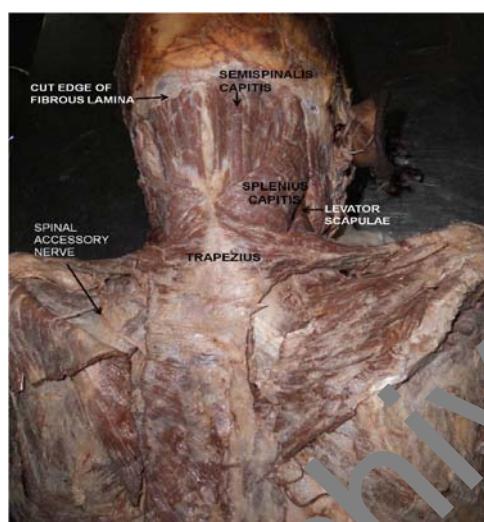


Figure 1. Dorsal view of the cervical and back region. The extent of the trapezius muscle and spinal accessory nerve, applying it is seen.

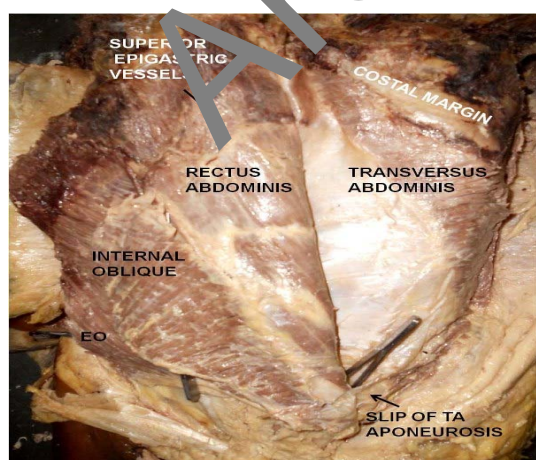


Figure 2. Ventral view of the abdominal wall. The posterior wall of rectus sheath formed by transversus abdominis (TA). A slip of TA

aponeurosis in the lower 1/6th is seen contributing to the anterior wall of the rectus sheath. EO: external oblique muscle.

Discussion

The hypobranchial muscle group of the posterior cranial and shoulder girdle area has a mixed somatic and branchial origin (4). In the occipital region, a single premuscle mass divides to form the sternocleidomastoid (SCM) ventrally and the trapezius muscle dorsally (5). These constitute the truncofugal muscles that migrate from the head (the trapezius and SCM muscles) and trunk (the rhomboids, levator scapulae muscles) to the shoulder girdle and are associated with movements and stabilization of the shoulder girdle (6). Developmental alterations in the migration of this muscle mass may cause variable morphology and explain the receding vertebral attachment of trapezius up to fifth cervical spine or descent up to the second lumbar spine. As seen in the present case, the occipital attachment of the trapezius reached only up to the fourth cervical spine. Various studies have emphasized the diverse variations of the trapezius muscle ranging from bilateral to complete unilateral absence of the muscle (1,7). Reportedly, the clavicular attachment may blend with SCM muscle; detach to form entities like Omocervicalis and dorsofascialis (8) or portions of the muscle may be deficient with separate cervical and thoracic parts (9). Thus, disproportionate development of the trapezius may compromise posture and shoulder girdle movements. Based on its vascular pedicle (descending branch of the transverse cervical artery), the trapezius enables a flexible arc of flap rotation, and such well-vascularized musculocutaneous flap designs provide adequate coverage with preserved muscle function during surgical restitution of trunk and cervical wounds (10). On the ventral aspect of the trunk, we found a variant rectus sheath formation wherein the posterior wall of the sheath was formed solely by the TA aponeurosis. Similarly, Monkhouse W. S. & Khaliq A. (1986) found in 27.5% cases, the aponeurosis of TA remained posterior while the IO aponeurosis passed anterior to the RA muscle (11). The rectus muscle is also employed in obtaining flaps for reconstructive breast surgery (2). Electromyographic studies reveal that rapid upper limb movements cause brief postural instability of the trunk that cause increased activity in the lower fascicles of TA and IO (12). The compressive forces thus generated flex the spine for stabilization of the sacroiliac joints (13). Further, an anterior position of these abdominal aponeuroses is considered favourable,

Morphological variations of trapezius and rectus sheath

as the fibres can act on a rigid support provided by the contracted RA (14). In the present case, postural imbalance produced by the bilateral partial absence of trapezius may have led to the favorable anterior disposition of the IO aponeuroses, as decussation of collagen fibers in the rectus sheath are reportedly established by mechanical demands after birth (15). In a case like ours, musculocutaneous flaps harvested from either the trapezius or rectus muscle may aggravate postural instability.

These conjointly occurring anomalies suggest congenital variations may create developmental aberrations at an entirely different site as a compensatory mechanism for maintenance of posture. Routine functional assessment of muscles employed as grafts must be performed to detect variant anatomy, as musculocutaneous flaps if harvested from such muscles may produce postural instability and/or deformities.

References

1. Johnson D, Collins P. Pectoral girdle, shoulder region and axilla. In: Standring S, editor. *Gray's Anatomy*. 40th ed. Edinburgh: Elsevier/Churchil Livingstone; 2005: p. 809.
2. Sinnatamby C, editor. *Last's anatomy*. 11th ed. Edinburg: Churchill Livingstone; 2000: p. 232-4.
3. Rizk NN. A new description of the anterior abdominal wall in man and mammals. *J Anat* 1980;131(Pt 3):373-85.
4. Limbs. In: Sadler TW, editor. *Langman's medical embryology*. 11th ed. New Delhi: Wolters Kluwer Health Pvt. Ltd; 2010: p. 150-1.
5. Sambasivan R, Kuratani S, Tajbakhsh S. An overview on the head: the development and evolution of craniofacial muscles. *Development* 2011;138(12):2401-15.
6. McKenzie J. The morphology of the sternomastoid and trapezius muscles. *J Anat* 1955;89(4):526-31.
7. Allouh M, Mohamed A, Mhanni A. Complete unilateral absence of trapezius muscle. *Mcgill J Med* 2004;8(1):31-3.
8. Joshi SS, Joshi SD. Muscle Dorso-Fascialis - A Case Report. *J Anat Soc India* 2001;50(2):159-60.
9. Garbelotti Jr SA, Rodrigues CFS, Sgrott EA, et al. Unilateral absence of the thoracic part of the trapezius muscle. *Surg Radiol Anat* 2001;23(2):131-3.
10. Mathes SJ, Stevenson TR. Reconstruction of posterior neck and skull with vertical trapezius musculocutaneous flap. *Am J Surg* 1988;156(4):248-51.
11. Monkhouse WS, Khoury A. Variations in the composition of the human rectus sheath: a study of the anterior abdominal wall. *J Anat* 1987;145(1):61-6.
12. Hodges P W, Passwell A, Thorstensson A. Preparatory trunk motion accompanies rapid upper limb movements. *Exp Brain Res* 1999;125(1):69-79.
13. Richardson CA, Steders CJ, Hides JA, et al. The relationship between the transversus abdominis muscles, sacroiliac joint mechanics, and low back pain. *Spine* 2002;27(4):399-405.
14. Mwachuka P, Odula P, Awori K, et al. Variations in the Pattern of Formation of the Abdominis Rectus Muscle Sheath among Kenyans. *Int J Morphol* 2009;27(4):1025-9.
15. Yang JD, Hwang HP, Kim JH, et al. Development of the Rectus Abdominis and Its Sheath in the Human Fetus. *Yonsei Med J* 2012;53(5):1028-35.

SID



سرویس های ویژه



سرویس ترجمه تخصصی



کارگاه های آموزشی



بلاگ مرکز اطلاعات علمی



عضویت در خبرنامه



فیلم های آموزشی

کارگاه های آموزشی مرکز اطلاعات علمی جهاد دانشگاهی



مباحث پیشرفته یادگیری عمیق؛
شبکه های توجه گرافی
(Graph Attention Networks)



کارگاه آنلاین آموزش استفاده از
وب آوساینس



کارگاه آنلاین مقاله روزمره انگلیسی