

A Woman with Normotensive Primary Hyperaldosteronism

Sedighe Moradi¹, Mohammadreza Shafiepour², and Alireza Amirbaigloo¹

¹ Institute of Endocrinology and Metabolism, Iran University of Medical Sciences, Tehran, Iran

² Rafsanjan University of Medical Sciences, Rafsanjan, Iran

Received: 29 May 2014; Accepted: 24 Nov. 2014

Abstract- Normotensive hyperaldosteronism is a rare disorder. It is usually diagnosed with hypokalemia or an adrenal mass. Our patient was a 27-year-old female presented with weakness. She had normal blood pressure, hypokalemia, high plasma aldosterone level and suppressed plasma renin activity. After the saline load, test aldosterone didn't show suppression. Adrenal computed tomography revealed a left adrenal mass. The patient was treated with spironolactone and potassium supplement. Surgical adrenalectomy was done. Final pathologic diagnosis was benign adrenocortical adenoma without capsular invasion. In postoperative course serum, potassium was normal.

© 2015 Tehran University of Medical Sciences. All rights reserved.

Acta Med Iran, 2016;54(2):156-158.

Keywords: Primary Hyperaldosteronism; Normotensive; Hypokalemia

Introduction

Primary hyperaldosteronism (PA) is the most common cause of secondary hypertension (1-3). The common form of primary aldosteronism is characterized by hypertension and hypokalemia. Although many cases with PA do not have hypokalemia (>50%), but normotensive patients are rare (1,4). It was first described by Brooks *et al.*, in 1972 and reported patients are still rare (5).

Unusual cases of normotensive PA are known by hypokalemia or by an incidentally discovered adrenal mass (6). The mechanisms underlying normal blood pressure are unknown.

Case Report

A 27-year-old female was admitted to our clinic

because of muscle weakness since six months ago. She was examined by the local physician who diagnosed hypokalemia and admitted her to the hospital, then started KCL infusion. Familial history for hypertension was negative.

At admission to our hospital, the body mass index was 22.8 kg/m². Blood pressure values measured with a manual armlet were always below 110/80mmhg. Heart rate was 72 beats per minute and regular. Thyroid gland examination was normal. There was neither obesity nor hirsutism; neurological examination was normal. Other physical examinations were normal too.

Renal function, urinary free cortisol, metanephrine, and normetanephrine were normal.

As shown in Table 1, blood aldosterone levels were increased, and the plasma renin activity (PRA) was suppressed.

Table1. Blood and urine aldosterone, and the PRA, and Potassium levels

Variable	Adult Reference Range	Patients
3 months before admission		
Serum Potassium (meq/li)	--	2.4
Aldosterone (pg/ml)	34-273	1131
Plasma Renin activity (ng/ml/hr)	4.4-41	<0.5
On admission		
Aldosterone (pg/ml)	8-172	1377
Plasma Renin Activity (ng/ml/hr)	0.5-1.9	<0.2

Corresponding Author: S. Moradi

Institute of Endocrinology and Metabolism, Firouzgar Hospital, Tehran, Iran

Tel: +98 21 88945434, Fax: +98 21 88945173, E-mail address: moradi.s@iums.ac.ir

After infusion of 2 liter 0.9% saline solution in 4h plasma, aldosterone was very high. Plain computed tomography image of the abdomen showed a mass measuring 3.2.2 cm in the body, and inner arm left adrenal gland (Arrow, Figure 1).

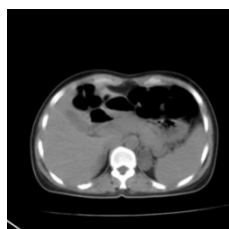

Figure 1. CT scan of the adrenal gland, Arrow shows left adrenal mass.

The patient then received 100 mg/day spironolactone and KCL infusion for 2 weeks before surgery, which normalized the serum potassium.

The adrenal gland was surgically removed (Figure 2), and the postoperative course was well.

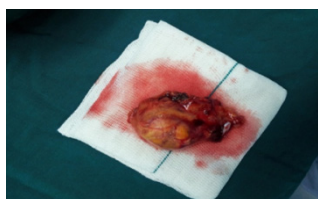


Figure 2. Macroscopic view of adrenal gland removed by surgery

The macroscopic tumor consisted of one ovaloid piece of orange rubbery tissue with weight: 22gr, circumscribed mass: 2.8cm in diameter adjacent to adrenal tissue.

In microscopic examination, it is reported as follow: Section of neoplastic tissue with the trabecular pattern was composed of cells with round nuclei, conspicuous nucleoli, and clear cytoplasm. Areas with nuclear atypia were seen. Necrosis, capsular invasion, and atypical mitosis were not present. Final pathologic diagnosis was benign adrenocortical adenoma without capsular invasion (Figure 3).

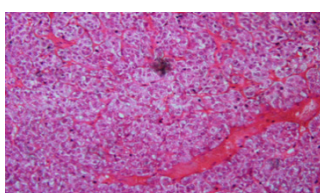


Figure 3. Microscopic view of adrenal mass

The patient had a normal serum potassium level without any medication or supplement. The mean level of blood pressure did not have any significant change compared to preoperative levels. She was good and had normal serum potassium four months after surgery.

Discussion

We described a patient with primary hyperaldosteronism presented with muscle weakness and normal blood pressure. Despite the absence of hypertension, hyperaldosteronism was confirmed by hypokalemia, suppressed PRA and increased plasma aldosterone levels. The patient had an adrenal mass on CT with a morphologically normal contralateral gland; histologic examination showed a typical adenoma with clear cells and normalization of hypokalemia after surgery.

To best our knowledge 26 cases have been reported of which 55% were Asian, (Eurasians) especially Japanese and 67% were female. They were aged between 23 and 55 years. No familial cases were reported. Neuromuscular signs and symptoms (i.e. paresthesia, muscular weakness, and paralysis) were the main clinical characteristics.

In another report about 10 normotensive PA one-third of the hypertensive PA, patients had hypokalemia (5). This is consistent with the 10–40% prevalence observed in a large multicentre series of hypertensive PA (7).

Different mechanisms leading to maintained normal blood pressure levels in primary aldosteronism have been described. Early diagnosis of hyperaldosteronism before the development of hypertension may be the cause in some patients. Salt restriction is mentioned as another cause (6). The negative findings in the salt loading test overrule the possibility that a low salt intake may have prevented the development of hypertension in our patient indeed; patients with normotensive primary aldosteronism may have a lower level of vasoconstrictor system or higher level of vasodilator system. High level of vasodilator system may result from increased secretion of vasodilator substances, such as prostaglandin E, kallikreins, and nitric oxide, or increased sensitivity to these substances (6).

Another explanation could be that individuals with low normal ranges of blood pressure have wider intervals to reach defined values of hypertension. Thus, in hypertensive circumstances, like primary

Normotensive primary hyperaldosteronism

aldosteronism, they may have increased blood pressure by more than 30 mmHg but be still in normal ranges and are considered normotensive (1). This is reported at least in one case with normotensive primary hyperaldosteronism, but our patient didn't show a significant decrease in blood pressure after surgery.

Lack of hypertension in hypokalemic patients should not exclude primary aldosteronism.

References

1. Kanoun F, Mabrouki T, Mekaouer A, et al. Normotensive Primary Aldosteronism: A Case Report. *Int J Endocrinol* 2009;5(1).
2. Satoh F, Morimoto R, Iwakura Y, et al. Primary aldosteronism. *Rev Endocr Metab Disord* 2011;12(1):11-4.
3. Calhoun DA. Aldosteronism and hypertension. *Clin J Amn Soc Nephrol* 2006;1(5):1039-45.
4. Williams JS, Williams GH, Raji A, et al. Prevalence of primary hyperaldosteronism in mild to moderate hypertension without hypokalaemia. *J Hum Hypertens* 2006;20(2):129-36.
5. Medeau V, Moreau F, Trinquart L, et al. Clinical and biochemical characteristics of normotensive patients with primary aldosteronism: a comparison with hypertensive cases. *Clin Endocrinol (Oxf)* 2008;69(1):20-8.
6. Paolo Rossi G. Does primary aldosteronism exist in normotensive and mildly hypertensive patients, and should we look for it? *Hypertens Res* 2011;34(1):43-6.
7. Mulatero P, Stowasser M, Loh KC, et al. Increased diagnosis of primary aldosteronism, including surgically correctable forms, in centers from five continents. *J Clin Endocrinol Metab* 2004;89(3):1045-50.

Archive of SID

Surf and download all data from SID.ir: www.SID.ir

Translate via STRS.ir: www.STRS.ir

Follow our scientific posts via our Blog: www.sid.ir/blog

Use our educational service (Courses, Workshops, Videos and etc.) via Workshop: www.sid.ir/workshop