

Guyon's Tunnel Syndrome during Pregnancy with Concomitant Anomalous Arch of the Ulnar Nerve: a Case Report

Nasser Janmohammadi

Department of Orthopedics, Mobility Impairment Research Center, Babol Medical Sciences Center, Babol, Iran

Received: 11 Dec. 2012; Accepted: 10 Jun. 2013

Abstract- Numerous causes are reported for ulnar nerve compression at the wrist, known as Guyon's tunnel syndrome. In the present article, a patient with Guyon's tunnel syndrome during pregnancy concomitant with an anomaly of ulnar nerve is described. A 29-year-old Iranian woman presented with clinical features of Guyon's tunnel syndrome (pain and paresthesia in the fifth finger of the left hand and atrophy of the first dorsal interosseus muscle). Symptoms of the patient appeared during the third trimester of pregnancy. Electro diagnostic studies confirmed Guyon's tunnel syndrome. Surgical exploration revealed an anomalous arch of the ulnar nerve passing through the flexor carpi ulnaris (FCU) tendon. The anomalous arch of the ulnar nerve was released by resection of the segment of FCU tendon passing through the ulnar nerve arch. Therefore, in patients with Guyon's tunnel syndrome, the ulnar nerve anomaly should be kept in mind as a cause. Moreover, pregnancy may have a provocative effect on Guyon's tunnel syndrome similar to carpal tunnel syndrome (CTS).

© 2014 Tehran University of Medical Sciences. All rights reserved.

Acta Medica Iranica, 2014;52(7):562-564.

Keywords: Guyon's Tunnel Syndrome; Ulnar Nerve; Anomaly; Wrist; Pregnancy

Introduction

Numerous causes of Guyon's tunnel syndrome have been reported, including anatomic variations (1), ganglions (2), occupational trauma (3), non-occupational trauma (4,5), muscular anomalies (6), vascular problems (7,8), rheumatoid arthritis (9), tumor (10), flexor carpi ulnaris tendon anomalies (11,12), and ulnar nerve anomalies (13,14). A patient with Guyon's tunnel syndrome during pregnancy because of a rare anomaly of ulnar nerve is described.

Case Report

A 29-year-old Iranian woman presented with pain and paresthesia in her fifth finger of the left hand and atrophy of the first dorsal interosseus muscle (Figure 1). The patient's symptoms appeared in the third trimester of pregnancy that was terminated four months ago. Patient had no history of trauma or other pre-disposing conditions. The patient also had no problem in her involved hand before getting pregnant.

Plain radiographic evaluation of the wrist and routine

laboratory investigations were normal.

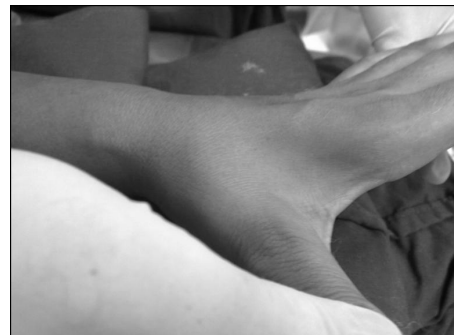

Figure 1. Wasting of first dorsal interosseus muscle

Diagnosis of ulnar nerve compression at the wrist - Guyon's tunnel syndrome - was made, regarding clinical presentation and electrodiagnostic studies. Surgical exploration of the ulnar nerve at the wrist was undertaken. Under general anesthesia, an incision was made on the antero-medial aspect of the left wrist and the ulnar nerve was explored cautiously. Approximately, six cm proximal to the pisiform bone; the ulnar nerve was divided into two branches. One branch comprising about three fourths of

Corresponding Author: N. Janmohammadi

Department of Orthopedics, Mobility Impairment Research Center, Babol Medical Sciences Center, Babol, Iran
Tel: +98 111 3239565, Fax: +98 111 2266192, E-mail address: Janmohammadi.nasser@gmail.com

the nerve's cross-sectional diameter continued along the expected course, the other branch formed an arch and passed through the flexor carpi ulnas tendon (FCU) (Figure 2). The two divisions rejoined at a point approximately two cm proximal to the pisiform bone. Distally, the ulnar nerve was normal, and there was no nerve compression.

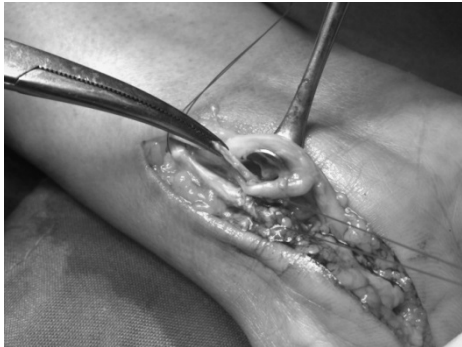


Figure 2. The segment of FCU after detection, and ulnar nerve arch

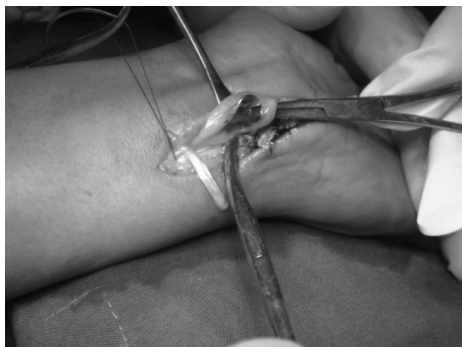

Figure 3. The segment of FCU tendon after cutting its distal end and ulnar nerve arch

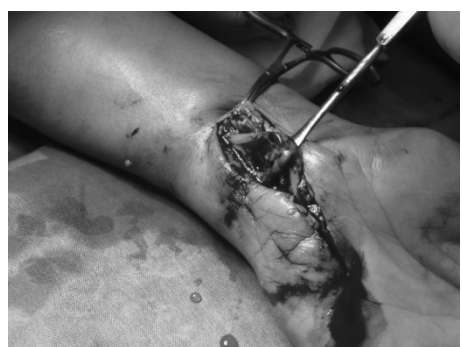

Figure 4. The ulnar nerve arch, after resection of the segment of FCU tendon

The entrapped anomalous arch of ulnar nerve in the FCU tendon was released by meticulous dissection and resection of a segment of the FCU tendon passing through the ulnar nerve arch (Figures 3, 4).

Discussion

Current report describes an individual with Guyon's tunnel syndrome during pregnancy and concomitant ulnar nerve anomaly. Guyon's tunnel syndrome because of ulnar nerve anomaly was reported previously (13,14). The current case is similar to report ones, but its association with pregnancy makes it different.

Women experience carpal tunnel syndrome (CTS) during pregnancy because of hormonal changes (high progesterone levels) and fluid retention in tissues which swell the tenosynovium (15,16). CTS is a common complication of pregnancy, with high reported prevalence (62%) (17,18). CTS occur most frequently in the third trimester of pregnancy (19,20).

Ulnar nerve neuropathy is reported concomitant with pregnancy; this may aggravate a predisposing condition (20). The present case with the ulnar nerve anomaly was asymptomatic before pregnancy. Pregnancy might have a provocative effect on the ulnar nerve anomaly to manifest as Guyon's tunnel syndrome. The pathogenesis of Guyon's tunnel syndrome during pregnancy may be similar to CTS in pregnancy.

In conclusion, ulnar nerve anomaly should be kept in mind as an etiology in patients with Guyon's tunnel syndrome. Moreover, pregnancy may have a provocative effect on Guyon's tunnel syndrome. Because of the phenomenon that causes CTS during pregnancy.

Acknowledgment

The author thanks Samaneh Asgari and Shahid Beheshti Hospital Clinical Research Development Center, for her utmost help in the completion of the manuscript.

References

1. Georgiev GP, Jeleu L, Surchev L. Undescribed variant muscle--"deep abductor-flexor" of the little finger, in relation to ulnar nerve compression at the wrist. *Ann Anat* 2007;189(3):276-82.
2. Kwak KW, Kim MS, Chang CH, et al. Ulnar Nerve Compression in Guyon's Canal by Ganglion Cyst. *J Korean Neurosurg Soc* 2011;49(2):139-41.
3. Chan JC, Tiong WH, Hennessy MJ, et al. A Guyon's canal ganglion presenting as occupational overuse syndrome: A case report. *J Brachial Plex Peripher Nerve Int* 2008;3(1):4.
4. Vance RM, Gelberman RH. Acute ulnar neuropathy with fractures at the wrist. *J Bone Joint Surg Am*

- 1978;60(7):962-5.
5. Gore DR. Carpometacarpal dislocation producing compression of the deep branch of ulnar nerve. *J Bone Joint Surg Am* 1971;53(7):1387-90.
 6. Lal RA, Raj S. Guyons canal syndrome due to accessory palmaris longus muscle: aetiological classification: a case report. *Cases J* 2009;2(1):9146.
 7. Kim SS, Kim JH, Kang HI, et al. Ulnar nerve compression at Guyon's canal by an arteriovenous malformation. *J Korean Neurosurg Soc* 2009;45(1):57-9.
 8. Ozdemir O, Calisaneller T, Altinors N. Compression of the ulnar nerve in Guyon's canal by an arteriovenous malformation. *J Hand Surg Eur* 2007;32:600-1.
 9. Taylor AR. Ulnar nerve compression at the wrist in rheumatoid arthritis. Report of a case. *J Bone Joint Surg Br* 1974;56(1):142-3.
 10. Sakai K, Tsutsui T, Aoi M, et al. Ulnar neuropathy caused by a lipoma in Guyon's canal--case report. *Neurol Med Chir (Tokyo)* 2000;40(6):335-8.
 11. O'Hara JJ, Stone JH. Ulnar neuropathy at the wrist associated with aberrant flexor carpi ulnaris insertion. *J Hand Surg Am* 1988;13(3):370-2.
 12. Harrelson JM, Newman M. Hypertrophy of the flexor carpi ulnaris as a cause of ulnar-nerve compression in the distal part of the forearm. Case report. *J Bone Joint Surg Am* 1975;57(4):554-5.
 13. Zook EG, Kucan JO, Guy RJ. Palmar wrist pain caused by ulnar nerve entrapment in the flexor carpi ulnaris tendon. *J Hand Surg Am* 1988;13(5):732-5.
 14. Kang HJ, Yoo JH, Kang ES. Ulnar nerve compression syndrome due to an anomalous arch of the ulnar nerve piercing the flexor carpi ulnaris: a case report. *J Hand Surg Am* 1996;21(2):277-8.
 15. Carpal tunnel syndrome. *Absolute Astronomy*. (Accessed in Jan 17, 2014, at [www.absoluteastronomy.com/topics/Carpal tunnel syndrome](http://www.absoluteastronomy.com/topics/Carpal%20tunnel%20syndrome))
 16. Ablove RH, Ablove TS. Prevalence of carpal tunnel syndrome in pregnant women. *WMJ* 2009;108(4):194-6.
 17. Jurjević A, Bralić M, Antončić I, et al. Early onset of carpal tunnel syndrome during pregnancy: case report. *Acta Clin Croat* 2010;49(1):77-80.
 18. Khosrawi S, Maghrouri R. The prevalence and severity of carpal tunnel syndrome during pregnancy. *Adv Biomed Res.* 2012;1(1):43.
 19. Rozali ZI, Noorman FM, De Cruz PK, et al. Impact of carpal tunnel syndrome on the expectant woman's life. *Asia Pac Fam Med* 2012;11(1):1.
 20. McLennan HG, Oats JN, Walstab JE. Survey of hand symptoms in pregnancy. *Med J Aust* 1987;147(11-12):542-4.

Surf and download all data from SID.ir: www.SID.ir

Translate via STRS.ir: www.STRS.ir

Follow our scientific posts via our Blog: www.sid.ir/blog

Use our educational service (Courses, Workshops, Videos and etc.) via Workshop: www.sid.ir/workshop