

# PHEOCHROMOCYTOMA ASSOCIATED WITH RENAL AGENESIS

A. Nickavar<sup>1\*</sup> and M. Razzaghy-Azar<sup>2</sup>

1) Department of Nephrology, School of Medicine, Iran University of Medical Sciences, Tehran, Iran

2) Department of Endocrinology, School of Medicine, Iran University of Medical Sciences, Tehran, Iran

**Abstract-** Pheochromocytomas are catecholamine producing tumor arising from chromaffin cells of adrenal medulla and extra adrenal tissues. Renal anomalies have been reported rarely in this disease. Here we report a rare case of pheochromocytoma associated with renal agenesis. Patient was a boy presented with headache and hypertension. In radiologic examinations, an adrenal mass was detected in the left side, with no renal tissue on that side. It was reported an adrenal pheochromocytoma in histopathology. Renal agenesis confirmed during surgery. All of the patient's symptoms alleviated after the resection of tumor. Considering association of renal abnormalities with pheochromocytoma, it is recommended to perform genetic analysis and kidney evaluation in cases with MEN type 2 or each of its components.

*Acta Medica Iranica* 2008; 46(1): 81-83.

© 2008 Tehran University of Medical Sciences. All rights reserved.

**Key words:** Pheochromocytoma, renal agenesis, hypertension

## INTRODUCTION

Unilateral renal agenesis is usually asymptomatic and detected incidentally. It is often associated with anomalies of contiguous (vertebrae, intestine, ...) or non contiguous (limbs, heart, ...) organs (1).

Pheochromocytomas are the most common endocrine tumors in childhood and the leading cause of pediatric hypertension in 1-2% (2). It may be associated with involvement of other organs in specific syndromes, especially MEN type 2. Renal anomalies have been reported rarely in this disease. This is a report of a rare case of pheochromocytoma associated with renal agenesis.

Received: 8 Nov. 2005, Revised: 28 Feb. 2006, Accepted: 20 May 2006

### \* Corresponding Author:

Azar Nikavar, Department of Nephrology, Ali Asghar Children Hospital, School of Medicine, Iran University of Medical Sciences, Tehran, Iran

Tel: +98 21 22226468,

Fax: +98 21 22200063

E-mail: anikavar@yahoo.com

## CASE REPORT

A 14 year old boy was admitted for headache and occasional night sweating. He had no complaint of nausea, vomiting and visual problems. Family history was negative for any significant disease. Physical examination was normal except for hypertension (BP= 160/90).

Laboratory examinations consisted of complete blood count (CBC), serum and urine biochemistry, serum renin and aldosterone level were all normal (Table 1). In abdominal ultrasound and DMSA radioisotope scan, right kidney was larger than normal and left kidney absent. Voiding cystourethrography was normal. Abdominal magnetic resonance imaging (MRI) and magnetic resonance angiography (MRA) of renal arteries showed compensatory hypertrophy of right kidney with multiple main renal arteries and no evidence of left kidney. An adrenal mass (possibly pheochromocytoma) detected in the left side. Therefore, urine VMA and NMN checked, which were both higher than normal (Table 1).

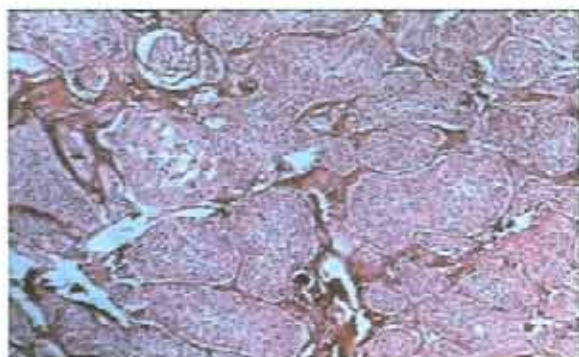
**Table 1.** Laboratory exams

Sodium	146 meq/l
Potassium	4.4 meq/l
Calcium	9.1 mg/dl
Phosph	5.4 mg/dl
Alk Phos	840 U/L
BUN	19 mg/dl
Crea	0.9 mg/dl
SGOT	40 U/L
SGPT	18 U/L
Renin	3 ng/ml/h (normal= $\leq$ 4/2 ng/ml/h)
Aldosterone	15 (normal= 2-22 ng/dl)
T3	150 (normal= 80-210 ng/dl)
T4	10 (normal= 4/2-13 microg/dl)
TSH	4 (normal=0/7-6/4 nmol/L)
PTH	30 (normal=9-65pg/ml)
VMA	18 (High)
NMN	4053 (High)

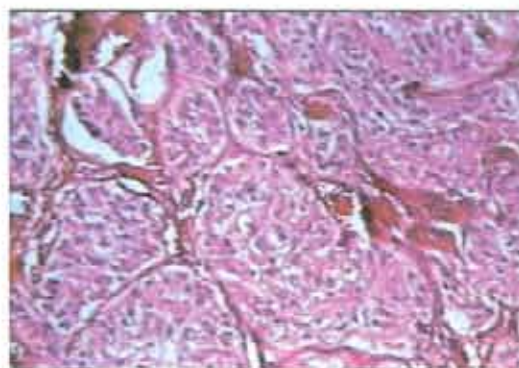
Abbreviations: VMA, vanillylmandelic acid; NMN, normetanephrin; DMSA, dimercapto succinic acid; MRA, magnetic resonance angiography; MIBG, monoio-dobenzylguanidine.

MIBG scan showed increased radiotracer uptake in both adrenals with a photopenic area in the enlarged left adrenal gland. The patient screened for MEN type 2 (parathyroid tumor, medullary carcinoma of the thyroid, and pheochromocytoma) (Table 1) and von Hippel Lindau disease which were all negative. He explored surgically for final diagnosis. No renal tissue detected in the left side, except a mass on that side, which was further reported to be an adrenal pheochromocytoma in histopathology (Fig. 1-3).

After tumoral resection, blood pressure became normal without any antihypertensive drug. During follow up, he had no recurrence of previous symptoms or any other disorders.



**Fig. 1.** Histopathology showing adrenal pheochromocytoma.



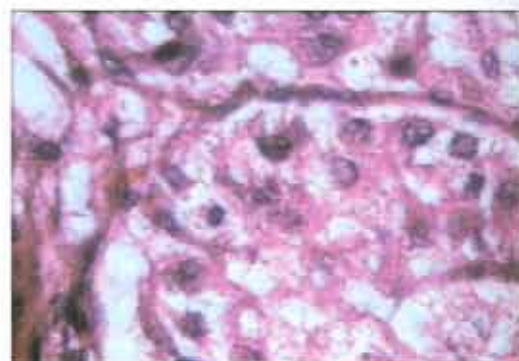
**Fig. 2.** Adrenal pheochromocytoma.

## DISCUSSION

Pheochromocytomas are adrenal and extra adrenal tumors which may present in the form of bilateral, multifocal, sporadic and familial as a component of MEN type 2, neurofibromatosis and Von hippel lindau disease (3, 4).

There are a few reports of renal abnormalities in patients with pheochromocytoma. It is a part of a rare autosomal dominant disease, von Hippel Lindau, which presents as renal cysts and carcinoma, retinal angioma, central nervous system hemangioblastoma and pancreatic involvement (5). Renal involvement is the most prevalent cause of its mortality (6).

Pheochromocytoma has been reported in some cases of bilateral polycystic kidney disease (7-9), one complicated by spontaneous rupture of tumor (8) and hemorrhage in the renal bed (9), and also in a patient with cystic dysplastic kidney on continuous dialysis. To our literature review, this is the first report of pheochromocytoma associated with renal agenesis.



**Fig. 3.** Histopathology showing adrenal pheochromocytoma with a greater magnification.

*Archive of SID*

Genetically, the significance of RET proto-oncogene gene (10) and its encoding protein related to tyrosin kinase family (11) has been documented in the induction of metanephric blastema and ureteric bud during kidney morphogenesis (10). Mutation of this gene is known to be responsible for developing MEN type 2A (2), renal agenesis or severe dysplasia (10). Lore et al have been suggested non invasive imaging techniques such as ultrasonography for screening renal abnormalities in patients with RET mutations (10).

According to common involvement of this gene in pathogenesis of these tumors and kidney morphogenesis, and the association of renal abnormalities with pheochromocytoma, it is recommended to perform genetic analysis and kidney evaluation in cases with MEN type 2 or each of its components.

**REFERENCES**

1. Limwongse C. Syndromes and malformations of the urinary tract. In: Avner ED, Harmon WE. Pediatric nephrology, 5th ed. Philadelphia: Lippincott, 2004; p. 93-125.
2. Pacak K, Eisenhofer G. Disorders of the adrenal medulla. In: Lifshitz fima. Pediatric endocrinology, Marcel Dekker, 2003; p. 194-9.
3. Ross JH. Pheochromocytoma. Special considerations in children. Urol Clin North Am. 2000 Aug; 27(3):393-402.
4. Chernausk SD Pheochromocytoma and the multiple endocrine neoplasia syndromes. In: Sperling. Pediatric endocrinology. Philadelphia; Saunders. 2002; P. 439-450.
5. Sessa A, Battini G, Meroni M, Pitingolo F, Righetti M, Ciotti P, Di Maria E, Bellone E, Ajmar F, Mandich P. Multifocal bilateral renal cell carcinoma and retinal angiomas in a patient with de novo von Hippel-Lindau disease: identification of a new germline mutation. J Nephrol. 2005 Mar-Apr; 18(2):209-212.
6. Chauveau D, Duvic C, Chrétien Y, Paraf F, Droz D, Melki P, Hélénon O, Richard S, Grünfeld JP. Renal involvement in von Hippel-Lindau disease. Kidney Int. 1996 Sep; 50(3):944-951.
7. Mansi L, Rambaldi PF, Marino G, Argenziano G, Sandomenico F, Del Vecchio E. Pheochromocytoma diagnosed with I-123 MIBG scintigraphy in a patient with concomitant bilateral polycystic kidneys. Clin Nucl Med. 1997 Apr; 22(4):268-270.
8. Quiñonero Díaz A, García Hirschfeld J, Alonso Dorrego JM, Marchal Escalona C, Machuca Santa Cruz J, Marín Martín JA. [Spontaneous rupture of pheochromocytoma in a patient with polycystic kidneys. Apropos of a case]. Arch Esp Urol. 1997 Dec; 50(10):1117-9. Spanish.
9. Delavierre P, Vayre P. [Association of a polycystic kidney and an adrenal adenoma, complicated by hemorrhage of the renal bed. Apropos of 2 cases]. Sem Hop. 1976 May 23; 52(20):1223-1224.
10. Lore F, Talidis F, Dicairano G, Renieri A. Multiple endocrine neoplasia type 2 syndromes may be associated with renal malformations. J Intern Med. 2001 Jul; 250 (1): 37-42.
11. Chappuis-Flament S, Pasini A, De Vita G, Ségouffin-Cariou C, Fusco A, Attié T, Lenoir GM, Santoro M, Billaud M. Dual effect on the RET receptor of MEN 2 mutations affecting specific extracytoplasmic cysteines. Oncogene. 1998 Dec 3;17(22):2851-2861.

Surf and download all data from SID.ir: [www.SID.ir](http://www.SID.ir)

Translate via STRS.ir: [www.STRS.ir](http://www.STRS.ir)

Follow our scientific posts via our Blog: [www.sid.ir/blog](http://www.sid.ir/blog)

Use our educational service (Courses, Workshops, Videos and etc.) via Workshop: [www.sid.ir/workshop](http://www.sid.ir/workshop)