

ALTERED PLASMA ZINC LEVEL CONTRIBUTES TO THE DEVELOPMENTAL TOXICITY OF VALPROIC ACID IN SKELETAL SYSTEM OF RAT

M.Akbari¹, F. Abolhassani^{*1}, M. Azizi¹, A.R. Dehpour², M.Ansari³, M.A. Ahmadi Faghih⁴ and A. Hedayatpour¹

- 1) Department of Anatomy, Medical School, Tehran University of Medical Sciences, Tehran, Iran
- 2) Department of Pharmacology, Medical School, Tehran University of Medical Sciences, Tehran, Iran
- 3) Department of Biochemistry, Medical School, Tehran University of Medical Sciences, Tehran, Iran
- 4) Iranian Atomic Energy Organization, Tehran, Iran

Abstract- Valproic acid is one of the main antiepileptic drugs. There is an increased risk of neural tube defects and axial skeletal malformations among infants born to women who had received valproic acid. There is a hypothesis that one biochemical abnormality underlying the teratogenicity of valproic acid is a drug-induced reduction in maternal plasma zinc. In the present experimental study mated rats were divided into four groups of 8 animals each [control, valproic acid (VPA), valproic acid + zinc (VPA+ Zn) and zinc (Zn) groups]. The VPA group received 300 mg/kg valproic acid, daily. The control group received an equal volume of 0.9% NaCl. The VPA+ Zn group received 300 mg/kg VPA and 30 mg/kg zinc sulfate and the Zn group received 30 mg/kg zinc sulfate, daily. Valproic acid, NaCl, and Zn were administered intraperitoneally from day 6 through day 15 of gestation. On day 16, six rats of each group were euthanized and the other rats were sacrificed on gestational day (GD) 20 to evaluate the skeletal system among the elder fetuses. Blood was drawn to determine plasma zinc. The data were analyzed by using analysis of variance (Kruskal -Wallis test). The zinc concentration in the plasma of rats treated with valproic acid was significantly lower than those of the other groups on 16 GD ($P=0.004$). Some anomalies such as hydrocephaly, spina bifida, hemivertebra, and rib malformations were seen in VPA treated group. Low percentage of rib anomalies and spina bifida were observed in the VPA+ Zn treated group while no skeletal anomalies were seen in Zn and control groups. The results from the present experiment support the hypothesis that one of the biochemical abnormalities causing the teratogenicity of VPA is a drug-induced maternal plasma zinc deficiency, and possibly, it may also result in reduction of embryonic Zn.

Acta Medica Iranica, 42(1): 10-15; 2004.

Key words: Teratogenicity, valproic acid, zinc, skeletal malformation, rat

INTRODUCTION

Epilepsy is a chronic neurological disorder characterized by recurrent seizures. It contains sudden and unprovoked attacks that usually associated with altered awareness and involuntary movements (1). Antiepileptic drugs are the mainstay of treatment for most patients with epilepsy. Valproic acid, one of the main antiepileptic drugs used today, has been used in both generalized and partial seizures (1,2). New

approved indications of valproic acid consist of the treatment of bipolar disorders, neuropathic pain, and migraine prophylaxis (1-5). Congenital malformations have been reported among infants born to women who had received antiepileptic drugs including valproate during pregnancy. There is an increased risk of neural tube defects such as spina bifida and anencephaly among infants exposed to valproate, and variety of syndromes such as craniofacial and digital abnormalities, cleft lip, cleft palate as well as axial skeletal malformations have been described (3,5-11). Keen et al. have demonstrated that the teratogenicity of a number of drugs can be linked partly to drug-induced alterations in maternal and fetal trace mineral status (12). Although some of the researchers believe that there is a relation between valproic acid teratogenicity and the decrease of plasma zinc level

Received: 2 February 2003, Revised: 19 August 2003, Accepted: 15 October 2003

*** Corresponding Author:**

F. Abolhassani, Department of Anatomy, Medical School, Tehran University of Medical Sciences, Tehran, Iran
Tel: +98 21 6112308
Fax: +98 21 6419072
E-mail: abolhasf@sina.tums.ac.ir

(12-14), the other researchers do not agree with them (15,16). Zinc (Zn) is an essential element in the nutrition of human beings, animals, and plants. Zinc is a constituent of over 200 metalloenzymes and other proteins involved in immune function, antioxidant protection, and membrane stabilization. Zinc is needed in all DNA and RNA synthesis and is required at every step of the cell cycle (3,8,17-21). Zn is essential for normal growth and development. In 1976, Jameson observed that low maternal serum zinc was associated with congenital malformations and fetal dysmaturity. Several groups reported that mothers of infants with congenital anomalies had lower plasma Zn concentrations than that among other mothers. Zinc deficiency has been implicated specifically in the development of two neural tube defects, anencephaly and spina bifida (20). Based on the aforementioned issues, we investigated the hypothesis that one biochemical abnormality underlying the teratogenicity of valproic acid is a drug-induced reduction in maternal plasma zinc level.

MATERIALS AND METHODS

Virgin female Sprague- Dawley rats (180-200gr) were purchased from Pasteur institute. The rats were housed in cages in a controlled atmosphere room (temperature 23 -25 °C, 12 h light: dark cycle). The rats were fed with the zinc adequate diet. Diet and water were available throughout the experiment. . All experiments on animals were performed in accordance with UK legal requirements. After 3 weeks of acclimation to the diet and the environment, rats were mated with males of the same strain over night, and successful mating was determined by the presence of vaginal plugs the next morning, which was designated as gestational day (GD) 0. The rats were divided into four groups of 8 animals each [control, valproic acid (VPA), valproic acid + zinc (VPA + Zn) and zinc (Zn) groups]. The valproic acid group received 300 mg/kg valproic acid, daily (Rouz Darou Co.). The zinc group received 30mg/kg zinc sulfate, daily (Merck Co.). The control group received an equal volume of 0.9% NaCl. The valproic acid + zinc group received 300mg/kg VPA and 30mg/kg zinc sulfate, daily (Merck Co.). Valproic acid, NaCl, and zinc sulfate were administered intraperitoneally. These injections were performed from day 6 through day 15 of gestation .On day 16, six rats of each group were authorized with ether, and the other rats were scarified on GD 20 to evaluate the skeletal system

among the elder fetuses. Blood was drawn by cardiac puncture using heparinized syringes. The uterus was removed, and the number of live, dead, and resorption fetuses were recorded. The live fetuses were weighed (by the rate of 0.01 gram, Sartorius balance), and crown-rump lengths were measured (by the rate of 0.1mm). According to toxicological studies, the usual practice is to evaluate half of the fetuses in each litter for microscopic and macroscopic alterations and the remaining for clearing and staining of skeletal system by the alizarin red-s; therefore, we performed this method for skeletal assessment.

Zinc analysis

Blood samples were centrifuged at 3000 g at 4 °C for 15 minutes and plasma was transferred into separate tubes. Plasma zinc was determined (by the rate of 0.04 ppm) by atomic absorption spectrophotometry (Spectra AA - 220, Varian) in Iranian Atomic Energy Organization.

Statistical analysis

Diversity of plasma zinc, fetus length, and fetus weight between groups at three time-intervals were evaluated by using analysis of variance. Kruskal-Wallis test used for non-parametric analysis of difference between all of groups. Statistical significance was taken for $p < 0.05$.

Evisceration of fetuses

The evisceration of fetuses was performed to aid in clearing and staining of the skeleton. Small scissors were used to make a longitudinal cut in fetuses. This cut was extended from below the umbilicus through the midline of trunk along one side of the sternum, and severing costal cartilage, but not ribs and avoiding the clavicle. Evisceration was performed by inserting the forceps into the thoracic cavity and removing thoracic viscera, then abdominal and pelvise viscera were removed.

Staining of fetal skeletons

Staining of fetal skeletons was a modification of the method of Staples and Schnell (22). After the alcohol fixation period (7 days), the fetuses were placed into individual dishes and any remaining alcohol was drained away. Dishes were filled with 1% KOH solution, and fetuses were macerated for approximately 24 h. The KOH solution was then drained and replaced with 1% KOH solution containing the alizarin red-s stain, and fetuses were maintained in the stain for approximately 24 h, after

Plasma Zn and toxicity of valproic acid

that this solution was drained and replaced with a fresh 1% KOH solution in which the specimens were retained for another 24 h. The KOH solution was again drained, and the fetuses were cleared with progressively higher concentrations of glycerin (20%, 40%, 60%, and 80%). After completion of this process, the fetuses were stored in 99.5% glycerin and a few crystals of thymol.

RESULTS

The mean of plasma zinc level \pm S.E.M among VPA, control, VPA+ Zn and Zn groups was 2.28 ± 0.63 , 4.43 ± 1.10 , 8.57 ± 1.15 , 12.49 ± 2.88 ppm, respectively (Table 1), where the difference between groups was significant ($P=0.004$). The latter findings showed that the plasma zinc concentration of rats treated with valproic acid were significantly lower than those of the control rats and the VPA+ Zn treated rats on 16 GD ($P<0.005$). The diversity of plasma zinc between VPA and VPA + Zn group was statistically significant ($P=0.006$). There was a significant difference of the 16-day-fetus weight between groups; however, this difference was mainly due to the high fetus weight of the Zn group in comparison with relatively equal mean weight of the three other groups ($P= 0.000$).

Table 1. Plasma zinc of studied groups

Groups	Plasma Zn(ppm)				
	Mean	SD	SE	Min.	Max.
VPA (n=6)	2.28	1.55	.63	.96	4.73
Control (n=6)	4.43	2.70	1.10	1.15	8.86
Zn (n=6)	12.49	5.76	2.88	7.15	19.65
Zn + VPA(n=6)	8.57	2.57	1.15	5.15	12.26

Abbreviations:SD,Standard deviation;SE ,Standard Error;VPA , Valproic Acid.

Compared to control and Zn groups, VPA+ Zn and VPA treated groups had low fetal weight and crown-rump length on 16 GD (Table 2). The difference of fetal length between Zn and control groups was not statistically significant ($P=0.186$). VPA and Zn groups showed 3.57% and 1.58% of dead fetuses, respectively. Control group had low percentage of resorption compared to the VPA exposed group while there was not any dead fetus. No dead or absorption fetus was observed in the VPA+Zn group. Some anomalies such as hydrocephaly, spina bifida (Fig1), hemivertebrate (Fig 2), and rib malformations (Fig 3) were seen in VPA treated group. Compared to VPA group, low percentage of rib anomalies and spina bifida were observed in the VPA+Zn treated group, but there was no anomaly in control and Zn groups (Table 3).

Table 2. Data regarding weight and length of studied groups at 16th GD

Statistics		Mean	Standard Error	Minimum	Maximum
Variables	Groups				
Weight -16(gr)	VPA	0.474	0.023	0.40	0.68
	Control	0.592	0.03	0.42	0.89
	Zn	0.66	0.029	0.53	0.90
	Zn+ VPA	0.496	0.023	0.38	0.66
Length -16(cm)	VPA	1.621	0.025	1.48	1.92
	Control	1.917	0.031	1.61	2.19
	Zn	1.88	0.065	1.33	2.80
	Zn+ VPA	1.551	0.027	1.25	1.70

Abbrivation:VPA,Valproic Acid.

Table 3. Anomalies of skeletal system in studied groups*

Groups	Hydrocephaly [†]	Spina bifida [†]	Hemivertebrate [†]	Rib anomalies [†]
VPA (n=52) [‡]	7.69	7.69	3.84	11.5
Control (n=60)	0	0	0	0
Zn (n=62)	0	0	0	0
Zn +VPA (n=57)	0	1.75	0	3.57
Incidence of anomalies in rat based on text book §	0.02	0.67	Not reported	0.03
P value	<0.0005	<0.0005	-	<0.0005

Abbrivation:VPA,Valproic Acid

*Data are given as the percentage

[†]Calculated in half of the fetuses(n /2) according to toxicological references

[‡] n: number of live fetuses

§ See references ; No.17

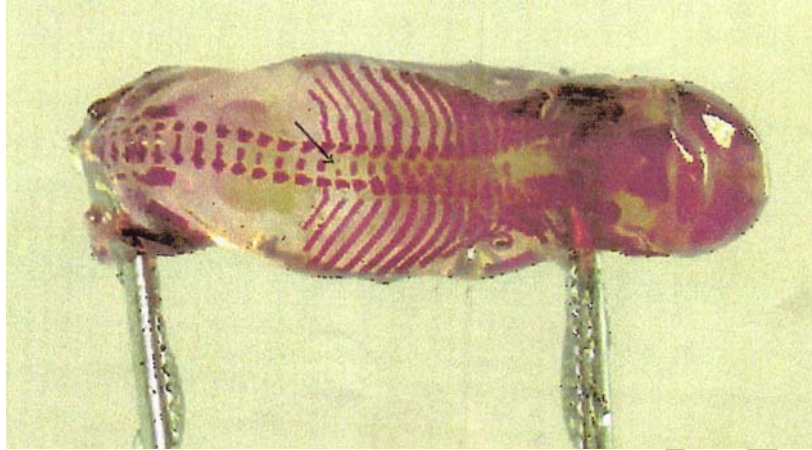


Fig. 1. Rat fetus of a valproic acid treated dam in day 20 of gestation. Incomplete ossification of vertebral centra (Spina bifida, T12)

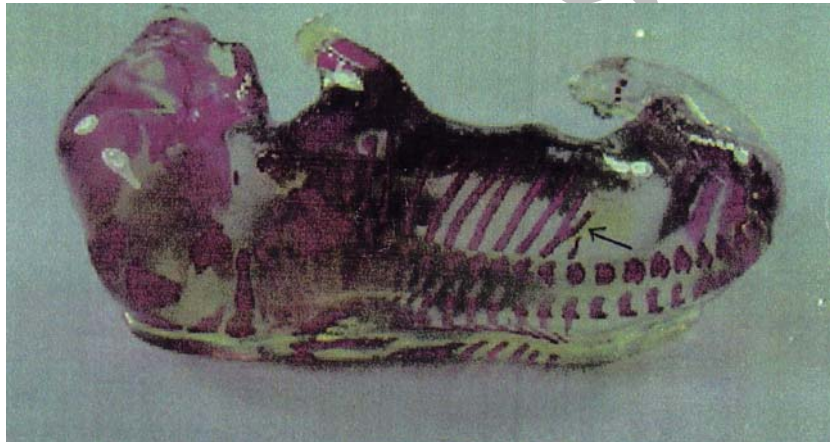

Fig. 2. Rat fetus of a valproic acid treated dam in day 20 of gestation. Interrelated malformations of vertebrae (a) L1 present as a right hemivertebra with (b) asymmetry of centra T13 and L2.

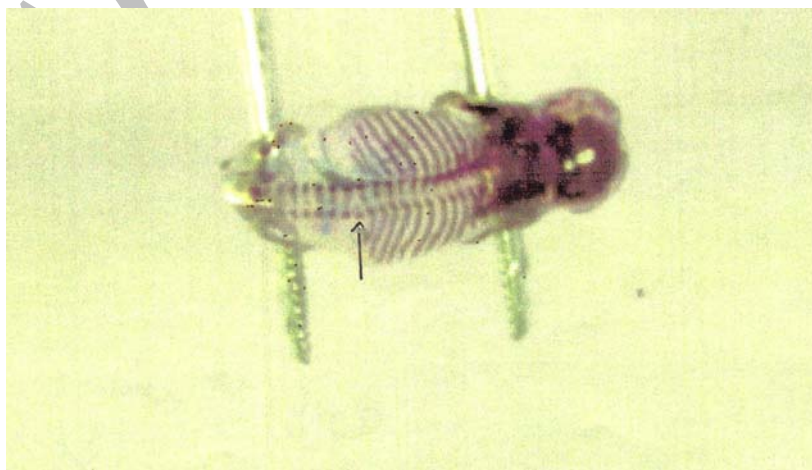


Fig. 3. Rat fetus of a valproic acid + zinc treated dam in day 20 of gestation. Malformation of ribs (present as a splitting or branching).

DISCUSSION

Results from the present experiment support the hypothesis that one of the biochemical abnormalities causing the teratogenicity of VPA is a drug-induced maternal plasma Zn deficiency. The data obtained in this study show that VPA administration to pregnant rats on days 6-15 of gestation resulted in significant reductions in maternal plasma Zn concentrations which were probably reflected by reduced placental Zn transfer and embryonic accumulation, similar to observation made by Keen et al. (12,13).

Hurd et al. published the findings which showed that administration of valproic acid for one week produced significant depletion of zinc in the plasma of rats (23). Cookley et al. and Daffron et al. demonstrated that although plasma Zn was depressed in VPA treated rats, there was no evidence of Zn deficiency induced by VPA (15, 16). In 1997, Altunbasak et al. observed that there was no zinc deficiency with administration of valproic acid (24). Considering high abnormalities and growth delays in fetuses obtained from VPA treated dams comparing with fetuses obtained from VPA+ Zn treated dams, it is suggested that the transitory Zn deficiency is induced by VPA and is developmentally toxic. A double-blind study of 580 African-American women in Alabama provides convincing evidence that poor maternal Zn status may also cause intrauterine growth retardation (20). Meanwhile, Goldenberg et al. demonstrated that administration of zinc during pregnancy was associated with an increase in birth weight, which is the same as findings in our research (25). Different studies show that the axial skeleton system is very sensitive to the teratogenicity of valproic acid which results in skeletal malformations and growth retardation (9,10).

Zinc is essential for bone mineralization, and it is bound to the mineral matrix, where this process starts. Several studies have demonstrated that zinc deficiency during pregnancy results in severe malformation of the fetus, especially in skeletal growth and calcification (26). Our results are similar to these experiments. It is well established that Zn is essential for normal embryo development, and deficiency of this element can result in congenital defects of multiple organ systems (8,18,20,21,27,28).

Acknowledgment

The authors wish to thank colleagues of the "Department of Biochemistry" of Tehran University of Medical Sciences especially Mrs. Aryabarzin and

the "Iranian Atomic Energy Organization" especially Mr. Rahimi for their cooperation.

REFERENCES

1. Pedley TA. The epilepsies. In: Goldman L, Bennett JC, editors. Cecil Text book of medicine. 21st edition. Philadelphia: W.B.Saunders co; 2000; p: 2151-2163.
2. Lowenstein DH. Seizures and epilepsy. In: Braunwald E, Fauci AS, Kasper DL, et al. editors. Harrison's Principles of Internal Medicine. 15th edition. USA: Mc Graw Hill 2001; p: 2354-2369.
3. Parfitt K, Sweetman S, Blake P, Parsons A, Martin Dale, The complete drug reference. 32nd ed. Pharmaceutical Press; 1999; p: 361-364, 1373.
4. Johannessen CU. Mechanisms of action of valproate: a commentary. *Neurochem Int* 2000 Aug-Sep; 37(2-3): 103-110.
5. Scott WJ, Schreiner CM, Nau H, Vorhees CV. Valproate induced limb malformations in mice associated with reduction of intracellular PH. *Reprod Toxicol* 1997 Jul-Aug; 11(4): 483-493.
6. DeCherney AH, Pernol MI. Current Obstetric and Gynecologic Diagnosis and Treatment. 8th edition. Along medical book 1996.
7. Sadler T W. Langmans Medical Embryology. 8th edition. Lippincotte Williams and Wilkins (LWW); 2000.
8. Klaassen CD, Casarett and Doull's Toxicology. The basic science of poisons. 5th edition. International Edition 1995.
9. Padmanabhan R, Ahmed I. Sodium Valproate augments spontaneous neural tube defects and axial skeletal malformations in mouse fetuses. *Reprod Toxicol* 1996 Sep-Oct; 10(5): 345-63.
10. Menegola E, Bronica ML, Nau H, Prati M, Ricolfi R, Giavini E. Teratogenic effects of sodium valproate in mice and rats at midgestation and at term. *Teratog Carcinog* 1996; 16(20): 97-108.
11. Nau H. Valproic acid-induced neural tube defects. *Ciba Found Symp* 1994; 181: 144-152.

12. Keen CL, Peters JM, Hurley LS. The effect of valproic acid on 65 Zn distribution in the pregnant rat. *J Nutr* 1989 Apr; 119(4): 607-611.
13. Bui LM, Taubeneck MW, Commisso JF, Hare JY, Faber WD, Keen CL. Altered Zinc metabolism contributes to the developmental toxicity of 2-ethylhexanoic acid, 2-ethylhexanol and valproic acid. *Toxicology* 1998 Feb; 126(1): 9-12.
14. Graf WD, Oleinik OE, Glauser TA, Maertens P, Eder DN, Pippenger CE. Altered antioxidant enzyme activities in children with a serious adverse experience related to valproic acid therapy. *Neuropediatrics* 1998 Aug; 29(4): 195-201.
15. Coakley ME, Brown NA. Valproic acid Teratogenicity in whole embryo culture is not prevented by Zinc supplementation. *Biochem Pharmacol* 1986 Mar; 35(6): 1052-1055.
16. Daffron JC, Kasarskis Ej. Effect of valproic acid on zinc metabolism in the rat. *Toxicol Lett* 1984 Dec; 23(3): 321-325.
17. Derelanko MJ, Hollinger MA. *Hand book of Toxicology*. 2nd edition. CRC Press 2001; P: 939.
18. Mahan LK, Stump SE. *Krause's Food Nutrition and Diet Therapy*. 10th edition. 2000 P: 133-134.
19. Subramanian P, Sivabalan S, Venugopal PM, Vasudevan K. Influence of chronic zinc supplementation on biochemical variables and circadian rhythms in Wistar rats. *Nutrition research* 2000; 20(3): 413-425.
20. King JC, Keen CL. Zinc. In: Shlls ME, Olson JA, Shike M, Ross AC, editors. *Modern Nutrition in Health and Disease*. 9th edition. 1999; P: 223-234.
21. Prasad AS. Zinc deficiency in women, Infants and children. *J Am coll Nutr* 1996 Apr; 15(2): 113-120.
22. Hlayes W. *Female reproductive and developmental toxicology. Principles and methods of toxicology*. 4th edition. Boston Massachusetts 2001; P: 1344-1362.
23. Hurd RW, Van Rinsvelt HA, Wilder BJ, Karas B, Maenhaut W, De Reu L. Selenium, zinc, and copper changes with valproic acid: possible relation to drug side effects. *Neurology* 1984 Oct; 34(10): 1393-1395.
24. Altunbasak S, Biatmakoui F, Baytok V, Herguner O, Burgut HR, Kayrin L. Serum and hair zinc levels in epileptic children taking valproic acid. *Biol Trace Elem Res* 1997 Jul- Aug; 58(1-2): 117-125.
25. Goldenberg RL, Tamura T, Neggers Y, Copper RL, Johnston KE, Dubard MB, Hauth JC. The effect of zinc supplementation on pregnancy outcome. *JAMA* 1995 Aug; 274(6): 463-468.
26. Salgueiro MJ, Zubillaga MB, Lysionek AE, Sarabia MI, Caro RA, De Paoli T, Hager A, Ettlín E, Weill R, Boccio JR. Bioavailability, biodistribution, and toxicity of bioZn-AAS: a new zinc source comparative studies in rats. *Nutrition* 2000; 16: 762-766.
27. Sole D, Rieckmann B, Lippelt RM, Lippelt RT, Amancio OM, Queiroz S de S, Naspitz CK. Zinc deficient diet consequences for pregnancy and offsprings of wistar rats. *Rev Paul Med* 1995 Jan-Feb; 113(1): 681-6.
28. Braga Costa TM, De Oliveria LM, Vannucchi H. Effect of zinc deficiency induced before and during pregnancy on the survival of female rats and their pups. *Braz J Med Bio Res* 1995 May; 28(5): 569-574.