

THE EVALUATION OF EPIPHYSEAL PLATE HISTOLOGICAL CHANGES IN OSTEOPETROTIC OP/OP MICE.

*ALIGHOLI SOBHANI, **AHMAD HOSSEINI, ***MOJTABA REZAZADEH, ****KIKUJI YAMASHITA, *****HOSEIN NIKZAD AND IRAJ RAGARDI KASHANI.

*Department of Anatomy, Faculty of Medicine, Tehran University of Medical Sciences, Tehran, Iran, **Department of Anatomy, Faculty of Medicine, Shahid Beheshti University of Medical Sciences, Tehran, Iran, ***Department of Anatomy, Faculty of Medical Sciences, Tarbiat Modarres University, Tehran, Iran, ****First Department of Anatomy, Faculty of Dentistry, Tokushima University, Tokushima, Japan, *****Department of Anatomy, Faculty of Medicine, Kashan University of Medical Sciences, Kashan, Iran.

ABSTRACT

This study was designed for evaluation of epiphyseal plate histological changes of femur bones in osteopetrotic op/op mice. In this study 5 osteopetrotic op/op mice which were purchased from the commercial source were used. The animals were killed by overdose of chloroform and their femur bones were extracted. The bones were fixed in 10% formaldehyde and decalcified by HCl (0.6N), and routine histological processing were performed. The sections were stained by H&E methods and studied by conventional light microscopy. The results showed that, proliferative zone (PZ) and especially hypertrophic zone (HZ) were much thickened. In the ossification zone, trabecular bones were irregular and atypical osteoblast cells were observed. The osteoclast cells were not attached to trabecular bones. The bone marrow cavity was restricted and bone marrow cells were poor and scattered. Findings of the present investigation are similar to those reported about epiphyseal plate in osteosclerotic (OC) mice in which epiphyseal plate especially hypertrophic zone was thickened and chondrocytes were not substituted for osteoblasts in calcified cartilage area. Also, osteoclast cells had been inactive or absent in OC mice. For prevention of other complication due to the epiphyseal plate changes in new borne, suitable and punctually treatment protocols such as prescription of Macrophage Colony Stimulating-Factor (MCS-F) could be useful.

Key Words: Chondroblast cells, Epiphyseal Plates, Osteopetrotic OP/OP Mice

INTRODUCTION

Osteopetrosis is a rare hereditary bone metabolic disease that was distinguished for the first time in 1904 by Albers-Schoberg (1) and for this reason was called Alber-Schoberg disease. Also, because of the high density of bones, some physicians called it Marble bones or marble bone disease (2, 3). This disease results from the lack of the activity or absence of osteoclast cells, severe decrease of monocytes and peritoneal macrophage due to the decrease in Macrophage- Colony Stimulating Factor (M-CSF) in this mutation (4, 5). Osteopetrosis appear in different types and different ages so have different treatment (6). The clinical appearance of osteopetrosis because of their accompanied immunitic and hematologic complication is different and while some cases die after birth because immunologic and hematogenic disorder, others continue the life for a long time (7, 8). The severe type of osteopetrosis in human is distinguished 2

months after birth by optical and hematological signs. Also, 2 types of osteopetrosis, lethal and nonlethal, are distinguished in adult people (9). In mice, 4 types of osteopetrotic mutation, happen at different chromosomes, and have been distinguished as follows: grey lethal (gl), microphthalmic (mi), osteosclerotic (oc) and osteopetrotic (op). The grey lethal (gl) and microphthalmic (mi) might results to death 5 weeks after the birth (10). Four other types mutations are discovered in rats as follows: Incisor absent (ia), osteopetrotic (op), toothless (tl) and microphthalmic blanc (mib) (11, 12, 13). In these mutations growth plate and its specific zones, proliferation zone, hypertrophic zone, calcified cartilage and substitution of chondrocytes by osteoblast cells are rare. The growth plate in this disease is affected, normal endochondral ossification is restricted, bone marrow cavity is limited and bone marrow cells are in weak condition and scattered (4, 14, 15). Marks and his coworker arranged a project for

histologic study of epiphyseal cartilage and ultrastructure of osteoclast cells in OC mice and reported that in OC mice growth plate particularly hypertrophic zone were vacant and substitution of chondrocytes by osteoblast cells were delayed (16). The chondroblast arrangement in hypertrophic zone was irregular, cells organism and external shape in light microscopy changed atypically. Also, hypertrophic zone vascularization was in a poor condition in OC mice (16). Also, Ricket like condition in human osteopetrosis has been reported (17, 18, 19, 20) and treatment of disorders has not been successful by vitamin D and other ricket protocols treatment in human osteopetrosis (21). For evaluation of superior epiphyseal plate histologic changes of femur bone, this study was designed on osteopetrotic op/op mice.

MATERIALS AND METHODS

In the present investigation, 40 days osteopetrotic op/op mice were purchased from Jackson laboratory (Bar Harbor Me USA). The animals were dieted by special soft nutrition at the animal house for one week and standard health conditions were arranged. For histological studies animals were killed by chloroform overdose and the femur bones were extracted. The harvested specimens were repeatedly fixed by 10% formaldehyde solution for one week and decalcified by HCl (0/6 N) for 2 weeks. The upper epiphyseal plate region was dissected. After routine histological processing the selected part of femur bone were embedded in hard paraffin longitudinally and were sectioned at 6 micron thickness (17). The sections at intervals of 60 micron were stained with Hematoxilin and Eosin (H&E). By the above-mentioned condition sections were prepared from normal animals and stained by H&E. Also, semi thin sections were prepared and stained by Toluiden blue for 2 groups. The slides were studied microscopically and photos were obtained.

RESULTS

In osteopetrotic op/op group by Hematoxilin and Eosin staining sever thickness of proliferative zone (PZ) and especially Hypertrophic zone (HZ) in longitudinal view were observed in contrast to control group (Fig 1a, 1b). The normal columns of chondroblasts, in the hypertrophic zone (HZ), were changed and irregular in the op/op groups (Fig 2a, 2b). The chondrocytes by Hematoxilin and Eosin staining were appeared vacant at calcified cartilage (CC) region in osteopetrotic op/op mice (Fig 3a, 3b). Osteoblast cells were

abnormal in external morphology, and typical epitheloid osteoblast cells were not observed and regulation of trabecular bones in op/op mice were destroyed (Fig 3a, 3b). Bone marrow cavities in experimental group were very restricted and bone marrow cells were poor and scattered. Also, no osteoclast cells in op/op group could be detected (Fig 3a, 3b). By toluiden-blue staining, the chondrocytes in terminal portion of hypertrophic zone were large and were accompanied by reach granules (Fig 4a, 4b).

DISCUSSION

Osteoporosis is a rare congenital disorder which is observed in one of 200000 children. It prevents formation of bone marrow cells and results in abnormal long bone development, blindness (22), stounded growth, abnormal dental development and fragile bones (23). Radiologically, this disease is characterized by generalized increases in skeletal density in which bones look solid on X-ray with defect in metaphiseal modeling (24, 25). Sever forms of osteopetrosis have been described with overlapping of clinical and radiographic features (25). Irregular conditions of the bone at the metaphyses may produce the appearance of parallel plates of dense bone at the end of long bones (16). In this investigation, sever thickness of proliferative zone (PZ) and especially hyperthrophic zone (HZ) of growth plate were observed. These findings resemble to the rickets condition that has been explained by other investigations (20, 26) and in other type of osteoporosis (27). The chondrocytes by H&E staining appeared vacant and was accompanied with granules by Toloiden blue staining. Marks and his coworkers by arrangement of the results of histological study of epiphyseal plate in oc mice reported similar results (28). In this investigation typical epitheloidal osteoblasts cells were not observed and regulation of trabecular bones were destroyed. Poppof has reported this characters in rabbits (29). In the present investigation bone marrow cavity was restricted and marrow cavities cells deficiency were similar to those of previous reports (30, 31). Osteoclast cells attached to bone trabeculae at present study could not be distinguished. Recently, Amling and his coworker reported that, in the absence of bone resorption because of osteoclastic function, bone formation continues and leads to progressive accentuation of the osteopetrotic phenotype in c-src-deficient mice (32). According to Nomura and his coworker idea, osteoclast normal function was dependent to the presence of a target gene for

Microphthalmia mutation (Mi) that is essential for the proliferation/differentiation of osteoclasts (33). It is believed that decrease in the amount of macrophage colony stimulating factor in these mutations, cause absence or inactivity of osteoclast cells (34, 35, 36, 37, 38).

REFERENCES

1. Albers-schonberg, H. (1904) Roentgenbilder enter seltenen knochener-krunkung. Munchen Med. Wochenschr. 51: 365-369.
2. Zawisch, C. (1947) Marble bone diseases. A study of osteogenesis. Arch. Pathol. 43: 55-75.
3. Engfeld, B., fajers, C.M., lodin, H., Pehrson, M. (1960) Studies of osteopetrosis. III Roentgenological and pathologic anatomical investigation on some of the bone changes. Acta. Paediat. 49: 391-408.
4. Marks, S.C.Jr. (1976) Tooth eruption and bone resorption: Exoerimental investigation of the ia(osteopetrotic) rat as a model for studying their relationships. J. Oral Pathol. 5: 149-163.
5. Marks, S.C.Jr. (1982) Morphological evidence for reduced bone resorption in osteopetrotic op/op mice. Am. J. Anat. 163: 157-167.
6. Marks, S.C.Jr. (1994) Osteopetrosis. Current opinion in orthopaedics. 5: 39-42.
7. Whyte, M.P. (1993) Carbonic anhydrase II defficiency. Clin. Orthop. 294: 79-84.
8. Mongham, B.A., Kaplan, F.S., August, C.S. Fallon, M.D. (1991) Transiant infantile osteopetrosis. J. Pediat. 118:252-256.
9. Gerristen, E.J.A., Vossen, J.M., Van, L., Hermans, J., Heltrich, M.H., Griscelli, C. Fischer, A. (1994) Autosomal recessive osteopetrosis: Variability of finding of diagnosis during the natural course. Pediatric. 93: 247-253.
10. Jedrzejczak, W., Bartocci, A., Ferrante, A.W. Jr., Ansari, A., Sell, K.W., Pollard, J.W. Stanley, E.R. (1990) Total abcnce of colony stimulating factor 1 in the macrophage-deficient osteopetrotic (op/op) mouse. Proc. Natl. Acad. Sci. USA. 87: 4828-4832.
11. Moutier, R., Lamendin, H. Berenhols, S. (1973) Osteopetrosis par mutation spontanee chezle rat. Experientia. 78-101.
12. Moutier, R., Toyama, K., Cotton, W.R. Galens J.F. (1976) Three recessive genes for congenital osteopetrosis in the Norway rat. J. Hered. 67: 189-195.
13. Moutier, R., Ostrowski, K. Lamendin, H. (1989) Microphthalmia: A new recessive mutation in the Norway rat. J. Hered. 80: 76-78.
14. Marks, S.C.Jr. Walker, D.G. (1976) Mamalian osteopetrosis: A model for studying cellular and humoral factors in bone resorption. The biochemistry and phisiology of bone. G.H. Bourne ed. Academic Press. New York. PP: 227-301.
15. Abboud, S., Woodruff, K., Liu, C., Shen, V. Ghosh-Choudhury, N. (2002) Rescue of the osteopetrotic defect in op/op mice by osteoblasts-specific targeting of soluble colony-stimulating factor-1. Endocrinology: 143(5): 1942-1949.
16. Mark, F. Marks, S.C. (1985) Morphological evidence of reduced bone resorption in the osteopetrotic (oc) mouse. The American J. of Anat. 172: 41-50.
17. Reeves, J., arnand, S., Gordon, S., subran, B., Bloock, M., huffer, W., Arnaud C., Munday, G. Haussler, M. (1981) The pathogenesis of infantile malignant osteopetrosis. Metab Bone Dis Relate Res. 3: 135-142.
18. Ozdrim, E., alty, c., Prinar, t. (1981) osteopetrosis with rickets in infancy. Turkish J. Ped. 23: 211-218.
19. Milgram, J.W., Justy, M. (1984) Osteopetrosis. J. Bone Joint Surg. 64A: 912-929.
20. Boncci, E., sartori, E., Spina, M. (1975) Osteopetrosis Fetalis. Report on a case with special refference to ultrastructure. Virchows Arch A Pathol Anat Histol. 368: 109-121.
21. Zamboni, G., Cecchettin, M., Marradi, P., Foradori, M., Zoppi, G. (1977) Association of osteopetrosis and vitamin D resistant rickets. Helv. Paediat. Acta. 32: 363-368.
22. Marks, S.C.Jr. (1981) Tooth eruptions depend on bone resorption: Experimental evidence from osteopetrotic (ia) rats. Metab Bone Dis Relate Res. 3: 107-115.
23. Philipart, C., Arys, A., Dourv, N. (1989) Effect of bone marrow transplantation in impacted dental germs in osteopetrotic op/op rats. J. Oral Pathol. Med. 18: 163-166.

24. Mintz, S.M., Martone, C.H., Anovi, Y. (1993) Avoiding problems in patients with craniotubular bone disorders. *J. Am. Dent. Assoc.* 124: 116-118.
25. Jagge, H.L. (1972) Metabolic, degenerative and inflammatory disease of bone and joints. Philadelphia, Lea and Febiger. 178-192.
26. Ozdrim, E., Alty, C., Pinar T. (1981) Osteopetrosis with ricket in infancy. *Turkish J. Ped.* 23: 211-218.
27. Marks, S.C.Jr., Seifert, M.F., Fox, R.R. (1986) The osteopetrotic rabbit general and skeletal features of a new outbred stock. *Bone.* 7: 300-307.
28. Seifert, M.F., Marks, S.C.Jr. (1985) Morphologic evidence of reduced bone resorption in the osteopetrotic (oc) mouse. *Am-J-Anat.* 172: 41-48.
29. Popoff, S.N., Marks, S.C.Jr. (1990) The relationship of abnormalities in dental and skeletal development in the osteopetrotic rabbit. *J. Oral Pathol. Med.* 19: 5-12.
30. Marks, S.C.Jr. (1982) Morphologic evidence for reduced bone resorption in osteopetrotic op/op mice. *Am. J. Anat.* 163: 157-167.
31. Steingrimsson, E., Tessarollo, L., Pathak, B., Hou, L., Arnheiter, H., Copeland, N.G., Jenkins, NA. (2002) *Mitf* and *Tfe3*, two members of the *Mitf-Tfe* family of bHLH-Zip transcription factors, have important but functionally redundant roles in osteoclast development. *Proc. Natl. Acad. Sci. USA*: 99 (7): 4477-4482.
32. Amling, M., Neff, L., Priemel, M., Schilling, A.F., Rueger, G.M., Baron, B. (2000) Progressive increase in bone mass and development of odontomas in aging osteopetrotic *c-src*-deficient mice. *Bone.* 27(5): 603-610.
33. Nomura, S., Sakuma, T., Higashibata, Y., Oboki, K., Sato, M. (2001) Molecular cause of the severe functional deficiency in osteoblasts by an arginine deletion in the basic domain of *Mi* transcription factor. *J. Bone Miner. Metab.* 19: 183-187.
34. Tanaka, S., Takahashi, N., Udagava, N., Tamura, T., Aktsu, T., Stanley, E.R., Kurakava, T., Suda, T. (1993) Macrophage colony stimulating factor is indispensable for both proliferation and differentiation of osteoclast progenitors. *J. Clin. Invest.* 91: 257-263.
35. Antonioly-Corboz, V., Cecchini, m.G., felix, R., Flesich, H., Vander Pluijm, G., Lowik, G.W.M. (1992) Effect of Macrophage colony stimulating factor on in vitro osteoclast generation and bone resorption. *Endocrinology.* 130: 437-441.
36. Flanagan, AM., Massey, HM., Wilson, c., Vellodi, A., Horton, MA., Steward, C.G. (2002) Macrophage colony-stimulating factor and receptor activator NF-kappaB ligand fail to rescue osteoclast-poor human malignant infantile osteopetrosis in vitro. *Bone*: 30(1): 85-90.
37. Tondravi, M.M., Marckchr, S.R., Anderson, K., Erdmann, J.M., Mark, R., Teitelbaum, S.L. (1997) Osteopetrosis in mice lacking hematopoietic transcription factor *Pu. 1*. *Nature.* 386: 81-84.
38. Suda, T., Takahashi, N., Martin, T. (1992) Modulation of osteoclast differentiation. *Endocr. Res.* 13: 66-80.

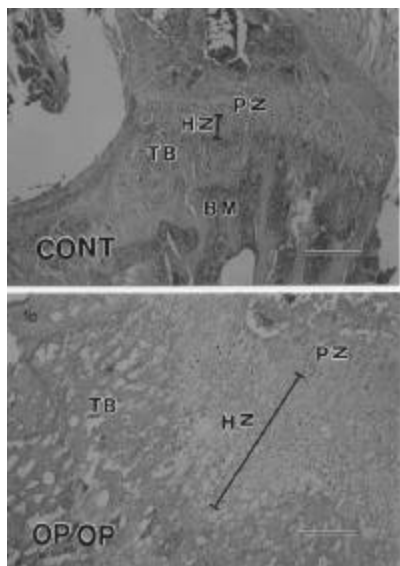


Figure 1- Light microscopic view from longitudinal section of proximal epiphyseal plate (Femur) in osteopetrotic op/op (a) and normal animals (b).

The proliferative zone (PZ) and especially Hypertrophic Zone (HZ) in osteopetrotic op/op mice is too thickened in contrast to the normal animals. Also, Trabecular bone (TB) is irregular in op/op mice.

Staining: Hematoxylin and Eosin
Original magnification: X100

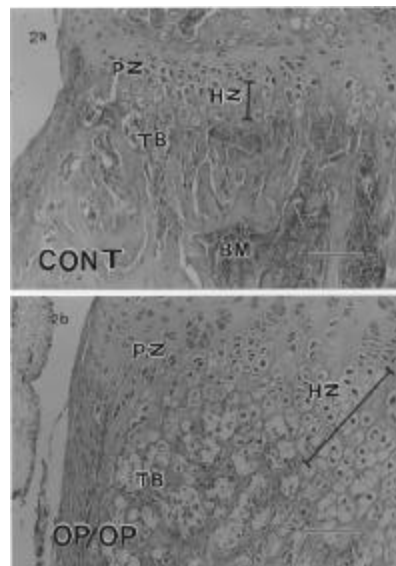


Figure 2- Light microscopic view from longitudinal section of proximal epiphyseal plate (Femur) in osteopetrotic op/op (a) and normal animals (b).

The trabecular bones (TB) in osteopetrotic op/op mice are irregular in contrast to normal animals. Normal typical epitheloidal osteoblast cells were not shown in op/op group. Bone marrow cavities (BM) are restricted and bone marrow cells are not enough in op/op group.

Staining: Hematoxylin and Eosin.
Original magnification: X 200

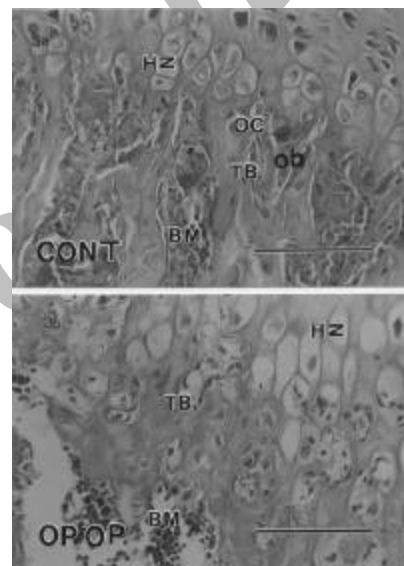


Figure 3- High magnified light microscopic view from longitudinal section of proximal epiphyseal plate (Femur) in osteopetrotic op/op (a) and normal animals (b). The chondrocytes in calcified cartilage (cc) region were observed vacant in op/op group by Hematoxylin and Eosin staining. The trabecular bone (TB) is irregular and normal epitheloidal osteoblast cells are not appeared in op/op group. Osteoclast cells are not shown in op/op group.

Staining: Hematoxylin and Eosin.
Original magnification: X400

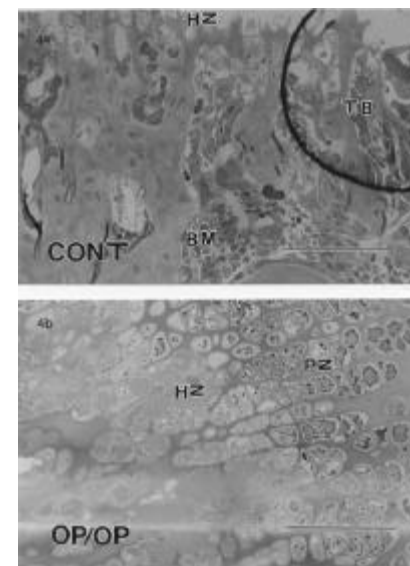


Figure 4- Light microscopic view from longitudinal section of proximal epiphyseal plate (Femur) in osteopetrotic op/op (a) and normal animals (b).

The chondrocytes in terminal portion of hypertrophic zone (HZ) in the region of calcified cartilage (cc) is accompanied by some granules in op/op group. But, in normal animals these granules however did not appear.

Staining: Toluidin Blue
Original magnification: X400