

Urological Oncology

A Comparison between Clinical and Pathologic Staging in Patients with Bladder Cancer

MEHRSAI A¹, MANSOORI D², TAHERI MAHMOODI M¹, SINA A¹, SERAJI A¹,
POURMAND GH¹

1- Department of Urology, Sina Hospital, Tehran University of Medical Sciences, Tehran, Iran

2- Department of Urology, Shaheed Mohammadi Hospital, Bandarabbass University of Medical Sciences, Bandarabbass, Iran

ABSTRACT

Purpose: To determine the accuracy of clinical staging methods of bladder cancer and TURBT results in estimating the pathologic stage of tumor.

Materials and Methods: Thirty two patients who had undergone radical cystectomy were studied in this retrospective survey. The results of bimanual examination, cystoscopy, TURBT pathology report and the tumor contour in CT scan, (size, infiltrative deepness, pelvic lymph nodes involvement and hydronephrosis) were recorded. The type of surgery and pathologic report of cystectomy sample were analyzed as well. Then the results of bimanual examination, tumor size, hydronephrosis and CT scan findings including tumor infiltrative deepness, pelvic lymph adenopathy and TURBT findings were compared to pathologic results of cystectomy sample.

Results: Seven patients were females and 25 were males. Their mean age was 62 (range 36 to 80) years. Gross hematuria and irritative urinary symptoms were the most common complaints. The duration between symptom manifestation and patient's referral was 5 days to 72 months (mean 12 months). Bimanual examination in estimating the extravesical involvement of tumor had a specificity of 82%, sensitivity of 46%, positive predictive value of 70% and negative predictive value of 63%. The size of tumor in determining extravesical involvement had a specificity of 41%, sensitivity of 93%, and positive predictive value of 58% and negative predictive value of 87%. Hydronephrosis was present in 15 patients of whom, 14(93%) had bladder muscle involvement. CT scan specificity was 70%, and sensitivity was 46% regarding pelvic lymph adenopathy and perivesical fat involvement. In TURBT report no muscle sample was observed in 11 cases, so that the interpretations of results were impossible. The reported grade of tumor was lower than pathologic sample of cystectomy in 4 patients.

Conclusion: Clinical staging in invasive bladder cancers has not high accuracy regarding the involvement of bladder surrounding fats and pelvic adenopathies. A tumor sized more than 5 cm could be sensitive in estimating extravesical involvement. Positive predictive value of hydronephrosis is considerable regarding bladder muscle involvement. Tumor understaging by TURBT is happened in high percentage of patients with invasive bladder cancer.

KEY WORDS: bladder cancer , bimanual palpation, hydronephrosis, tumor size, TURBT

Introduction

Radical cystectomy is considered as a standard treatment in muscle invasive urothelial bladder tumors. Before such treatment, clinical staging is done by physical examination, imaging, liver function tests, bladder endoscopy, bimanual examination under anesthesia, tumor biopsy, and TURBT; however, pathologic staging which is the most important factor in patient prognosis is done ultimately following the study of the full thickness of bladder wall and lymphatic glands, that is after radical cystectomy.^(1,2)

There is always a risk of error in clinical staging of patients with bladder cancer which may even exceed to 50%.⁽³⁾ Bimanual examination of the bladder is used to detect palpable extravesical mass. Palpable mass particularly after TURBT affects patient survival.⁽⁴⁾ CT scan is a common method in clinical staging. Its sensitivity in estimating extravesical involvement of tumor is between 57% and 96% and its specificity is reported to be between 60% and 93%.^(5,6,7) Hydronephrosis is a sign of ureteral obstruction and is regarded as an important factor in staging. It is associated with muscle invasion in 70-90% and distant metastasis in 55%.⁽⁸⁾ The size of tumor is also considered as an effective factor in patients' prognosis⁽⁹⁾ and finally TURBT is regarded as one of the most important methods of clinical staging and determining biologic characteristics of tumor; however, there is a risk of error in estimating infiltrative deepness of tumor and its grade and understaging could be occurred even in more than 50% of cases.⁽¹⁰⁾

Muscle invasion is indicated in more than 95% of high grade tumors in patients who underwent cystectomy; while, the deepness of high grade tumors is mostly estimated lower than its actual amount via TURBT.⁽²⁾ The efficiency of the following items has been studied in this survey:

1. bimanual examination,
2. CT scan findings including tumor size, hydronephrosis, infiltrative deepness of tumor regarding prevesical fat involvement, and pelvic adenopathy,
3. TURBT report to estimate pathologic stage of bladder cancer.

Materials and Methods

Thirty two patients with bladder cancer who had undergone surgical radical cystectomy from 1999 to 2001, were enrolled in this retrospective survey.

Patients' preoperative evaluations were as follows: history taking, physical examination, chest x-ray, CBC, BUN, Cr, electrolytes, liver function tests, CT scan, bone scan, and barium enema or colonoscopy for patients who were candidates for urinary diversion, in order to rule out any colorectal lesion.

The following data were collected from each patient: the results of bimanual bladder examination, cystoscopy, TURBT or tumor biopsy report, tumor site and size in pelvic CT scan, regarding size, infiltrative deepness, hydronephrosis, pelvic lymph nodes involvement as well as type of surgery and pathologic report of radical cystectomy.

In this survey, the efficiency of bimanual examination, infiltrative deepness, tumor size in CT scan, hydronephrosis, and TURBT or biopsy report in estimating pathologic stage of bladder tumor were studied.

Tumor staging was performed according to TNM classification (Edition 1997) and tumor grading was conducted in accordance with WHO classification (grade I to III).

Results

Seven out of 32 studied patients were females and 25 were males. Patients mean age was 61 (range 36 to 80) years. A history of gross hematuria was reported in 29 patients, irritative urinary symptoms in 15, and obstructive urinary symptoms in 6 and suprapubic pain in 3.

One patient suffered from anuria. Mean duration between the disease manifestation and referral time was 12 (range 5 to 72) months. The tumor was palpable by bimanual examination in 11 patients. Table 1 shows the results of comparing palpable tumor and final pathology.

The specificity of bimanual examination in this study was 82%, sensitivity was 46%, positive predictive value was 70%, and negative predictive value was 63%. According to cystoscopy and CT scan, the tumor was located on the left wall in 11 patients, right in 8, bladder base in 7, diffuse in

TABLE 1. Results of bimanual examination of tumor and their comparison to pathologic results of radical cystectomy samples

Total	No extravesical tumor involvement (T1, T2)	Extravesical tumor involvement (T3, T4)	
10	3	7	Palpable cases
22	14	8	No-palpable cases
32	17	15	Total

the bladder in 4, at the bladder dome in 1, and in the bladder diverticulum in 1. Trigone involvement was not present in 7 patients, while it was observed via cystoscopy in the remained patients. Tumor size (the largest dimension of tumor) was measured in CT scan. It was compared to final pathologic results (table 2). Tumor size specificity in determining extravesical involvement was 41% and its sensitivity was 93%. Its positive productive value was 58% and negative productive value was 87%. Unilateral or bilateral hydronephrosis were seen in 15 patients. Table 3 shows the relationship between hydronephrosis and pathologic findings of surgical samples. The specificity of hydronephrosis in determining the involvement of bladder muscle was 75%, its sensitivity was 50%, its positive productive value was 93%, and its negative productive value was 17%. Table 4 shows the involvement of perivesical fat or pelvic lymph adenopathy in CT scan and its comparison to final pathology.

The specificity of CT scan in determining perivesical fat involvement or pelvic adenopathy was 70%, its sensitivity was 46%, its positive pro-

ductive value was 58% and its negative productive value was 60%.

In the TURBT report of patients who underwent cystectomy, no muscular sample was seen in biopsy of 11 patients and only mucosal layer involvement with tumor was reported. Tumor grade was lower than radical cystectomy sample in 4 cases. Clinical evidences of muscular involvement including TURBT or CT scan results were the indication of radical cystectomy in 29 cases. Surgical operation was performed in 3 cases considering big size of tumor or the presence of bladder diverticulum's, despite the lack of evidence of bladder muscular involvement. Figures 1 and 2 show types of used urinary diversion and final report of patients pathology. In situ carcinoma was also simultaneously reported in 5 patients.

Discussion

The stage of bladder cancer has been reported in several reports as the most important criterion of prognosis and patient's survival.^(11,12) Despite the innovation of modern methods of imaging, clinical staging of bladder cancer has a high percentage of errors.⁽¹³⁾ A comparison has been conducted between the accuracy of different methods of clinical staging and final pathologic staging. Bimanual examination of bladder particularly under anesthesia and following TURBT is regarded as an important staging tool. In a study conducted on 276 Swedish patients, 5-year patient survival was

TABLE 2. A comparison between of tumor size and pathologic reports of radical cystectomy samples

Total	No extravesical involvement (T1 or T2, N0)	Extravesical involvement (T3 or T4 or N+)	
24	10	14	Tumor lager than 5 cm
8	7	1	Tumor smaller than 5 cm
32	17	15	Total

TABLE 3. A comparison between hydronephrosis and pathologic reports of radical cystectomy samples

Total	No muscular involvement (T1)	Muscular involvement (T2, T3, T4)	
15	1	14	Hydronephrosis
17	3	14	Without hydronephrosis
32	4	28	Total

TABLE 4. A comparison between CT scan findings and pathologic reports of radical cystectomy samples

Total	No extravesical involvement (T1 or T2, N0)	Extravesical involvement (T3 or T4 or N+)	
12	5	7	Presence of Perivesical fat involvement or pelvic adenopathy in CT scan
20	12	8	No extravesical involvement in CT scan
32	17	15	Total

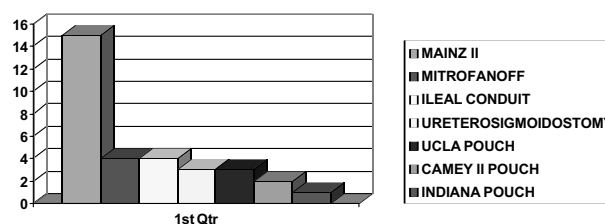


FIG. 1. Types of urinary diversion surgeries in patients

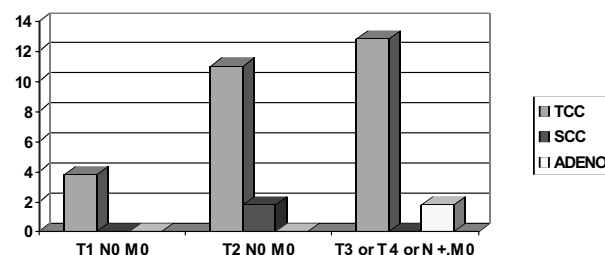


FIG. 2. Results of pathologic report of cystectomy samples of patients

reduced from 83% (in not palpable cases) to 50% in the cases of palpable mass.⁽⁴⁾

The specificity of this examination was acceptable in the prognosis of extravescical tumor involvement; sensitivity was low, only about 46%. The reason might be bimanual examination without anesthesia, which led to lack of complete relaxation of abdominal muscles. Patient obesity, unavailable bladder tumor as well as small size of tumor are regarded other influencing factors for false negative results in this examination, as it mentioned in references. Previous pelvic surgical history, radiotherapy and inflammatory lesions of rectosigmoid are among false positive reasons.⁽²⁾

The size of tumor is considered as a prognostic factor in bladder tumors. In a study conducted on 64 patients who underwent radical cystectomy, the size of tumor, as an independent factor, affected on 10-year cancer-specific survival.⁽⁹⁾

In this study 14 out of 15 patients whose pathologic stages were T3 or higher, had a tumor larger than 5 cm which indicated the necessity of invasive treatment in large tumors particularly high grade ones.

Hydronephrosis is regarded as a prognostic criterion in bladder tumors by which muscular involvement is reported to be between 70% and 90%.⁽⁸⁾ No deference has been seen between unilateral and bilateral hydronephrosis in most performed studies considering the relationship between the stage of cancer and obstruction,^(14,15) though, some believe that bilateral hydronephrosis has worsen prognosis.⁽⁸⁾

CT scan is conducted to determine the infiltrative deepness of tumor in bladder muscle and the involvement of surrounding soft tissue; however, these changes could be inflammatory and non-infiltrative. In addition, if CT scan is performed after bladder tumor TUR, these changes might be due to extravasation of fluid. In a survey, the similarity between CT scan findings and pathologic staging was reported in 86% of 50 patients who underwent radical cystectomy.⁽¹⁶⁾ In another study this rate was 68% in 60 patients.⁽¹⁷⁾ In a retrospective study carried out on 82 patients, final result showed that CT scan was unable to detect microscopic involvement or little extravescical extension of tumor and lymphatic metastasis; moreover, it had a high understaging rate and lacked the effect on surgical treatment of patients.⁽¹⁸⁾ In this study CT scan specificity was 70% and sensitivity was 46% which insure the unreliability of this method in tumor staging.

TURBT is one of the most important approaches in bladder cancer staging; however, the difference of surgeons' experience and the variety of deepness of removed tissue as well as problem in pathologic interpretation of samples decreases the accuracy of this method in determining the stage of tumor. If the sample is so small or if just a biopsy of tumor was taken, a high percentage of error would be occurred in determining infiltrative deepness of tumor and its grade. In a survey performed on 105 patients, understaging of tumor was reported via TURBT in 55 patients.⁽¹⁰⁾ In this study no muscular sample was seen in TURBT samples in 11(34%) patients of Mainly, the lack of muscular sample in bladder biopsy is considered a risk factor in understaging bladder tumor.⁽¹⁹⁾ Tumor grade was lower than final pathology in 4 other patients.

Conclusion

This survey which was conducted to assess the efficacy of clinical methods for staging of invasive bladder invasive tumors showed that bimanual palpation lacks adequate sensitivity for determining extravescical involvement of tumor but it is mostly specified. A tumor lager than 5 cm could lead to high sensitivity in predicting extravescical involvement of tumor, but it has not a high specificity. Regarding bladder muscle involvement, hydronephrosis has a high positive predictive value and CT scan has low accuracy in determining the involvement of surrounding bladder tissue and pelvic lymphadenopathy. Furthermore, understaging with TURBT or biopsy is occurred in high percentage of patients, specially, when no bladder muscular tissue is seen in TUR samples. Finally, it seems that none of the current common methods is adequately credible for clinical staging of bladder cancer in the prognosis of pathologic stage. Probably, using molecular markers or modern methods of imaging like spiral CT scan and MRI may be more accurate in staging.

It is recommended to perform prospective study with more samples and with modern imaging modalities and using molecular markers to predict pathologic stage of invasive bladder tumors.

References

1. Messing EM, Catalona W. Urothelial tumors of the urinary tract. In: Walsh PC, Retik AB, Vaughan ED, editors. *Campbell's Urology*. WB Saunders Company; 1998. p. 2327-2410.
2. Droller MJ, Gospodarowicz MK. *Staging of bladder cancer*.

- In: Vogelzang NJ, Scardino PT, Shipley WU, editors. *Comprehensive Textbook of Genitourinary Oncology*. Lippincott Williams Wilkins; 2000. p. 343-355.
3. Skinner DG, Tift JP, Kaufman JJ. High dose, short course preoperative radiation therapy and immediate single stage radical cystectomy with pelvic node dissection in the management of bladder cancer. *J Urol* 1982; 127: 671.
 4. Wijkstrom H, Norming U, Lagerkvist M, Nilsson B, Naslund J, Wiklund P. Evaluation of clinical before cystectomy in transitional cell bladder carcinoma: a long-term follow-up of 276 consecutive patients. *Br J Urol* 1998 May; 81(5): 686-91.
 5. See WA, Fuller JR. Staging of advanced bladder cancer: current concepts and pitfalls [Review] *Urol Clin North Am* 1992; 19: 663-683.
 6. Voges GE, Tauschke E, Stockle M, et al. Computerized tomography: an unreliable method for accurate staging of bladder tumors in patients who are candidates for radical cystectomy. *J Urol* 1989; 142: 927-974.
 7. Barentsz JO, Witjes JA, Rujis JH. What is new in bladder cancer imaging. *Urol Clin North Am* 1997; 24: 583-602.
 8. Haleblan GE, Skinner EC, Dickinson MG, Lieskovsky G, Boyd SD, Skinner DG. Hydronephrosis as a prognostic indicator in bladder cancer patients. *J Urol* 1998; 160(6): 2011-2014.
 9. Cheng L, Neumann RM, Scherer BG, Weaver AL, Leibovich BC, et al. Tumor size predicts the survival of patients with pathologic stage T2 bladder carcinoma: a critical evaluation of the depth of muscle invasion *Cancer* 1999 Jun 15; 85(12): 2638-47.
 10. Cheng L, Neumann RM, Weaver AL, Chevillie JC, Leibovich BC, Ramani DM, et al. Grading and staging of bladder carcinoma in transurethral resection specimens. Correlation with 105 matched cystectomy specimens. *Am J Clin Pathol* 2000 Feb; 113(2): 275-9.
 11. Thrasher JB, Frazier HA, Robertson JE, Dodge RK and Paulson DF. Clinical variables which serve as predictors of cancer-specific survival among patients treated with radical cystectomy for transitional cell carcinoma of the bladder and prostate. *Cancer* 1994; 73: 1708.
 12. Narayana AS, Loening SA, Slymen DJ and Culp DA. Bladder cancer: factors affecting survival *J Urol* 1983; 130: 56.
 13. Holzbeierlein JM, Smith JR. Management of superficial Ta/T1 TIS bladder cancer. Vogelzang NJ, Scardino PT, Shipley WU, editors. In: *Comprehensive textbook of Genitourinary oncology*. Lippincott Williams and wilkins; 2000. p. 384-393.
 14. Hatch TR, Barry JM. The value of excretory Urography in staging bladder cancer. *J Urol* 1986; 135: 49.
 15. Lange EK. The roentgenographic assessment of bladder tumors. A comparison of the diagnostic accuracy of roentgenographic techniques. *Cancer* 1969; 23: 717.
 16. Liu D, Chen Q, Tang A. The evaluation of clinical staging by preoperative CT examination in patients with bladder cancer. *Zhonghua wai ke za zhi* 1996 May; 34(5): 283-5 [abstract].
 17. Nurmi M, Katevuo K, Puntala P. Reliability of CT in preoperative evaluation of bladder carcinoma *Scan. J Urol Nephrol* 1988; 22(2): 125-8.
 18. Paik ML, Scolieri MJ, Brown SL, Spirnak JP, Resnick MI. Limitation of computerized tomography in staging invasive bladder cancer before radical cystectomy. *J Urol* 2000 Jun; 163(6): 1693-6.
 19. Dutta SC, Smith JA Jr, Shappell SB, Coffey CS, Chang SS, Cookson MS. Clinical understaging of high risk non-musele invasive urothelial carcinoma treated with radical cystectomy. *J Urol* 2001 Aug; 166(2): 490-493.