

# SID



سرویس های ویژه



سرویس ترجمه تخصصی



کارگاه های آموزشی



بلاگ مرکز اطلاعات علمی



عضویت در خبرنامه



فیلم های آموزشی

## کارگاه های آموزشی مرکز اطلاعات علمی جهاد دانشگاهی



کارگاه آنلاین آشنایی با پایگاه های اطلاعات علمی بین المللی و ترند های جستجو



مباحث پیشرفته یادگیری عمیق؛ شبکه های توجه گرافی (Graph Attention Networks)



کارگاه آنلاین مقاله نویسی IEEE و ISI ویژه فنی و مهندسی

# Nail fold Capillaroscopic Findings in Iranian Patients with Systemic Lupus Erythematosus

Alireza Rajaei<sup>1</sup>, Pooneh Dehghan<sup>2\*</sup>, Saideh Ariannia<sup>1</sup>

<sup>1</sup>Department of Rheumatology, Loghman Hospital, Shahid Beheshti University of Medical Sciences, Tehran, Iran

<sup>2</sup>Taleghani Hospital Research Development Center, Shahid Beheshti University of Medical Sciences, Tehran, Iran

Received: 22 February, 2016; Accepted: 19 June, 2016

## Abstract

**Background:** Systemic Lupus Erythematosus is a progressive autoimmune disease with a wide range of morphological and functional changes in microscopic examination of small blood vessels. Identification of vascular diseases at early stage, plays an essential role in the prevention of its' vascular complications. Nailfold capillaroscopy (NFC) is a non-invasive, easy, painless, and accurate method for evaluation of microcirculation and could be used for this purpose. The vast majority of studies on capillaroscopy in lupus patients have shown that changes are not specified to lupus –unlike Systemic Sclerosis- and are more likely to overlap with other diseases. Therefore, it was decided to check capillaroscopic changes and evaluate morphological changes and capillary structure in terms of quality and quantity in lupus patients.

**Materials and Methods:** Nail fold capillaroscopic findings of 114 patients aged 19-75 years old were reviewed in this study. The results were categorized as: a) normal, b) non-specific morphological abnormalities, and c) Scleroderma-like pattern. Results were analyzed qualitatively and quantitatively using SPSS 21 software. "Chi square" test was used to analyze the relationships between variables ( $P < 0.05$  was considered significant).

**Results:** Our results show that Lupus –independent of any other microvascular risk factor can significantly affect the morphology and structure of blood circulation and these changes are shown with detail by nail fold capillaroscopy.

**Conclusion:** Most of the findings are in line with similar studies performed by other investigators in this field. However, no specific pattern was recognized and microbleeding was higher in our patients with scleroderma-like pattern of involvement.

**Keywords:** Nailfold Video Capillaroscopy (NVC), Systemic Lupus Erythematosus (SLE), Systemic Sclerosis

\*Corresponding Author: Pooneh Dehghan, MD; Address: Northern Chamran Highway; Yaman Street; Next to Shahid Beheshti University of Medical Sciences; Taleghani Hospital Research Development Center; Department of Imaging; Tehran, Iran. Email: p.dehghan@sbmu.ac.ir & poonehdehghan@yahoo.com

Please cite this article as: Rajaei AR, Dehghan P, Ariannia S. Nail fold Capillaroscopic Findings in Iranian Patients with Systemic Lupus Erythematosus. *Novel Biomed*. 2016;4(4):166-72.

## Introduction

Systemic Lupus Erythematosus (SLE) is a progressive autoimmune disease with a wide range of clinical and immunological disorders. Vascular

endothelial damage accompanied by systemic vascular inflammation lead to vascular and internal organ dysfunction<sup>1</sup>. Morphological and functional changes in microscopic examination of small blood vessels have been reported following by ischemic vascular response<sup>2,3</sup>. Therefore, identification of vascular

manifestations at early stage plays an essential role in the diagnosis of its' vascular complications<sup>1</sup>.

Nailfold Video Capillaroscopy (NVC) is a non-invasive, easy, painless and accurate method for evaluation of the capillaries and examination of small vessel abnormalities in rheumatic diseases, especially in patients with Raynaud's phenomenon and systemic sclerosis<sup>3,4</sup>.

Microvascular dysfunction has been reported in Systemic Lupus Erythematosus<sup>6,7</sup>. In addition, it seems that changes in nailfold capillaroscopy are related to disease activity and the presence of specific antibodies<sup>5,8</sup>. Capillaroscopic pattern evaluation is not executed based on a single parameter, but based on a general pattern of numerical and morphological features such as capillary diameter, width, length, shape, distribution, average capillary density, avascular areas, hemorrhages and neo-angiogenesis<sup>4,9</sup>.

The vast majority of capillaroscopic studies in lupus patients have shown that changes are not specific in SLE and are more likely to overlap with other diseases<sup>10-12</sup>. Since most NVC investigations have been performed on Systemic Sclerosis patients, studies have reported typical changes in Scleroderma in 2 to 9% of patients<sup>13,14</sup> and these changes comprise a specific category in reporting the results of NVC.

No specific changes have been described in the capillaroscopic studies of SLE patients. Therefore, it was decided to study these findings and evaluate morphological changes and capillary structure in terms of quality and quantity in this population.

## Methods

In this study, NVC findings of 114 patients diagnosed with SLE for at least one year (according to ACR criteria) were studied. All patients had specific indications for performing the study like acrocyanosis, Reynaud's phenomenon or other manifestations of microvascular insufficiency. The data were collected from patients who were referred to Resselat Capillaroscopy Center from October 2011 to October 2014.

Patients were 19-75 years old with the following exclusion criteria: any evidence of coronary disease or other vascular disorders, high blood pressure, diabetes, hepatitis, other collagen vascular diseases,

dermatologic diseases, smoking, infection and drug use.

Capillaroscopy was performed under standard conditions in all patients (refraining caffeine and smoking for 12 hours prior to the exam; performing the test between 9 AM. to 12 midday; adaptation to ambient temperature -22 to 25 degrees Celsius- by staying in the room for 15 minutes before the study). Afterwards, nail fold capillaroscopy was done using the video capillaroscope (D1 videocap, Vedica, SRL, DC, Milan, Italy, 2011). All nail folds were examined for each patient.

For each image, capillaroscopic parameters that were reported by an experienced rheumatologist with at least 8 years of experience were: microvascular architecture, capillary distribution, morphology with numbers, capillary density, efferent/ afferent limb ratio, sub-papillary venular plexus according to the Wertheimer criteria (Modified by Terry et al.), morphological abnormalities of thick capillaries, Raynaud loops and mega-vessels.

The results were categorized as: 1) normal, 2) non-specific morphological abnormalities, and 3) scleroderma-like pattern.

Participants were divided into two groups based on a study by Cutolo et al.<sup>15-17</sup>:

- Patients with two or more abnormal morphological parameters (in at least two nails) were placed in the scleroderma group.

- Participants with a homogeneous distribution of hairpin-shaped capillaries with capillary density of 9 to 14 per mm or existence of only one parameter of non-specific morphological abnormalities were considered as the normal capillaroscopy pattern.

Capillaroscopy findings of all patients were analyzed qualitatively and quantitatively using SPSS 21 software. "Chi square" test was used to analyze the relationships between variables ( $P < 0.05$  was considered significant).

This study was approved by the ethics and research committee of the hospital.

## Results

The average age of participants in this study was  $20.12 \pm 33.41$ , where 102 (89.4%) were female and 12 (10.5%) male. Capillaroscopic findings are shown in Table 1. As is shown in the table, sub-papillary

venular plexus was visible in all cases. Efferent/afferent limb ratio and capillary density were normal in almost all cases. Microvascular architectural distortion was the most frequent abnormality in this study (Table 1).

Varying degrees of morphologic abnormalities were visible in all cases as shown in Figure 1; most remarkably, capillary tortuosity in most subjects (113 case) and angiogenic expression in 89 cases.

Early scleroderma pattern was observed in 46 cases (40.3%) and normal pattern in 68 (59.6%).

Forty two of the 46 patients with scleroderma pattern were female. Tortuous capillaries, isolated and

altered micro vascular architecture and abnormal capillary morphology were more common in lupus patients with scleroderma facade than in patients with normal pattern (P<0.05). Also, in morphological abnormalities, angiogenesis, isolated enlarged loop, neo capillary formation, irregular enlarged loop, architectural derangement and micro bleeding were more common in lupus patients with scleroderma facade compared to patients with normal pattern (P<0.05). The complete details are shown in Tables 2 and 3.

However, there was no difference in the average age of patients with scleroderma pattern compared to the

**Table 1:** Capillaroscopic Findings.

Variables		Total (%) 114
Microvascular Architecture	Normal	96 (84.2)
	Abnormal	18 (15.7)
Capillary Distribution	Regular	109 (95.6)
	Irregular	5 (4.38)
Capillary Morphology	Homogeneous	107 (93.8)
	Nonhomogeneous	7 (6.1)
Capillary Density	Normal	112 (98.2)
	Decreased	2 (1.7)
Subpapillary Venular Plexus	Visible	114 (100)
	Invisible	0
Efferent/Afferent Ratio	Normal	112 (98.2)
	Increased	2 (1.7)

irregular enlarged loops, angiogenesis and altered microvascular architecture were among the most common morphological abnormalities in Lupus patients with scleroderma facade. Based on P-values,

normal pattern. Also, no relationship was found between different patterns of involvement (normal or scleroderma pattern) and participants' gender (P=0.759).

**Table 2:** Comparison of capillaroscopic variables in SLE patients with normal and scleroderma pattern.

		Normal pattern n (%)	Scleroderma pattern n (%)	P-value
Microvascular Architecture	Normal	63 (92.6)	33 (71.7)	0.003
	Abnormal	5 (7.3)	13 (28.2)	
Capillary Distribution	Regular	68 (100)	41 (89.1)	0.009
	Irregular	0	5 (10.8)	
Capillary Morphology	Homogeneous	68 (100)	39 (84.7)	0.001
	Nonhomogeneous	0	7 (15.2)	
Capillary Density	Normal	68 (100)	44 (95.6)	0.161
	Decreased	0	2 (4.3)	
Efferent/Afferent limb Ratio	Normal	68 (100)	44 (95.6)	0.161
	Increased	0	2 (4.3)	
Gender	Male	8 (11.7)	4 (8.6)	0.759
	Female	60 (88.2)	42 (91.3)	

**Table 3:** Comparison of architectural abnormalities in SLE patients with normal and scleroderma pattern.

Architectural Abnormality		Normal Pattern N (%)	Scleroderma Pattern N (%)	P-Value
Angiogenesis	Yes	48 (70.5)	41 (89.1)	0.022
	No	20 (29.4)	5 (10.8)	
Tortuosity	Yes	68 (100)	45 (97.8)	0.404
	No	0 (0)	1 (2.1)	
Isolated enlarged loop	Yes	5 (7.3)	17 (36.9)	0.000
	No	63 (92.6)	29 (63.04)	
Isolated Microbleeding	Yes	1 (1.4)	4 (8.6)	0.156
	No	67 (98.5)	42 (91.3)	
Capillary Neoformation	Yes	0 (0)	0 (0)	0.039
	No	68 (100)	46 (100)	
Irregular enlarged loop	Yes	1 (1.4)	20 (43.4)	0.000
	No	67 (98.5)	26 (56.5)	
Architectural Derangement	Yes	0 (0)	0 (0)	0.039
	No	68 (100)	46 (100)	
Microbleeding	Yes	0 (0)	0 (0)	0.039
	No	68 (100)	46 (100)	
Avascular Area	Yes	1 (1.4)	0 (0)	1.00
	No	67 (98.5)	46 (100)	
Megacapillary	Yes	0 (0)	1 (2.1)	0.404
	No	68 (100)	45 (97.8)	

**Table 4:** Comparison of microvascular abnormalities between genders.

Variables	Male (%)	Female (%)	P-Value
Altered Microvascular Architecture	3.8	6.16	0.270
Nonhomogeneous capillary distribution	0	0	-
Nonhomogeneous capillary morphology	0	0	-
Reduced capillary density	0	9.1	0.794
Increased Efferent/Afferent limb ratio	0	9.1	0.794
Angiogenesis	3.83	4.77	0.773
Tortuosity	100	99	1.00
Isolated Enlarged loop	25	6.18	0.493
Isolated Microbleeding	0	9.4	0.950
Capillary Neoformation	0	0	-
Irregular Enlarged loop	0	5.2	0.00
Architectural Derangement	0	0	-
Microbleeding	0	0	-
Avascular area	0	0.9	1.00
Mega capillary	0	0.9	1.00

Table 4 compares all micro vascular findings between men and women. Statistical analysis shows significant differences in the irregular enlarged loop between the two groups ( $P < 0.05$ ).

## Discussion

Various forms of vascular disorders are described in capillaroscopic studies of lupus patients. Most studies have described long capillary arches and major capillary network<sup>18,19</sup>.

In morphological studies, long capillary arches have been shown as a characteristic of lupus<sup>20</sup>. While the

scleroderma-like capillaroscopy pattern was shown in 2 to 9% of lupus patients, it seems that this pattern is related to findings such as Raynaud, anti-cardiolipin and anti U1RNP<sup>10-12</sup>.

Other studies have shown the relationship between vascular density and pulmonary gas transfer in lupus patients. Poor gas transfer and alveolar capillary loss in lupus patients may be reflected to the density of vessels in capillaroscopy and may be an important indicator of alveolar capillary density<sup>21</sup>.

In 2005, Ricciari and colleagues conducted a study of capillaroscopic findings on 44 patients with lupus. Fifteen patients (34%) showed Raynaud's phenomenon

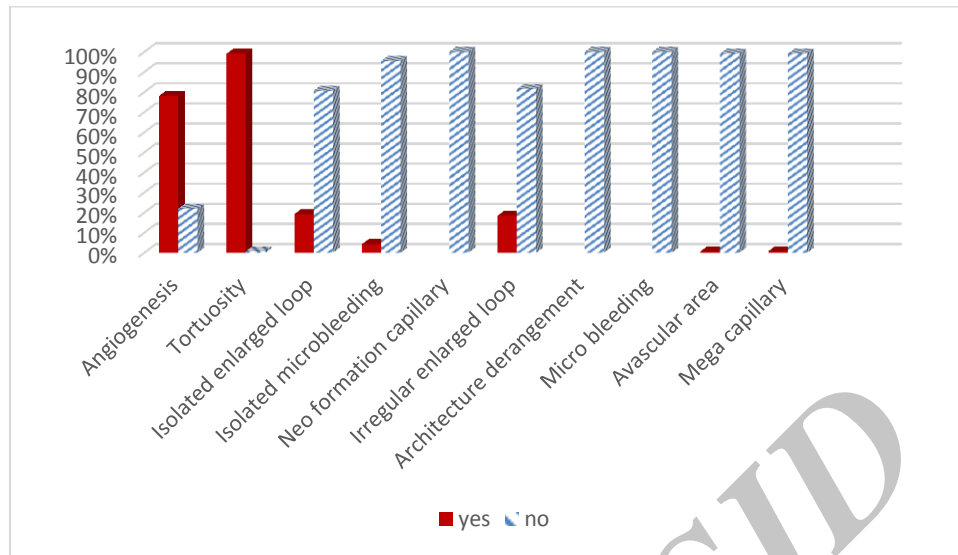


Figure 1. Morphological abnormalities shown in capillaroscopy of SLE patients.

and 9 of them (20%) showed related capillaroscopic changes. Also, 3 patients (8.6%) had capillary loss (avascular areas), 18 patients (41%) had capillary length changes, 16 patients (5.36%) had shorter and 2 (5.4%) longer capillaries. Twenty-six patients (59%) showed capillary tortuosity and architectural derangement was observed in 6 patients (14%) while micro hemorrhage was observed in 4 patients. Capillaroscopic score of over 1 was related to disease activity ( $P=0.01$ ), the existence of anti-cardiolipin ( $P<0.04$ ) and anti SM ( $P<0.04$ ) and high titer AntidsDNA ( $P<0.001$ ) (8).

In a study by Kuryliszyn-Moskal and colleagues (2009), assessing the accompaniment of capillaroscopic changes with markers of endothelial cell and disease (SLE) activity; they showed nail fold disorders to be present in 74 of 90 patients (92.5%) with lupus. Normal pattern or slight changes were observed in 33 patients (41.2%) and moderate to severe changes in 47 patients (58.7%). Capillaroscopic score  $>1$  was repeatedly related to internal organ involvement ( $P<0.001$ ) and immune suppressive therapies ( $P<0.01$ ) (22). The findings show the usefulness of capillaroscopy as a noninvasive method to assess microvascular disorders in Systemic Lupus Erythematosus.

They also conducted a study in 2007 on 47 patients with lupus, and showed morphological changes by capillaroscopy in 45 patients (7.95%). Minor changes

were observed in 16 (34%), moderate in 21 (7.44%) and severe in 8 patients (17%). All patients with systemic involvement showed moderate to severe changes in capillaroscopy. This study showed that capillaroscopy disorders may be a reflection of systemic manifestations and microvascular involvement of lupus<sup>1</sup>.

Leroy Ec and colleagues conducted a study on patients with scleroderma in 2001 and showed that micro vascular derangement in these patients consists of giant capillaries, loss of capillaries and progressive neoangiogenesis<sup>23</sup>.

In a study by M Eredemeier and colleagues which was conducted in 2004 on scleroderma patients, it was shown that capillary loss in NVC correlated with pulmonary hypertension, interstitial lung disease (ILD), peripheral vascular disorders and their severity also cardiopulmonary involvement<sup>24</sup>.

Sambataro and his colleagues carried out a study (2014) on 107 patients with scleroderma assessing the number of micro hemorrhages (MHE), micro thrombosis (MT), giant capillaries (GC) and dilated capillaries. These numbers (micro hemorrhage, micro thrombosis and giant capillaries) were good indicators of disease activity in scleroderma<sup>25</sup>.

In our study of 114 patients with lupus, the normal capillaroscopy pattern was observed in 68 cases (61.59%). Efferent / afferent limb ratio was normal in almost all individuals (Table 1) and high frequency of



capillary tortuosity and angiogenesis was shown similar to the results of Riccieri's study<sup>8</sup>.

Also, 46 patients showed scleroderma pattern of which 42 were female. Tortuous capillaries, angiogenesis, and large irregular capillary arches were among the most common morphological abnormalities in patients with scleroderma-like pattern, as expected. Risary and his colleagues' study had similar results<sup>8</sup>. Leroy and his colleagues study also, shows similar results in patients with scleroderma<sup>23</sup>.

We have also observed that micro bleeding was significantly higher in patients with scleroderma-like pattern.

Ingegnoli et al. reported that reduced capillary density may be identified very soon in patients with scleroderma<sup>4</sup>. This finding is consistent with our results.

## Conclusion

Our study is the largest study performed in this field on SLE patients in Iran. Our results are mostly in line with similar studies performed by other investigators in this field. However, microbleeding is higher in our patients with scleroderma-like pattern of involvement. This finding could be a basis for further investigation, either in Iranian SLE patients or for comparison with patients involved by other connective tissue disorders.

## Acknowledgment

We would like to thank Loghman Hospital, department of Rheumatology for their contribution in this study.

## Conflict of interest

The authors declare no conflicts of interest.

## References

1. Kuryliszyn A, Kliminuk P, Seirakowski S, Ciotkiowicz M. vascular endothelial growth factor in systemic lupus erythematosus: relationship to disease activity, systemic organ manifestation, and nailfold capillaroscopic abnormalities. *Arch Immunol Ther.* 2006;55:179-85
2. Tibirićá E, Rodrigues E, Cobas RA, Gomes MB. Endothelial Function in Patients with Type 1 Diabetes Evaluated by Skin Pillary Recruitment. *Microvascular Research.* 2007;73:107-12.

3. Kuryliszyn-Moskal A, Dubicki A, Zarzycki W, Zonnenberg A, Gorska M. Microvascular Abnormalities in Capillaroscopy Correlate with Higher Serum IL-18 and sE-Selectin Levels in Patients with Type 1 Diabetes Complicated by Microangiopathy. *Folia histochemica et Cytobiologica/Polish Academy of Sciences. Polish Histochemical and Cytochemical Society.* 2011;49:104-10.
4. Ingegnoli F, Gualtierotti R, Lubatti C, Bertolazzi C, Gutierrez M, Boracchi P, et al. Nailfold Capillary Patterns in Healthy Subjects: A Real Issue in Capillaroscopy. *Microvascular Research.* 2013;90:90-5.
5. Kaminska-Winciorek G, Deja G, Polanska J, Jarosz-Chobot P. Diabetic Microangiopathy in Capillaroscopic Examination of Juveniles with Diabetes Type 1. *Postepy Higieny Medycyny Doswiadczalnej.* 2012;66:51-9.
6. Bounameaux H, Miescher A, De Moerloose P. Association of anti cardiolipin antibodies and abnormal nailfold capillaroscopy in patients with systemic lupus erythematosus. *Lupus.* 1995 4. 142-144.
7. Lee P, Leung FY, Alderdice C, Armstrong SK. Nailfold capillary Microscopy in the connective tissue diseases: a semiquantitative assessment. *J Rheumatology.* 1983;10:930-8.
8. Riccieri V, Spadaro A, Cecarelli F, Scrivo R, Germano V, Valesini G. Nailfold capillaroscopy changes in systemic lupus erythematosus: correlations with disease activity and autoantibody Profile. *Lupus.* 2005;14:521-5.
9. Lambova SN, Hermann W, Muller-Ladner U. Comparison of Qualitative and Quantitative Analysis of Capillaroscopic Findings in Patients with Rheumatic Diseases. *Rheumatology International.* 2012;32:729-35.
10. Studer A, Hunziker T, Lutolfo, Schmid J, Chen D, Mahler F. quantitative nailfold capillary microscopy in cutaneous and systemic lupus erythematosus and localized and systemic scleroderma. *J An Acad Dermatol.* 1991;24:941-5.
11. Bongard O, Bounameaux H, Miescher PA, De Moerloose P. Association of anticardiolipin antibodies and abnormal nailfold capillaroscopy inpatients with systematic lupus erythematosus. *Lupus.* 1995;4:142-4.
12. Furtado RNV, Pucinelli MLc, Cristo VV, Andrade LEC, Sato El. Scleroderma – like nailfold capillaroscopic abnormalities are associated with anti – U1 – RNP antibodies and Raynaud's phenomenon In SLE patients. *Lupus.* 2002;11:35-41.
13. Maricq HR, Leroy EC, D'Angelo WA, et al. Diagnostic potential of in vivo capillary microscopy in scleroderma and related disorders. *Arthritis Rheum* 1980; 23: 183-188.
14. Kabasakal Y, Eluins Dm, Ring EFJ, Mc Hugh NJ. Quantitative nailfold capillaroscopy finding in a population whit connective tissue disease and in normal health controls. *Ann Rheum Dis.* 1996;55:507-12.
15. Cutolo M, Pizzorni C, Tuccio M, Burrioni A, Craviotto C, Basso M, et al. Nailfold Videocapillaroscopic Patterns and Serum Autoantibodies in Systemic Sclerosis. *Rheumatology (Oxford).* 2004;43:719-26.
16. Cutolo M. Atlas of Capillaroscopy. Walter Grassi, Patrizia Del Medico. 2004.
17. Cutolo M, Sulli A, Vanessa S. How to Perform and Interpret Capillaroscopy. *Best Practice & Research Clinical Rheumatology.* 2013;27:237-48.
18. Redish W, Messina EJ, Hughes G, McEwen C. Capillaroscopic observations in rheumatic diseases. *Ann Rheum Dis.* 1970;29:244-53
19. Lee p, leung FYK, Alderdice C, Armstrong SK. Nailfold capillary microscopy in mixed connective tissue diseases: a semiquantitative assessment . *J Rheumatology.* 1983;10:930-8
20. Granier F, Vayssairat M, Priollet P, Housset E. Nailfold capillary microscopy in mixed connective tissue disease. *Arthritis Rheum.* 1986;29:189-95
21. Pallis M, Hapkinson N, Pawell R. Nailfold capillary density as a possible indicator of pulmonary capillary loss in systemic lupus erythematosus but not in mixed connective tissue disease. *J Rheumatol.* 1991;18:1532-6

22. Kurylczyn A. Clinical significance of nailfold capillaroscopy in systemic lupus erythematosus: correlation with endothelial cell activation markers and disease activity. *Scand J Rheumatol.* 2009;38(1):38-45.

23. Leroy Ec, Medsger TAJr. Criteria for the classification of early systemic sclerosis. *J Rheumatol.* 2001;18:1273-6.

24. Eredemier M, Xavier RM, capobianco KG, et al. Nailfold

capillary microscopy can suggest pulmonary disease activity in systemic sclerosis. *J Rheumatol.* 2004;31:286-94.

25. Sambataro E. Nailfold Videocapillaroscopy micro – hemorrhage and giant capillary counting as an accurate approach for a steady state definition of disease activity in systemic sclerosis, *arthritis Research Therapy.* 2014;16:462.

Archive of SID



# SID



سرویس های ویژه



سرویس ترجمه تخصصی



کارگاه های آموزشی



بلاگ مرکز اطلاعات علمی



عضویت در خبرنامه



فیلم های آموزشی

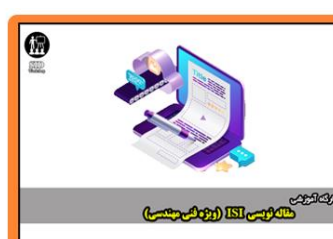## کارگاه های آموزشی مرکز اطلاعات علمی جهاد دانشگاهی



کارگاه آنلاین آشنایی با پایگاه های اطلاعات علمی بین المللی و ترند های جستجو



مباحث پیشرفته یادگیری عمیق؛ شبکه های توجه گرافی (Graph Attention Networks)



کارگاه آنلاین مقاله نویسی IEEE و ISI ویژه فنی و مهندسی