



## Brain Infarction: Rare Neurological Presentation of African Bee Stings

Hernando Raphael Alvis- Miranda<sup>1</sup>, Nancy Carolina Duarte-Valdivieso<sup>2</sup>, Gabriel Alcala-Cerra<sup>3</sup>, Luis Rafael Moscote-Salazar<sup>1</sup>

<sup>1</sup>University of Cartagena, Cartagena de Indias, Colombia, South America

<sup>2</sup>Chang Gung Memorial Hospital, Linkou, Taiwan

<sup>3</sup>University of Cartagena, Cartagena de Indias, Colombia, South America

**Corresponding author:** Luis Rafael Moscote-Salazar

Address: University of Cartagena, Cartagena de Indias, Colombia, South America.  
e-mail: mineurocirujano@aol.com

Received: November 20, 2013

Revised: December 12, 2013

Accepted: December 24, 2013

### ▶ ABSTRACT

Bee stings are commonly encountered worldwide. Various manifestations after bee sting have been described including local reactions which are common, systemic responses such as anaphylaxis, diffuse intravascular coagulation and hemolysis. We report a case of a 74-year-old man who developed neurologic deficit 5 hours after bee stings, which was confirmed to be left frontal infarction on brain CT-scan. The case does not follow the reported pattern of hypovolemic or anaphylactic shock, hemolysis and/or rhabdomyolysis, despite the potentially lethal amount of venom injected. Diverse mechanisms have been proposed to give an explanation to all the clinical manifestation of both toxic and allergic reactions secondary to bee stings. Currently, the most accepted one state that victims can develop severe syndrome characterized by the release of a large amount of cytokines.

**Keywords:** Bee stings; Stroke; Rhabdomyolysis; Shock.

Please cite this paper as:

Alvis-Miranda HR, Duarte-Valdivieso NC, Alcala-Cerra G, Moscote-Salazar LR. Brain Infarction: Rare Neurological Presentation of African Bee Stings. *Bull Emerg Trauma*. 2014;2(1):59-61.

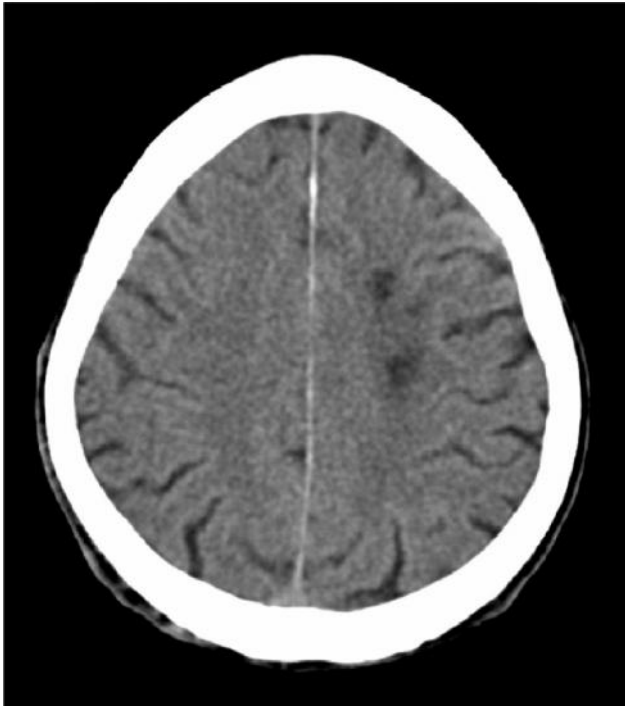
### Introduction

Africanized honey bees, known colloquially as "killer bees", are some hybrid varieties of the Western honey bee species (*Apis mellifera*) and are particularly aggressive. They have been imported from tropical zones in America where a large number of deaths have been reported [1]. Bee stings are commonly encountered worldwide. Various manifestations after bee sting have been described. Local reactions are common. Unusually, manifestations like vomiting, diarrhea, dyspnea, generalized edema, acute renal failure, hypotension and collapse may occur. Rarely vasculitis, serum sickness, neuritis and encephalitis have been described which generally develop days to weeks after a sting [2]. We report a case of a 74-year-

old man who developed neurologic deficit 5 hours after bee stings, which was confirmed to be left frontal infarction on brain CT-scan.

### Case Report

A 74-year-old male patient, with previous history of arterial hypertension; since a week, in the early morning, the patient was stung by Africanized race bees, up to 200, during roof cleaning, in a rural area of the Colombo-Venezuelan frontier. 5 hours later, the patient posteriorly experienced general malaise, and paresthesia of the right hand with language alteration during 5 minutes. After that time, the patient recovered completely and called for help to his physician, who prescribed paracetamol and rest. Two days after, the



**Fig. 1.** Brain CT-scan showing left frontal hypodensity suggestive of brain regional infarction.

patient experienced sudden right hemiparesia with inability to speak and comprehend. In the physical examination in the emergency department, relevant data obtained were: blood pressure: 150/100mmHg, cardiac sounds were rhythmic without murmurs, and lung fields were clear. Murmur in the left common carotid artery. In the neurological examination, the patient was alert with global aphasia (sensitive-motor), facial paralysis of the right lower quadrant. Paresis of in the right superior (2/5) and inferior (4/5) limbs with hyperactive reflexes, with ipsilateral pathological reflexes such as Hoffman's, Trommer's and Babinski's, plus right hemicorporal hypoesthesia. Coordination and gait could not be evaluated. The brain CT-scan (Figure 1) showed left frontal hypodensity suggestive of brain regional infarction. The patient was managed during hospitalization with intravenous fluid replacement and corticoids. Due to satisfactory evolution the patient was discharged 10 days after. The outpatient controls had evidenced positive evolution of the right hemiparesis and hypoesthesia.

### Discussion

In 1956, Africanized bees began to spread in the American continent from southern Brazil, where original African bees mated with European bees [3]. The presence of Africanized bees had produced positive effects on south-american economy, negative impacts-such as swarming, aggressive behavior, and the ability to mass attack-resulting in serious and fatal envenomation with humans and animals, can also be

produced [3].

Diverse mechanisms have been proposed to give an explanation to all the clinical manifestation of both toxic and allergic reactions secondary to bee stings. Currently, the most accepted one state that victims can develop severe envenomation syndrome characterized by the release of a large amount of cytokines, mainly interleukins (IL), e.g., IL-1, IL-6, IL-8, and tumor necrosis factor (TNF); which subsequently, lead to acute inflammatory response triggering adverse effects on skeletal muscles; bone marrow; hepatic and renal functions; and cardiovascular, central nervous, and immune systems.

The main clinical manifestations of bee venom poisoning are local allergic reactions at the site of the sting such as edema, erythema, and burn-like sensation and generalized reactions that include pruritus, urticarial, angioedema, and, in extreme cases, anaphylactic shock. Systemic toxic reactions due to venom compounds are observed usually after 50 to 100 bee bites [1]. Although adults can tolerate more than 1000 bee bites, sensitive individuals may develop mortal anaphylactic reaction after one.

Sometimes life-threatening allergic reactions can occur due to bee stings, being the most important one the anaphylaxis. The incidence of anaphylaxis due to bee sting ranges between 0.4% and 5%. With high mortality rate associated with severe allergic reactions mainly before the age of 20 years and being twice common in male population [4].

Some unusual neurologic complications such as myasthenia gravis, peripheral neuritis, encephalomyelitis, optic neuritis, cerebral infarction, parkinsonism, trigeminal neuralgia, pontine hematoma, and thalamic and mesencephalic hemorrhages as well as the Guillain-Barré syndrome can also be related to bee stings [5].

We describe a case of multiple African bee stings in which the exceptionally high dose suggests a direct effect of hymenoptera venom on brain vessels. The case does not follow the reported pattern of hypovolemic or anaphylactic shock, hemolysis and/or rhabdomyolysis, despite the potentially lethal amount of venom injected. Diverse authors have reported similar neurological alterations. Rajendiran *et al.* reported a case of a 25-year-old male who developed left sided monoparesis and transient visual loss following multiple bee stings, with evidence supporting involvement of both the anterior circulation and posterior circulation territory to the brain, in our case the was involvement of the anterior left circulation [6]. Bilir *et al.* reported a case of a 35-year-old man who developed neurologic deficit 6 hours after a bee sting, which was confirmed to be left parietooccipital infarction on magnetic resonance

imaging scan [1]. Dikici *et al.*, [5] reported the case of a 49-year-old male patient presenting generalized tonic clonic seizure and loss of consciousness after an hour of wild bee bite from the anterior abdomen in a rural area. The cranial computed tomography taken in the emergency department was normal; control cranial computed tomography at the 36th hour after admission was consisted with subarachnoid hemorrhage (SAH). The patient was diagnosed as SAH due to exposure to bee stings. The patient was treated for a month in an intensive care unit and discharged in a vegetative state

Treatment in these circumstances implies limiting the inflammatory cascade triggered by bee stings and the management of secondary organ injuries, i.e., intracranial hemorrhage, stroke, acute myocardial

infarction, among others. Thus recurring to corticoids, antihistaminic drugs are useful in diminishing local and systemic allergic reactions, and for organ injuries, should be applied a rationale treatment approach. In the case of severe complications such as brain ischemia/infarction or hemorrhage, rapid recognition and collaboration with experienced clinicians is the best way to facilitate specialized treatment protocols. In conclusion, the exact mechanism that drives to brain ischemia are not fully comprehended, thus further studies are needed to elucidate the pathogenetic mechanism involved and to prevent organ damage as there is no complete cure for stroke [7].

**Conflict of Interest:** None declared.

## References

1. Bourgain C, Pauti MD, Fillastre JP, Godin M, François A, Leroy JP, et al. Massive poisoning by African bee stings. *Presse Med* 1998;**27**(22):1099-101.
2. Bilir O, Ersunan G, Kalkan A, Ozmen T, Yigit Y. A different reason for cerebrovascular disease. *Am J Emerg Med* 2013;**31**(5):891.e5-6.
3. Ferreira RS Jr, Almeida RA, Barraviera SR, Barraviera B. Historical perspective and human consequences of Africanized bee stings in the Americas. *J Toxicol Environ Health B Crit Rev* 2012;**15**(2):97-108.
4. Kalyoncu AF, Demir AU, Ozcan U, Ozkuyumcu C, Sahin AA, Bari YI. Bee and wasp venom allergy in Turkey. *Ann Allergy Asthma Immunol* 1997;**78**(4):408-12.
5. Dikici S, Aydin LY, Saritas A, Kudas O, Kandis H. An unusual presentation of bee sting: subarachnoid hemorrhagia. *Am J Emerg Med* 2012;**30**(8):1663.e5-6.
6. Rajendiran C, Puvanalingam A, Thangam D, Ragunathanan S, Ramesh D, Venkatesan S, et al. Stroke after multiple bee sting. *J Assoc Physicians India* 2012;**60**:122-4.
7. Jain J, Banait S, Srivastava AK, Lodhe R. Stroke intracerebral multiple infarcts: Rare neurological presentation of honey bee bite. *Ann Indian Acad Neurol* 2012;**15**(2):163-6.

Surf and download all data from SID.ir: [www.SID.ir](http://www.SID.ir)

Translate via STRS.ir: [www.STRS.ir](http://www.STRS.ir)

Follow our scientific posts via our Blog: [www.sid.ir/blog](http://www.sid.ir/blog)

Use our educational service (Courses, Workshops, Videos and etc.) via Workshop: [www.sid.ir/workshop](http://www.sid.ir/workshop)