



## Asymptomatic Tuberculosis-Induced Ileal Perforation in an HIV-Infected Individual; A Case Report

Sedigheh Tahmasebi<sup>1</sup>, Sam Moslemi<sup>1</sup>, Maryam Tahamtan<sup>2\*</sup>, Lohrasb Taheri<sup>1</sup>, Mohammad Ali Davarpanah<sup>2</sup>

<sup>1</sup>Department of General Surgery, Shiraz University of Medical Sciences, Shiraz, Iran

<sup>2</sup>Department of Internal Medicine, School of Medicine, Shiraz University of Medical Sciences, Shiraz, Iran

**Corresponding author:** Sam Moslemi

Address: Department of General Surgery, Faghihi Hospital, Shiraz University of Medical Sciences, Shiraz, Iran.

e-mail: moslemis@sums.ac.ir

Received: September 5, 2013

Accepted: September 29, 2013

### ► ABSTRACT

The co-existence of acquired immune deficiency syndrome (AIDS) and tuberculosis is a major cause of morbidity and mortality because of a widespread organ involvement. The gastrointestinal tract is a common site for localization of opportunistic microorganisms in AIDS. However, surgical abdominal emergencies such as intestinal perforation resulted from tuberculosis are uncommon in these patients. The asymptomatic occurrence of such intestinal perforation has not been reported our knowledge. We represent an HIV and HCV co-infected man with miliary tuberculosis and an incidentally detected free air under diaphragm in the chest X-ray eventually resulting in exploratory laparotomy which then revealed two tubercular-induced intestinal perforations. It seems that as the tuberculosis is increasing in incidence, mostly due to reactivation in HIV-infected patients especially in developing countries, we should not underestimate its acute abdominal emergencies such as bowel perforation.

**Keywords:** Tuberculosis; Intestinal perforation; Human Immunodeficiency Virus (HIV); Acquired Immune Deficiency Syndrome (AIDS).

Please cite this paper as:

Tahmasebi S, Moslemi S, Tahamtan M, Taheri L, Davarpanah MA. Asymptomatic Tuberculosis-Induced Ileal Perforation in an HIV-Infected Individual; A Case Report. *Bull Emerg Trauma*. 2013;1(4):182-185.

### Introduction

Tuberculosis has various presentations which should not be underestimated. Since the advent of human immunodeficiency virus (HIV), the incidence of disease is increasing more and more [1,2]. Although gastrointestinal involvement is common in HIV-infected patients, intestinal perforation is very rare and it is mostly due to opportunistic infections or malignancies [3]. Where the etiology of intestinal perforation is tuberculosis, it is considered extremely rare [4]. To our knowledge, the cases reported in the literature as very rare victims of tuberculosis-induced intestinal perforation have been all symptomatic.

Here, we represent a 62 year-old man with AIDS and a new presentation of intestinal perforation caused by tuberculosis.

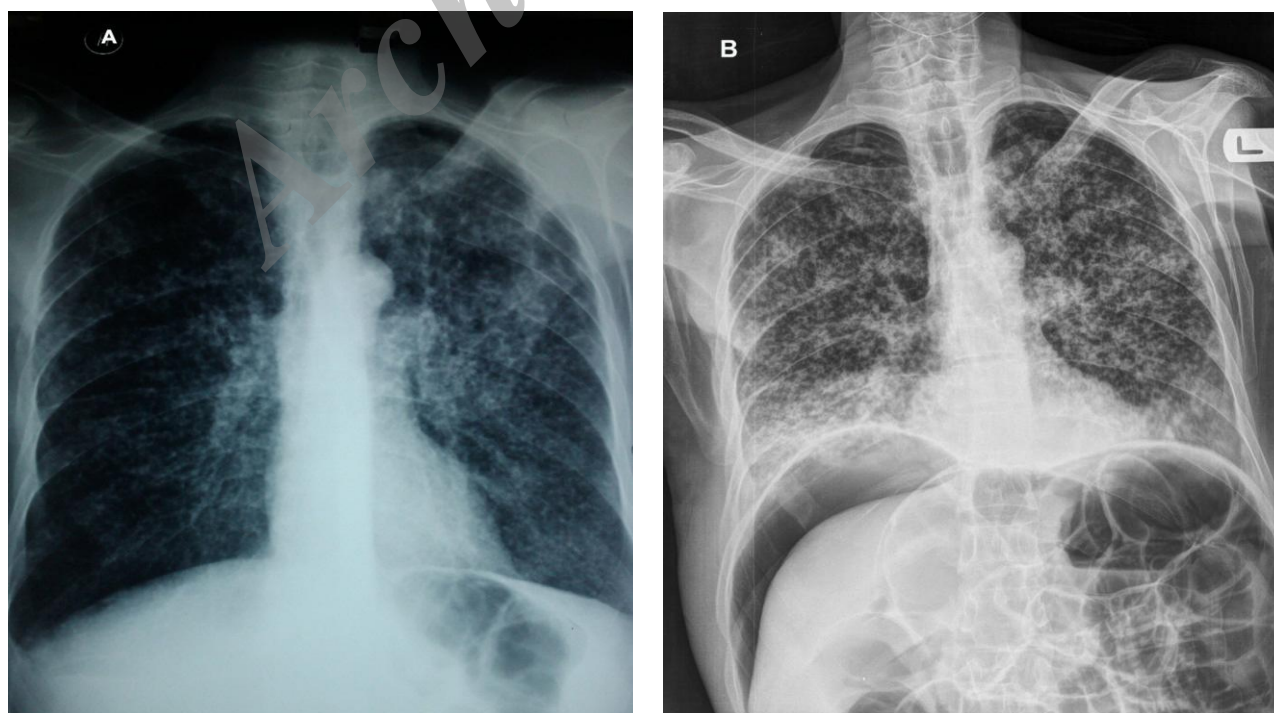
### Case report

A 62-year-old prisoner man was referred to our center with a one month history of anorexia, fatigue, 12 pounds weight loss and intermittent fever accompanied by occasional episodes of productive cough and mild dyspnea since one week prior to admission. He was a 13 pack-year cigarette smoker with a history of opium addiction and crystal abuse for 20 years and 6 months respectively. Reviewing

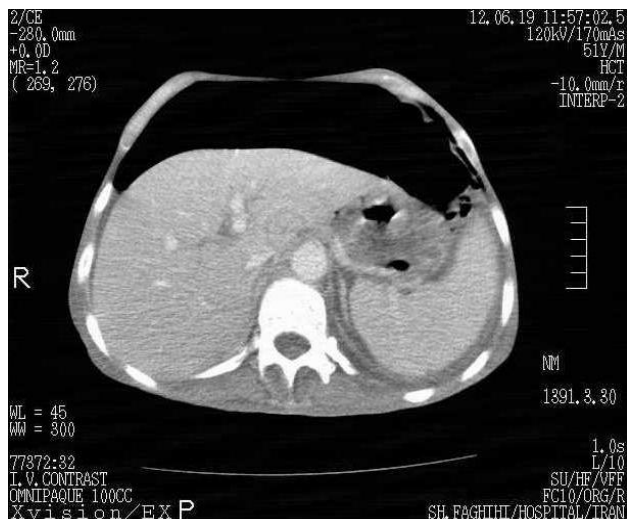**Table 1.** The characteristics of tuberculosis-induced bowel perforations previously reported in the literature

Author	No. of cases	Site of perforation	Nature of perforation	HIV association
Muquit S <i>et al.</i>	1	small intestine	single	
Acer T <i>et al.</i>	1	jejunum	multiple	
Friedenberg KA <i>et al.</i>	2	small intestine	multiple	x
Senise JF <i>et al.</i>	2	ileum	single	x
Doré P <i>et al.</i>	2	small and large intestine	single	
Midiri G <i>et al.</i> , [10]	1	small and large intestine	multiple	x
Grinev MV <i>et al.</i> , [11]	5	jejunum: 1 ileum: 4	single/multiple	
Rondelli F <i>et al.</i> , [12]	1	small intestine	multiple	
Mogoş D <i>et al.</i> , [13]	2	small intestine	single	
Uraniş S [14]	1	small intestine	single	
Mert A <i>et al.</i> , [15]	1	small intestine	Single	
Agrawal RL <i>et al.</i> , [9]	1	small intestine	multiple	
Kapan M <i>et al.</i> , [16]	1	small intestine	multiple	
McElvanna K <i>et al.</i> , [17]	1	small intestine	multiple	
Deb T <i>et al.</i> , [18]	1	ileum	multiple	
Jayaswal <i>et al.</i> , [19]	1	small intestine	recurrent	
Dogo D <i>et al.</i> , [20]	1	ileum	single	x
Sweetman WR <i>et al.</i> , [21]	1	small intestine	single	
Târcoveanu E <i>et al.</i> , [22]	2	small intestine	single	

his past medical and family histories revealed no significant findings. In the physical examination, we were confronted by an ill-appearing old man with generalized wasting and diffuse petechial spots and a core body temperature of 38.3 °C. His blood pressure, heart rate and respiratory rate were 120/80 mmHg, 90 bpm and 30/min respectively. He had diffuse thrush in oral cavity and two 4×6 and 3×4 crusted ulcers with pussy discharge and an erythematous border surrounding the right anterior axillary line in the midpart. Both lungs had basilar coarse crackles on auscultation and the abdomen was scaphoid

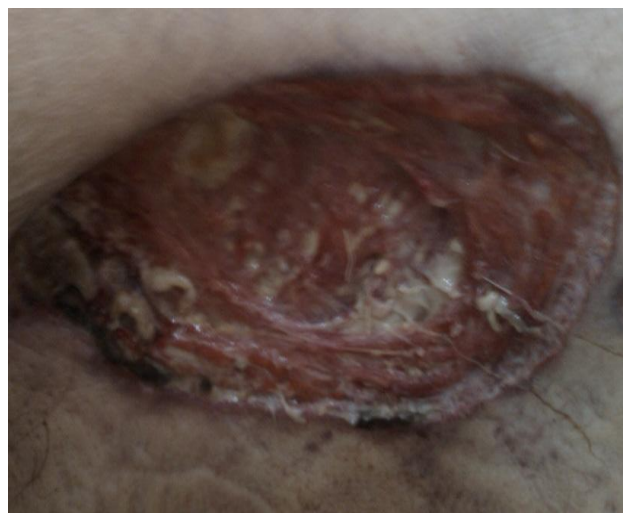

**Fig. 1.** Radiographic findings of chest; **A.** Vague bilateral nodular pattern in the chest X-ray taken one week prior to admission; **B.** Obvious nodular pattern in both lungs and an incidentally detected free air under both hemidiaphragms.



**Fig. 2.** Abdominopelvic computed-tomographic demonstration of pneumoperitoneum.

without obvious tenderness or organomegaly. The CBC showed a pancytopenia with Hb 11 gr/dl, platelet count of 140000/mm<sup>3</sup> and WBC 2800/mm<sup>3</sup> with absolute lymphocyte count (ALC) of 53. The peripheral blood smear confirmed the presence of pancytopenia. The chest X-ray taken a week prior to admission showed a scattered distribution of small-sized nodules throughout both lungs suggesting miliary tuberculosis (Figure 1). Abdominopelvic computed-tomographic (CT) scan demonstrated extensive pneumoperitoneum (Figure 2). Three samples of sputum for acid fast bacilli (*Mycobacterium tuberculosis*) were found positive and a reactive HIV Ab ELISA was noted which was reactive again in repetition and HIV infection was confirmed by a western blot test. We also detected a positive HCV Ab. Biopsy of both skin lesions showed caseating necrosis and positive acid-fast test in favor of tuberculosis. We started a four-drug regimen with Rifampin, Isoniazid, Pyrazinamide and Ethambutol as recommended in the guidelines of our society for treatment of tuberculosis. A broad-spectrum antibiotic therapy was also administered. In the hospital course, we incidentally encountered with a remarkable free air under both hemidiaphragms in the chest X-ray. Undergoing conservative management, three days later, the patient developed mild abdominal distension with moderate amount of ascites demonstrated in the abdominopelvic sonography. An extended free air was also detectable in the radiographs. The patient was immediately taken to operating room for exploratory laparotomy which then revealed two 3 and 1.5 cm perforation of small bowel, 130 and 150 cm distal to Treitz ligament respectively as well as 1400 cc biliary fluid in the abdominal cavity, multiple lymphadenopathies and mesenteric calcification. We repaired both bowel perforations (Figure 3). Despite the success of operation, the patient was confronted



**Fig. 3.** The depth of a skin ulcer after primary debridement

by a respiratory distress two days later and soon underwent mechanical ventilation. However, the patient's condition was deteriorated and he expired 3 days after surgery. The biopsy specimens prepared from edges of perforated sites demonstrated caseating necrosis and acid-fast bacilli suggesting bowel involvement by tuberculosis without any evidence of CMV infection in either pathologic or serologic evaluations.

### Discussion

A remarkable part of gastrointestinal complaints in AIDS is related to opportunistic infections affecting the gastrointestinal (GI) tract. Tuberculosis is a well-known example of these infections in which the entire gastrointestinal tract can be affected. The most common involved anatomic portion of GI tract in tuberculosis is the ileocecal area. When the small intestine is involved in tuberculosis, the symptoms include abdominal pain, nausea/vomiting and weight loss. Apart from this chronic form, abdominal tuberculosis may present with acute surgical emergencies such as obstruction and perforation [3,5].

Cytomegalovirus is considered as the main cause of intestinal perforation in patients suffering from AIDS [6]. However, it is mostly seen in the large bowel between terminal ileum and splenic flexure [7]. Despite the rarity of intestinal perforations caused by tuberculosis in HIV-infected patients, the most common site is the antimesenteric side of terminal ileum [8]. As mentioned in Table 1, there are a few tuberculosis-induced intestinal perforations reported in the literature. Two of the cases were at very young ages: a preterm baby and a 2-year-old child [2,9]. As demonstrated in the Table 1, nine reports (10 cases) were confronted by multiple intestinal perforations. All the six HIV-infected patients reported as cases



of tuberculosis-induced intestinal perforation were symptomatic and developed various degrees of peritoneal signs. However, despite significant amount of ascites and striking amount of free air under diaphragm in our patient, he did not show any signs of peritonism guiding the physician to manage the patient's condition as an urgent acute abdomen. The absence of peritonitis in our case may be due to extremely insidious onset of intestinal perforation, a personal history remarkable for use of different opium derivatives or the failure of a brisk immunologic response in the context of immune deficiency. To defend our hypotheses, we could not find any related subjects in the literature and these three possibilities require further similar case reports to investigate the real fact behind the absence of peritonitis.

The intestinal perforation should be managed surgically via debridement of necrotic tissues and then simple closure followed by a complete irrigation of abdominopelvic cavity. Biopsy specimens should be taken from edges of the perforated site to confirm

the diagnosis. Segmental bowel resection is considered when there are multiple perforations or when we are not certain enough about the viability of bowel segment [2]. The case presented above, underwent simple repair of both perforated sites in the ileum. In the postoperative course, our patient developed respiratory deterioration leading to mechanical ventilatory support. Such this outcome has been mentioned in previous reports [1,11] clarifying the significance of high suspicion of catastrophic forms of abdominal tuberculosis presenting with different atypical symptoms and signs contributing to a misleading dilemma.

In conclusion, it seems that as the tuberculosis is increasing in incidence, mostly due to reactivation in HIV-infected patients especially in developing countries, we should not underestimate its acute abdominal emergencies such as bowel perforation.

**Conflict of Interest:** None declared.

## References

- Muquit S, Shah M, Abayajewa K. A case of miliary tuberculosis presenting with bowel perforation. *Emerg Med J* 2006;**23**(11):e62.
- Acer T, Karnak İ, Ekinçi S, Talim B, Kiper N, Şenocak ME. Multiple jejunoileal perforations because of intestinal involvement of miliary tuberculosis in an infant. *J Pediatr Surg* 2008;**43**(9):e17-21.
- Shiekh RA, Yasmeen S, Prindiville TP, Ruebner BH. Intestinal perforation and peritonitis in AIDS: Case series and review of literature. *JK-Practitioner* 2004;**11**(4):248-56.
- Friedenberg KA, Draguescu JO, Kiyabu M, Valenzuela JE. Intestinal perforation due to Mycobacterium tuberculosis in HIV-infected individuals: report of two cases. *Am J Gastroenterol* 1993;**88**(4):604-7.
- Lazarus AA, Thilagar B. Abdominal tuberculosis. *Dis Mon* 2007;**53**(1):32-8.
- Senise JF, Hamrick PA, Guidugli RB, Ribera JM, Siqueira SA. Ileal loop perforation caused by tuberculosis in patients with the acquired immunodeficiency syndrome. *Rev Paul Med* 1991;**109**(2):61-4.
- Kram HB, Shoemaker WC. Intestinal perforation due to cytomegalovirus infection in patients with AIDS. *Dis Colon Rectum* 1990;**33**(12):1037-40.
- Doré P, Meurice JC, Rouffineau J, Carretier M, Babin P, Barbier J, et al. Intestinal perforation occurring at the beginning of treatment: a severe complication of bacillary tuberculosis. *Rev Pneumol Clin* 1990;**46**(2):49-54.
- Agrawal RL, Rehman H. Congenital miliary tuberculosis with intestinal perforations. *Tuber Lung Dis* 1995;**76**(5):468-9.
- Midiri G, Urbano V, Lombardi A, Covotta A, Tesoriere A, Covotta L, et al. A case of multiple intestinal perforations due to TBC in a female patient with HIV-1 infection. *G Chir* 1993;**14**(4-5):227-30.
- Grinev MV, Skrynnik NA, Shteĩntsaĩg AI. Intestinal perforation in tuberculosis. *Vestn Khir Im II Grek* 1997;**156**(4):46-9.
- Rondelli F, Finocchi L, Covarelli P, Boselli C, Cristofani R, Noya G. Multiple intestinal perforations due to tuberculosis: a case report and review of the literature. *Chir Ital* 2009;**61**(3):397-9.
- Mogoş D, Vasile I, Păun I, Dragomir T. Tuberculous perforation of the small bowel. *Chirurgia (Bucur)* 2000;**95**(4):363-6.
- Uranüs S. A rare cause of small bowel perforation by intestinal and peritoneal tuberculosis. *Z Gastroenterol* 1990;**28**(2):110-2.
- Mert A, Bilir M, Ozaras R, Tabak F, Goksel S, Senturk H. A rare complication of miliary tuberculosis: intestinal perforation. *Acta Chir Belg* 2001;**101**(1):42-5.
- Kapan M, Karabicak I, Aydogan F, Kusaslan R, Kisacik B. Intestinal perforation due to miliary tuberculosis in a patient with Behcet's disease. *Mt Sinai J Med* 2006;**73**(5):825-7.
- McElvanna K, Skelly RT, O'Neill C, Spence GM. Miliary Tuberculosis Causing Multiple Intestinal Perforations in an Immigrant Worker. *Ulster Med J* 2008;**77**(3):206-8.
- Deb T, Singh TY, Singh NB, Sharma MB, Debbarma A. Multiple tubercular ulcer perforation of ileum in an AIDS patient: case report. *J Commun Dis* 1998;**30**(3):175-8.
- Jayaswal R, Jena PK, Gopinathan VP, Chauhan MS. Recurrent acute tuberculous perforations of small intestine associated with miliary tuberculosis of lung. *J Assoc Physicians India* 1986;**34**(11):817-8.
- Dogo D, Bakari AA, Gali BM, Ibrahim AG. Tuberculous ileal perforation in a HIV positive patient: a case report and review of literature. *Niger J Clin Pract* 2008;**11**(4):386-8.
- Sweetman WR, Wise RA. Acute perforated tubercular peritonitis in surgical treatment. *Ann Surg* 1959;**149**(1):143-8.
- Tărcoveanu E, Filip V, Moldovanu R, Dimofte G, Lupaşcu C, Vlad N, et al. Abdominal tuberculosis--a surgical reality. *Chirurgia (Bucur)* 2007;**102**(3):303-8.

Surf and download all data from SID.ir: [www.SID.ir](http://www.SID.ir)

Translate via STRS.ir: [www.STRS.ir](http://www.STRS.ir)

Follow our scientific posts via our Blog: [www.sid.ir/blog](http://www.sid.ir/blog)

Use our educational service (Courses, Workshops, Videos and etc.) via Workshop: [www.sid.ir/workshop](http://www.sid.ir/workshop)