

SID



سرویس های ویژه



سرویس ترجمه تخصصی



کارگاه های آموزشی



بلاگ مرکز اطلاعات علمی



عضویت در خبرنامه



فیلم های آموزشی

کارگاه های آموزشی مرکز اطلاعات علمی جهاد دانشگاهی



کارگاه آنلاین آشنایی با پایگاه های اطلاعات علمی بین المللی و ترند های جستجو



مباحث پیشرفته یادگیری عمیق؛ شبکه های توجه گرافی (Graph Attention Networks)



کارگاه آنلاین مقاله نویسی IEEE و ISI ویژه فنی و مهندسی

ORIGINAL RESEARCH

Ultrasound-Guided Reduction of Distal Radius Fractures

Anita Sabzghabaei¹, Majid Shojaee², Ali Arhami Dolatabadi², Mohammad Manouchehrifar¹, Mahdi Asadi^{2*}

1. Emergency Department, Loghman Hakim Hospital, Shahid Beheshti University of Medical Sciences, Tehran, Iran.

2. Emergency Department, Imam Hossein Hospital, Shahid Beheshti University of Medical Sciences, Tehran, Iran

*Corresponding Author: Mahdi Asadi; Emergency Department, Imam Hossein Hospital, Shahid Madani Avenue, Imam Hossein Square, Tehran, Iran;
Tel: +989124837764; Email: drasadi2014@gmail.com

Received: June 2015; Accepted: August 2015

Abstract

Introduction: Distal radius fractures are a common traumatic injury, particularly in the elderly population. In the present study we examined the effectiveness of ultrasound guidance in the reduction of distal radius fractures in adult patients presenting to emergency department (ED). **Methods:** In this prospective case control study, eligible patients were adults older than 18 years who presented to the ED with distal radius fractures. 130 consecutive patient consisted of two group of Sixty-Five patients were prospectively enrolled for around 1 years. The first group underwent ultrasound-guided reduction and the second (control group) underwent blind reduction. All procedures were performed by two trained emergency residents under supervision of senior emergency physicians. **Results:** Baseline characteristics between two groups were similar. The rate of repeat reduction was reduced in the ultrasound group (9.2% vs 24.6%; $P = .019$). The post reduction radiographic indices were similar between the two groups, although the ultrasound group had improved volar tilt (mean, 7.6° vs 3.7° ; $P = .000$). The operative rate was reduced in the ultrasound groups (10.8% vs 27.7%; $P = .014$). **Conclusion:** Ultrasound guidance is effective and recommended for routine use in the reduction of distal radius fractures.

Keywords: Ultrasound; reduction, distal radius fracture; emergency department

Cite this article as: Sabzghabaei A, Shojaee M, Dolatabadi AA, Manouchehrifar M, Asadi M. Ultrasound-Guided Reduction of Distal Radius Fractures. *Emergency*. 2016; 4(3):132-135.

Introduction:

Colles' fracture is the most common wrist fracture in adults patients (1). It is a transverse fracture of the distal radial metaphysis, which is dorsally displaced and angulated, causing the classic "dinner fork" deformity seen on physical examination. Displaced distal radius fractures are usually managed with closed reduction under local or regional anesthesia, or procedural sedation and analgesia (PSA). Post-reduction radiographs are then obtained to assess the adequacy of the reduction. However, multiple inadequate reductions under blind manipulation can result in prolonged anesthesia time, increased sedation complication, increased radiation exposure, patient discomfort and additional investment of personnel, time and resource. Using ultrasonography (US) to guide reduction could improve these shortcomings (2). Ang and co-workers supported the effective role of US guidance and recommended it as a routine technique in the reduction of distal radius fractures (3). Also previous studies showed that US has a good sensitivity and specificity in evaluation of long bone and wrist fracture (4-7). Narihito K. et al also suggest that US

assistance can aid reduction of distal radius fractures as well as fluoroscopy (8). Based on diagnostic procedure, US also considered as a safe and reliable tool compared to X-ray diagnosis in juvenile fractures (9). Base on the above-mentioned, the purpose of our study was to assess the accuracy of ultrasound in monitoring closed reduction of distal radius fractures.

Methods:

Study design and setting

This case control study was carried out during May 2012 to December 2013 in the emergency department (ED) of Haft-tir educational Hospital, Tehran, Iran. The study protocol was approved by ethical committee of Shahid Beheshti University of Medical Sciences. We sought to compare the results of US guided Colles' fracture reductions, with the traditional technique of blind manipulation. The written informed consent was full fielded by all patients.

Participants

The patients with diagnosis of distal radius fracture (colles) undergoing US guided reduction were enrolled



around a one-year period, under a convenience sample. All patients with age <18 years, open fracture, intra-articular step off > 2 mm, neurovascular compromise, volar tilt > 0°, and poor compliance were excluded.

Procedure

In this study, fracture reduction was done under procedural sedation-analgesia by fentanyl 1 µg/kg and propofol 0.1 mg/kg. 130 eligible patients were categorized in each group for one year. At presentation to ED, anteroposterior (AP) and lateral (LAT) wrist x-rays were done to fracture confirmation. The attending emergency physician performed all reduction procedures and ultrasonographies. Two trained junior emergency residents performed traction-countertraction at the three first finger and the arm under supervision of senior emergency physician. 7.5 MHz linear array US probe (SonoScape SSI-5500BW) was used to examine the fracture site by orienting the probe along the longitudinal plane on the dorsal and radial aspects of the radius. During the reduction, US views may be repeated as necessary until aligning the proximal and distal cortices into as straight a line as possible, seen in both AP and LAT views. The other group underwent reduction by the same condition but without US guidance. After reduction and immobilization, AP and LAT control x-rays were obtained for two groups. The accepted criteria for successful reduction were: volar tilt > 0°, radial inclination angle of 15-25°, and radial height > 5 mm. Another attempt was made in the cases of unsuccessful reduction.

Final decisions for operative or conservative management were made by the orthopedic surgeon at either inpatient or outpatient settings. 65 patient underwent US guided and 65 cases underwent blind reduction. Two residents of was trained about 20 hours regarding performance of US and fracture reduction.

Statistical analysis

SPSS 20 (SPSS, Chicago, IL, USA) was used to analyze the data. Pre- and post-reduction x-ray criteria such as volar tilt, radial inclination angle, radial height; number of attempts for reduction; successful reduction rate; and need for open reduction in operating room were compared between 2 groups. The Student t test was used to compare the difference in means between the groups and the χ^2 and Fisher exact tests were used to compare the different rates between groups. Results were considered statistically significant at the $P < 0.05$ level.

Results:

130 patients with Colles' fracture were divided to two equal groups of US guided and blind fracture manipulation. Table 1 demonstrates the baseline characteristics of studied participants. The most common cause of injury was falling on outstretched hand (60%). As table 1 show there was no significant difference regarding sex, age, trauma mechanism, side of injury, and initial fracture indices between groups. Table 2 shows the result of pre and post reduction fracture indices. The post reduction radiographic indices were similar between the two

Table 1: Baseline Characteristics of two studied groups

	Ultrasonography (%)	Blind Manipulation (%)	P
Age, mean (SD):	36.5 (15.8)	38.6 (17.1)	0.46
Sex			
Male	53 (81.5)	51 (78.5)	0.51
Female	12 (18.5)	14 (21.5)	
Mechanism of trauma			
Accident	22 (33.8)	25 (38.5)	0.80
Falling	40 (61.5)	38 (58.5)	
Direct Trauma	3 (4.6)	2 (3.1)	
Side of fracture			
Right	32 (49.2)	33 (50.8)	0.81
Left	32 (49.2)	30 (46.2)	
Right and Left	1 (1.5)	2 (3.1)	
Fracture indices			
Volar Tilt	-21.4 (13.1)	-19.1 (14.3)	0.325
Radial Inclination 1	6.12 (6.3)	7.0 (5.3)	0.346
Radial Height 1	8.0 (2.0)	7.8 (2.2)	0.512

Table 2: Post reduction X-ray fracture indices between two groups

Fracture Indices	Ultrasonography (%)	Blind Manipulation (%)	P
Volar tilt	7.6 (5.2)	3.7 (6.0)	< 0.001
Radial inclination	18.8 (4.00)	18.4 (4.08)	0.559
Radial height	10.1 (2.4)	9.4 (2.7)	0.181



Table 3: Comparison of reduction outcome between two groups

	Ultrasonography (%)	Blind Manipulation (%)	P
Reduction quality			
Accepted	60 (92.3)	51 (78.5)	0.025
Non-accepted	5 (7.7)	14 (21.5)	
Number of reduction			
1	59 (90.8)	49 (75.4)	0.019
≥ 2	6 (9.2)	16 (24.6)	
Type of fixation			
Casting	58 (89.2)	47 (72.3)	0.014
ORIF	7 (10.8)	18 (27.7)	

ORIF: open reduction and internal fixation.

groups, except for volar tilt (mean, 7.6° vs 3.7°; $P < 0.001$). The delta volar tilt in the US group was 29° compared to 22.8° for the other group. Table 3 compares the measured outcomes between two groups. The need for further attempt was significantly reduced in the ultrasound group (6 (9.2%) vs. 16 (24.6%); $P = .019$). The need for open reduction was significantly reduced in the US groups (7 (10.8%) vs. 18 (27.7%); $P = .014$).

Discussion:

In this study, repeated attempts at reduction were significantly reduced by using US guidance. There was significantly improvement in volar tilt and decrease of operative rate. Most patients with a displaced distal radius fracture are initially managed with closed reduction under fluoroscopy or without imaging assistance in the ED (8). Fluoroscopy is not readily available in all EDs and the patient and physician are exposed to radiation. Reduction without imaging guidance result in multiple attempt, more need for post reduction radiograph, increased patient discomfort, and radiation exposure. Restoring the volar angle itself result in better functional outcome and is an important indicator for surgery. Obviously, ultrasound cannot directly measure radial height, radial inclination, or volar tilt, but alignment of the distal and proximal bony fragments of the radius in two planes can indirectly predict amount of these indices. US has a good sensitivity and specificity in evaluation of long bone (4, 5) and wrist fracture (6, 7). US also is a useful tool in evaluation and reduction attempt in infants (10-13). Multiple studies have been declared the successful utility of US in reduction of different type of fractures. Ang et al. stated that US guidance is effective and recommended it for routine use in the reduction of distal radius fracture (8). Shiang-Hu et al. reported that US group had improved volar tilt (mean, 5.93° vs 2.61°; $P = .048$). They also reported that operative rate was also reduced in this group (4.9% vs 16.7%; $P = .02$) (3). In the current study the accepted (successful) reduction was better in ultrasound group 92% (60/65) than blind group 78% (51/65). Narihito K. et al reported successful reduction of 95% (41/43) in ultrasound group versus 68%, that

was in line with our findings (15/22) (8). Sono-guided reduction is an accurate, simple, and safe technique that provides the considerable advantage of real-time observation. The advantages of US guidance over blind manipulation are decrease the number of reduction attempts and consequently fewer traumas to the surrounding soft tissues (3). The greatest value in US-guided reduction may lie in its ability to provide the practitioner with immediate imaging of bony alignment after each reduction maneuver, therefore decreasing the need for repeat procedural sedations and removal and reapplication of the splint (3, 7, 14). Finally, while US has some limitations that prevent it from completely replacing conventional radiography, it can facilitate the reduction and prevent repeated reduction attempts. There were some limitations of our study. Due to our design limitations, we did not study whether the use of US could decrease the time spent in the ED or not. Also as our limitation of resource and overcrowding, we couldn't use finger trap for traction and instead of it two person performed traction-counterattraction at the three first finger and the arm. However, it was performed similarly in both ultrasound and control groups.

Conclusion:

It seems that, ultrasonography is a suitable guidance tools for wrist fracture reduction and is recommended for routine use in real-time monitoring of close reductions.

Conflict of interest:

None

Funding support:

None

Authors' contributions:

All authors passed four criteria for authorship contribution based on recommendations of the International Committee of Medical Journal Editors.

References:

1. Gartland JJ, Werley CW. EVALUATION OF HEALED COLLES' FRACTURES. The Journal of Bone & Joint Surgery. 1951;33(4):895-907.



2. Esmailian M, Zargarbashi EH, Masoumi B, Karami M. Accuracy of ultrasonography in confirmation of adequate reduction of distal radius fractures. *Emergency*. 2013;1(1):pp. 7-10.
3. Ang S-H, Lee S-W, Lam K-Y. Ultrasound-guided reduction of distal radius fractures. *The American journal of emergency medicine*. 2010;28(9):1002-8.
4. Weinberg ER, Tunik MG, Tsung JW. Accuracy of clinician-performed point-of-care ultrasound for the diagnosis of fractures in children and young adults. *Injury*. 2010;41(8):862-8.
5. Heiner JD, Proffitt AM, McArthur TJ. The ability of emergency nurses to detect simulated long bone fractures with portable ultrasound. *International emergency nursing*. 2011;19(3):120-4.
6. Fusetti C, Poletti PA, Pradel PH, et al. Diagnosis of occult scaphoid fracture with high-spatial-resolution sonography: a prospective blind study. *Journal of Trauma and Acute Care Surgery*. 2005;59(3):677-81.
7. Hauger O, Bonnefoy O, Moinard M, Bersani D, Diard F. Occult fractures of the waist of the scaphoid: early diagnosis by high-spatial-resolution sonography. *American journal of Roentgenology*. 2002;178(5):1239-45.
8. Kodama N, Takemura Y, Ueba H, Imai S, Matsusue Y. Ultrasound-assisted closed reduction of distal radius fractures. *The Journal of hand surgery*. 2014;39(7):1287-94.
9. Ackermann O, Liedgens P, Eckert K, et al. Ultrasound diagnosis of juvenile forearm fractures. *Journal of Medical Ultrasonics*. 2010;37(3):123-7.
10. Cross KP. Bedside ultrasound for pediatric long bone fractures. *Clinical Pediatric Emergency Medicine*. 2011;12(1):27-36.
11. Levy JA, Bachur RG. Bedside ultrasound in the pediatric emergency department. *Current opinion in pediatrics*. 2008;20(3):352-242.
12. Chen L, Kim Y, Moore CL. Diagnosis and guided reduction of forearm fractures in children using bedside ultrasound. *Pediatric emergency care*. 2007;23(8):528-31.
13. Tsung JW, Blaivas M. Dynamic scanning in the transverse plane for ultrasound-guided fracture reduction. *Pediatric emergency care*. 2009;25(11):805.
14. Majeed M, Mukherjee A, Paw R. Ultrasound-guided hematoma block and fracture reduction: a new way to go forward. *Critical Care*. 2010;14(Suppl 1):1-2

Archive of SID



SID



سرویس های ویژه



سرویس ترجمه تخصصی



کارگاه های آموزشی



بلاگ مرکز اطلاعات علمی

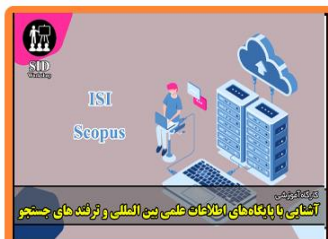

عضویت در خبرنامه

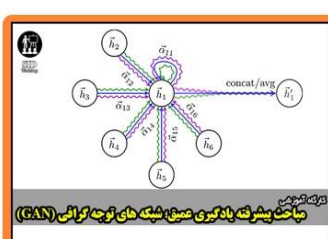


فیلم های آموزشی

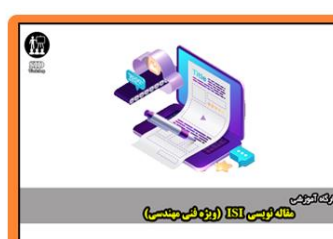کارگاه های آموزشی مرکز اطلاعات علمی جهاد دانشگاهی



کارگاه آنلاین آشنایی با پایگاه های اطلاعات علمی بین المللی و ترند های جستجو



مباحث پیشرفته یادگیری عمیق؛ شبکه های توجه گرافی (Graph Attention Networks)



کارگاه آنلاین مقاله نویسی IEEE و ISI ویژه فنی و مهندسی