

SID



سرویس های ویژه



سرویس ترجمه تخصصی



کارگاه های آموزشی



بلاگ مرکز اطلاعات علمی



عضویت در خبرنامه



فیلم های آموزشی

کارگاه های آموزشی مرکز اطلاعات علمی جهاد دانشگاهی



PROPOSAL

پروپوزال

مركز آموزش پروپوزال نویسی و پایان نامه نویسی

کارگاه آنلاین پروپوزال نویسی و پایان نامه نویسی



مركز آموزش روش تحقیق و مقاله نویسی علوم انسانی

کارگاه آنلاین روش تحقیق و مقاله نویسی علوم انسانی



ISI Scopus

مركز آموزش آشنایی با پایگاه های اطلاعات علمی بین المللی و ترکیه های جستجو

کارگاه آنلاین آشنایی با پایگاه های اطلاعات علمی بین المللی و ترکیه های جستجو

A Young Woman with Multiple Liver Cysts

Anahita Sadeghi^{1*}, Hamidreza Soleimani¹, Mehdi Saberifiroozi²

1. Shariati Hospital, Department of Internal Medicine, Tehran University of Medical Sciences, Tehran, Iran
2. Shariati Hospital, Digestive Disease Research Institute, Tehran University of Medical Sciences, Tehran, Iran

Please cite this paper as:

Sadeghi A, Soleimani HR, Saberifiroozi M. A Young Woman with Multiple Liver Cysts. *Middle East J Dig Dis* 2014;6:244-6.

A 29-year-old housewife presented with abdominal pain and abnormal results on liver function tests (table 1). The patient was from a rural area (Garmsar, Iran) and there was no family history of a similar disease. Her family owned various animals most notably jackals, dogs, and cats. The animals were not receiving regular veterinary check-ups, preventive care, or even vaccinations.

The patient underwent a liver sonography and multiple echogenic liver cysts were reported. Consequently, an abdominal CT scan was done which showed multiple cysts in her liver (figure 1).

The radiological findings suggested multiple cystic lesions of the liver and patient's history raised the suspicion of hydatid disease. To confirm this diagnosis, a serological study of IgG ELISA for echinococcal antigens was done which yielded positive results. A surgical consultation was done; however, the medical treatment was selected by the patient. Therefore, treatment with albendazole was started.

Table 1: Laboratory Results of the Patient

Test	Result
WBC	5.64x10 ³ /mm ³
PMN	67%
Lymph	28%
Eosino	6%
Hemoglobin	12.8 mg/dL
Platelet	357x10 ³ /mm ³
AST	18 U/L
ALT	22 U/L
Alkaline Phosphatase	685 U/L
Bilirubin	0.3 mg/dL
Direct	0.1 mg/dL

*** Corresponding Author:**

Anahita Sadeghi, MD
 Assistant Professor of Internal Medicine,
 Department of Internal Medicine, Tehran
 University of Medical Sciences, Shariati
 Hospital, N. Kargar Avenue., Tehran 14114-
 13137, Iran
 Tel: + 98 21 84902397
 Fax: + 98 21 88633039
 Email: anahita825@gmail.com
 Received: 20 Jul. 2014
 Accepted: 31 Aug. 2014

What is your Diagnosis?

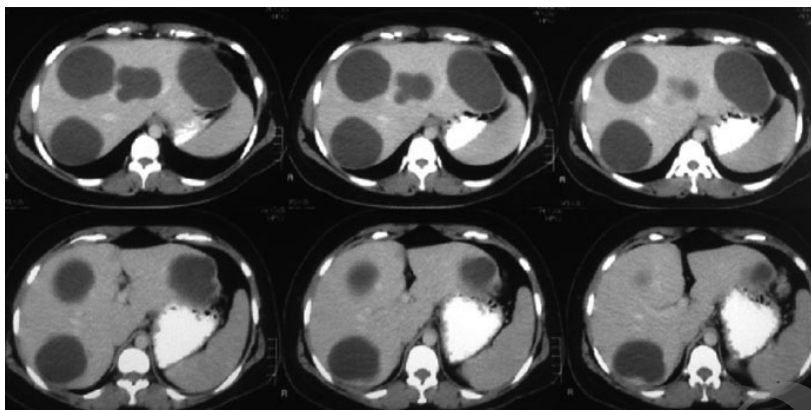


Fig. 1: An abdominal CT scan showing multiple liver cysts

Answer:

Hepatic Hydatid Cysts.

DISCUSSION

Cystic liver lesions are commonly encountered findings on radiological examinations and may represent a wide array of differential diagnoses ranging from benign developmental cysts to malignant neoplasms. Due to the wide variety of pathologic processes that can result in cystic liver lesions, it is of utmost importance to assimilate the radiological findings with the clinical and laboratory results in order to reach an accurate diagnosis.¹ Generally, the cystic lesions of the liver can be classified as simple or complex cysts. Simple cysts appear as fluid-containing lesions with fine thin walls without any irregularities such as septation, calcification, or nodularity. However, finding such irregularities on imaging studies indicates a complex lesion. Table 2 shows the differential diagnosis of cystic liver lesions along with the characteristic radiological findings of each entity.^{1,2}

In this patient the presence of multiple hypo-attenuated lesions with well-defined and distinguishable walls in an abdominal CT scan along with the patient's history of having contact with unvaccinated animals, raised the suspicion of hydatid disease which was confirmed with the serological exam.

Hydatid disease or echinococcosis is a zoonotic disease which is caused by the *Echinococcus granulosus*.³ The disease is endemic in the Mediterranean region and other sheep-raising areas.^{2,4} The dog is the definitive host of the tapeworm, while humans, cattle,

and sheep are the intermediate hosts. By eating the viscera of a sheep which contains the hydatid cysts, dog gets infected. In the dog's intestine, the scolices found in the cysts turn into adult taenia which in turn adhere to the intestinal wall and shed ovas to the feces. The feces contaminate the grass and water, the ova is ingested by the sheep, pigs and cattle and the cycle continues. Humans can become infected by ingesting the eggs of the tape worm *Echinococcus granulosus* II,^{2,4} either after eating the contaminated food or by having contact with different animals of the dog family such as dogs, jackals, and coyotes in areas where these animals have access to the contaminated offals of sheep and cattle.⁵ The ingested eggs invade the intestinal wall and by entering the portal circulations find their way into the liver.⁴ In liver the invading eggs form the hepatic cysts which consist of three layers: outer pericyst (fibrotic host tissue), middle laminated membrane or ectocyst and the inner germinal layer. The peripheral invagination of the germinal layer results in formation of the daughter cysts.¹

Eosinophilia, positive serology, and Casoni skin test are some of the key laboratory features that can help distinguish between hepatic hydatid cysts and other liver cystic lesions. The enzyme-linked immunosorbent assay (ELISA) for echinococcal antigens can confirm the diagnosis in approximately 85% of infected patients. In other words, the diagnosis of the disease is based on the results of the ELISA test.⁵ Also, history of travel to an endemic area or having contact with the above mentioned animals are important points that can help making the diag-

Table 2: Differential Diagnosis and Key Radiological Features of Cystic Hepatic Lesions

Type of the Lesion		Radiological Features
Simple Cysts	Benign developmental hepatic cyst	Homogeneous, round, regular, no wall, no enhancement
	Caroli disease	Cysts communicating with the biliary tree, central dot sign, septa
Complex Cysts	Neoplastic Undifferentiated sarcoma	Large solitary lesion, enhancing solid components, calcifications
	Biliary cystadenoma or cystadenocarcinoma	Multilocular, mural nodules, fibrous capsule, calcifications, variable signal intensities
	Hepatocellular carcinoma	Hypervascular solid part, capsule, signs of cirrhosis
	Cavernous hemangioma	Peripheral nodular enhancement, large lesion
Inflammatory or Infectious	Cystic metastases	Rim enhancement, multiple
	Abscess	Presence of air, double target sign, enhancing wall
	Hydatid cyst	Calcifications, daughter cysts, pericyst
Miscellaneous	Subcapsular pseudocyst	Occurs in left liver lobe, signs of pancreatitis, thin capsule
	Intrahepatic hematoma	Fluid attenuation at CT, methemoglobin at MR imaging, signs of trauma
	Intrahepatic biloma	No capsule, no septa, no calcifications

nosis.¹ Ultrasonography is a sensitive method for detecting liver cysts. Hyper dense lesions with well-defined margins are characteristic features of cysts in ultrasonography. In the CT scan, hepatic cysts appear as well-defined hypo-attenuating lesions with distinguishable walls.² In 50% of the patients, coarse calcifications are present and daughter cysts can also be found in 75% of the patients.^{2,4,6}

Although surgery is the definitive treatment of the disease, it is also associated with risks such as operative morbidity, recurrence of the cysts, and most notably the spillage of fluid from the cysts, which can trigger anaphylactic reactions or promote dissemination of infection.⁷ Albendazole is the drug that has widened prescribers' therapeutic choices for patients suffering from cystic hydatid disease because of *Echinococcus granulosus*.⁸ Patients who are considered inoperable or who suffer from widespread disease with numerous cysts or those who are not suitable candidates for surgery due to their complicated medical conditions, are excellent choices for Albendazole therapy.^{8,9}

CONFLICT OF INTEREST

The authors declare no conflict of interest related to this work.

REFERENCES

- Vachha B, Sun MR, Siewert B, Eisenberg RL. Cystic lesions of the liver. *Am J Roentgenol* 2011;**196**:W355-66.
- Mortelé KJ, Ros PR. Cystic focal liver lesions in the adult: differential CT and MR imaging features. *Radiographics* 2001;**21**:895-910.
- Salem CO, Schneegans F, Chollet J, Jemli ME. Epidemiological studies on echinococcosis and characterization of human and livestock hydatid cysts in mauritania. *Iran J Parasitol* 2011;**6**:49-57.
- Mergo PJ, Ros PR. MR imaging of inflammatory disease of the liver. *Magn Reson Imaging Clin N Am* 1997;**5**:367-76.
- Pedrosa I, Saíz A, Arrazola J, Ferreirós J, Pedrosa CS. Hydatid disease: Radiologic and pathologic features and complications. *Radiographics* 2000;**20**:795-817.
- Murphy BJ, Casillas J, Ros PR, Morillo G, Albores-Saavedra J, Rolfes DB. The CT appearance of cystic masses of the liver. *Radiographics* 1989;**9**:307-22.
- Liu LX, Weller PF. Antiparasitic Drugs. *N Engl J Med* 1996;**334**:1178-84.
- Nahmias J, Goldsmith R, Soibelman M, el-On J. Three- to 7-year follow-up after albendazole treatment of 68 patients with cystic echinococcosis (hydatid disease). *Ann Trop Med Parasitol* 1994;**88**:295-304.
- Horton RJ. Chemotherapy of Echinococcus infection in man with albendazole. *Trans R Soc Trop Med Hyg* 1989;**83**:97-102.

SID



سرویس های ویژه



سرویس ترجمه تخصصی



کارگاه های آموزشی



بلاگ مرکز اطلاعات علمی



عضویت در خبرنامه



فیلم های آموزشی

کارگاه های آموزشی مرکز اطلاعات علمی جهاد دانشگاهی



PROPOSAL
پروپوزال

پروپوزال نویسی و پایان نامه نویسی

دوره آموزشی

کارگاه آنلاین
پروپوزال نویسی و پایان نامه نویسی



روش تحقیق و مقاله نویسی علوم انسانی

دوره آموزشی

کارگاه آنلاین
روش تحقیق و مقاله نویسی علوم انسانی



ISI
Scopus

آشنایی با پایگاه های اطلاعات علمی بین المللی و ترند های جستجو

دوره آموزشی

کارگاه آنلاین آشنایی با پایگاه های اطلاعات علمی بین المللی و ترند های جستجو