

Ear necrosis syndrome in weaning pigs associated with PCV2 infection: A case report

Vassilis Papatsiros*

Department of Medicine (Clinic of Farm Animal Medicine), Faculty of Veterinary Medicine, University of Thessaly, Karditsa, Greece.

Article Info	Abstract
<p>Article history:</p> <p>Received: 30 December 2011 Accepted: 8 April 2012 Available online: 15 September 2012</p> <p>Key words:</p> <p>Circovirus PMWS Ear necrosis Pig Vaccine</p>	<p>Porcine necrotic ear syndrome (PNES) in pigs has been reported as an increasing health problem in many countries with intensive pig farming. The etiology of this disease is complex and the presumed triggering factors can be divided into infectious and non-infectious agents. The present report describes a case of Porcine Circovirus type 2 (PCV2), infection associated with lesions of PNES at the weaning stage of a farrow-to-finish pig farm. Approximately 35% of weaners (1-3 weeks after weaning) presented clinical symptoms similar to Post-weaning Multisystemic Wasting Syndrome (PMWS). About 2-3 weeks after weaning the first lesions of PNES occurred in approximately 20% of pigs, resulting in a significant health problem characterized by poor growth or severe wasting and finally mortality up to 15% in some batches. Moreover, approximately 5% of survived weaners, during growing / finishing stage, presented poor growth and secondary co-infections that lead to death. The present study based on the clinical signs, serological and pathological examinations, indicates that weaners suffered by sub-acute PCV2 infection resulting in PMWS associated with PNES. The lesions of PNES were initially observed at the same period (4-8 weeks of age) with the higher seroprevalence of PCV2 infection. Metaphylaxis of this case included intramuscular injection of florfenicol for the treatment and control of skin lesions and respiratory signs. Moreover, piglets were vaccinated against PCV2. In conclusion, sub-acute PCV2 infection could be included in triggering factors PNES in weaners. The mass vaccination against PCV2 of infected piglets might be effective in reduction of clinical signs and losses of PNES in cases of PCV2 infection associated with PNES.</p> <p>© 2012 Urmia University. All rights reserved.</p>

سندرم گوش نکروتیک خوک سانان در خوکهای از شیر گرفته شده مرتبط با عفونت سیرکو ویروسی تیپ ۲: گزارش موردی

چکیده

بر طبق گزارشات موجود، سندرم گوش نکروتیک خوک سانان (PNES) در خوکها یک مشکل بهداشتی روز افزون در بسیاری از کشورهای است که به پرورش خوک اقدام می کنند. علت شناسی این بیماری پیچیده بوده و به نظر می رسد که عامل آغاز گر آن را می توان به عوامل عفونی و غیر عفونی تقسیم کرد. گزارش حاضر یک مورد از عفونت ویروسی سیرکو ویروس خوک تیپ ۲ (PCV2) مرتبط با جراحات PNES در مرحله از شیر گیری یک خوک در مزرعه ای می باشد که خوکها را تا مرحله کشتار پرورش می دهند. برآورد شد که ۳۵ درصد خوکهای از شیر گرفته شده (۱ تا ۳ هفته پس از از شیر گیری) علائم بالینی مشابه به سندرم تحلیل چندگانه اعضای بدن متعاقب از شیر گیری (PMWS) را نشان دادند. حدود ۲ تا ۳ هفته پس از از شیر گیری اولین جراحات PNES در حدود ۲۰ درصد خوکها رخ داد که به واسطه رشد ضعیف و تحلیل شدید بدن و در نهایت مرگ ۱۵ درصدی در برخی واحد ها منجر به مشکل بهداشتی قابل ملاحظه ای گردید. علاوه بر این، حدود ۵ درصد خوکهای از شیر گرفته شده که زنده ماندند در خلال سنین رشد و وزن گیری رشد ضعیفی را نشان داده و مبتلا به عفونتهای ثانویه شده که منجر به مرگ گردید. مطالعه حاضر که بر اساس آزمایشات بالینی، سرولوژیکی و پاتولوژیکی استوار است نشان داد که خوکهای از شیر گرفته شده از عفونت PCV2 تحت حاد رنج می بردند که منجر به PMWS مرتبط با PNES گردید. جراحات PNES ابتدا در سن ۴ تا ۸ هفتهگی توأم با شیوع بالای عفونت PCV2 رخ داد. متا فلاکسی این مورد شامل تزریق عضلانی فلورفنیکل به منظور درمان و کنترل جراحات جلدی و علائم تنفسی بود. علاوه بر این، بچه خوکها در برابر PCV2 مایه کوبی شدند. نتیجه اینکه عفونت تحت حاد PCV2 را می توان به عنوان عامل آغاز گر PNES در خوکهای از شیر گرفته شده دخیل دانست. مایه کوبی کل گله در برابر PCV2 در بچه خوکهای مبتلا می تواند در کاهش علائم بالینی و حذف PNES در موارد عفونتهای مرتبط با PNES موثر باشد.

واژه های کلیدی: سیرکو ویروس، سندرم تحلیل چندگانه اعضای بدن متعاقب از شیر گیری، نکروز گوش، خوک، واکسن

*Correspondence:

Vassilis Papatsiros DVM, PhD
Department of Medicine (Clinic of Farm Animal Medicine), Faculty of Veterinary Medicine, University of Thessaly, Karditsa, Greece.
E-mail: vpapatsiros@vet.uth.gr

Introduction

Necrotic ear syndrome or ear necrosis in pigs has been reported as an increasing health problem in many countries with intensive pig farming.¹ It is characterized by large erosive lesions at the margin of the pinna(e) in both sexes. It occurs mainly in weaning pigs and growers/fatteners with bodyweight ranging approximately from 10 to 40 kg.² The earliest lesions are normally visible on the ear tips at 6-7 weeks old pigs, beginning as a superficial vesicular dermatitis associated with superficial auricular trauma, which can bleed, attractive to pen mates, who may then start to bite at the lesion, resulting in swelling and reddening of the ear. Localized lesions slowly healed or sporadically progressed to deep necrotic ulcers, cellulitis, vasculitis, thrombosis, ischemia.³

The etiology of this disease is complex and therefore it is often named as porcine ear necrosis syndrome (PENS). The presumed triggering factors can be divided into infectious and not infectious agents. It is usually the result of a mixed infections causing damage to the skin. *Staphylococcus hyicus* is the most common isolated agent in lesions of PENS cases, but other pathogens such as *Mycoplasma suis*, *Streptococcus suis* and spirochetes are often implicated.⁴⁻⁸ Moreover, non-infectious factors such as intensive pen density and overpopulation, poor air quality with high concentrations of gases (e.g. ammonia), poor hygienic conditions, copper and magnesium deficiency, contamination of feed with mycotoxins and cannibalism, were associated with an increased risk of incidence of PENS.^{2,9-12}

Recently, an important causative role has also been attributed to immunosuppressive agents such as Porcine Circovirus type 2 (PCV2), Porcine Reproductive and Respiratory Syndrome Virus (PRRSV), as well as mycotoxins.^{7,13} PCV2 is considered to be involved in etiology agents of the development of PENS¹⁴ and is present in ear lesions PCV2 infected pigs,¹⁵ associated sometimes with co-infections of PRRSV,^{16,17} *Pasteurella multocida*, *Streptococcus suis* types 1 and 2 and other pathogens.^{18,19}

Last years a marked increase of field cases characterized by PENS associated with PCV2 infection has been observed in the USA,²⁰ in Canada²¹ and Europe.^{1,9,14,22} In Greece, during the last two years our clinical observations in field conditions suggest the cases of PENS have been increased and when Porcine Circovirus Associated Diseases (PCVAD) is present on a farm, more pigs with ear tip necrosis are observed, accompanied with severe wasting, respiratory clinical signs and significant mortality.²³

Case Description

History. The present report describes a case of PCV2 infection associated with lesions of PENS at the weaning stage of a farrow-to-finish pig farm of 200 sows (Large x White x Landrace) in Central Greece. Weaning took place

at the age of 25 ± 3 days. All weaning pigs were moved every week into the flat deck unit, grouped in pens of 15 pigs. This farm applied all appropriate facilities of biosecurity of good hygiene.

Clinical observations. Approximately 35% of weaning pigs (1-3 weeks after weaning), through out of different batches, presented clinical symptoms similar to Post-weaning Multisystemic Wasting Syndrome (PMWS), such as fever, anorexia, diarrhea, considerable weight loss cough, dyspnea, paleness of the skin, enlarged lymph nodes and lethargy. About 2-3 weeks after weaning the first lesions of PENS occurred in approximately 20% of pigs, resulting in a significant health problem characterized by poor growth or severe wasting and finally mortality up to 15% in some batches. Moreover, approximately 5% of survived weaning pigs, during growing / finishing stage, presented poor growth and secondary co-infections that lead to death.

Regarding the lesions of PENS, they initially appeared at the margin of the pinna(e) (on the tip of the ear or at its base) as a superficial vesicular dermatitis associated with superficial auricular trauma (Fig. 1. A and B). These lesions were characterized by necrosis, vasculitis, dry gangrene and inflammation that sporadically progress in exudative or ulcers (Fig. 2. A and B). In addition, the necrotic lesions were complicated with secondary infections.

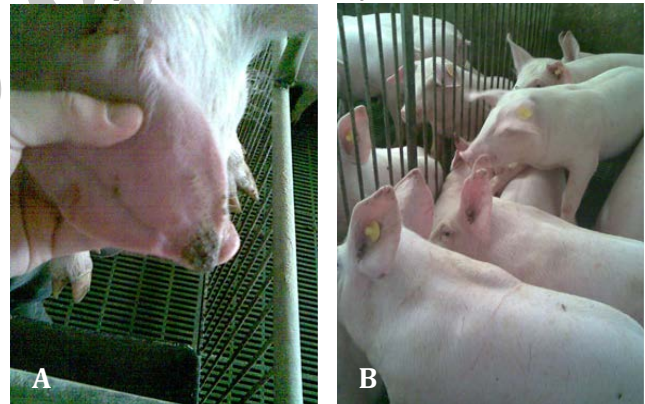


Fig. 1. A. Weaning pig with initial lesions of PENS. **B.** Group of pigs with PENS clinical signs.

Sampling / Diagnosis. Blood samples were collected from pigs at age of 5-6 weeks (group 1), 7-8 weeks (group 2), 9-10 weeks (group 3) and 22-23 weeks (group 4). Serum samples were stored at -20°C , and analyzed for PCV2 IgM and IgG antibodies by Ig capture ELISA based on method described by van Esch and Wellenberg.²⁴ IgM and IgG specific ELISA tests (Ingezim PCV IgG / IgM®, Spain) were also used. Moreover, five weaning pigs (4-9 weeks of age) were euthanized for necropsy. Samples collected from lung, heart, inguinal lymph node, tonsil, thymus, spleen, small and large intestines, liver, kidney, and pancreas were fixed in 10% (w/v) buffered formaldehyde for 24 h and embedded in paraffin by standard histologic procedures.

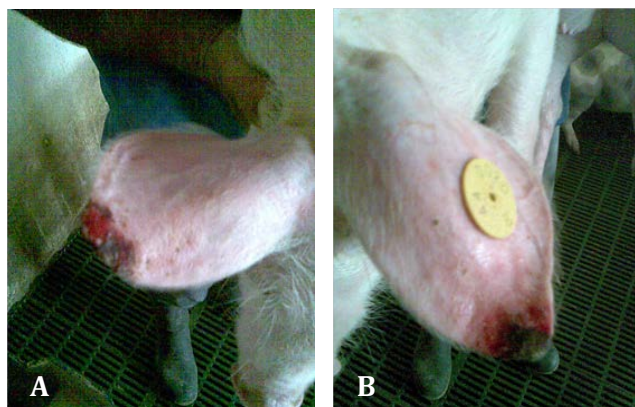


Fig. 2 A and B. Weaning pigs with severe lesions of ear necrosis syndrome.

Results

The serological results for PCV2 IgM and IgG responses in sera blood samples are shown in Table 1. Based on the serological results and the proposed interpretation of PCV2 IgM and IgG ELISA results in pigs,²⁴ it is noticed that infected pigs suffered by sub-acute infection.

Table 1. Percentage of PCV2- positive pigs (PCV2 IgM, IgG) in different ages.

Animals	Test system	No.	Percentage positive pigs
Group 1	IgM ELISA	10	60% (6/10)
(5-6 weeks)	IgG ELISA	10	20% (2/10)
Group 2	IgM ELISA	10	50% (4/10)
(7-8 weeks)	IgG ELISA	10	10% (1/10)
Group 3	IgM ELISA	10	45% (4/9*)
(9-10 weeks)	IgG ELISA	10	10% (1/10)
Group 4	IgM ELISA	15	21% (3/14*)
(22-23 weeks)	IgG ELISA	15	7% (1/15)

* insufficient serum. No. = number of animals.

Pathological examinations based on microscopic analysis of lymphoid tissue immunohistochemistry and in situ hybridization, indicated abundant amount of PCV2 DNA within observed histopathological PMWS-specific lesions (lymphocyte depletion in lymphoid tissues and interstitial pneumonia).

Treatment protocol / Control strategies. In this case of PCV2-infection associated with PNWS, intramuscular injection of florfenicol (20 mg kg⁻¹ body weight) was suggested for the treatment and control of skin lesions and respiratory signs. Moreover, the following batches of piglets were vaccinated against PCV2 with commercial vaccine Porcilis® PCV (MSD Animal Health Animal Health) administered with 2 × 2 mL dose scheme (first dose at 7th day of age, with the second dose 3 weeks later -day of weaning). This vaccination scheme resulted in a significant reduction of PNES prevalence and mortality rate of weaning pigs in the herd (data not shown). At the same time, for these following batches of piglets a grouping of 10 animals per pen at weaning stage was applied.

Discussion

Based on the clinical signs of infected weaning pigs and serological as well as pathological results, we concluded that weaning pigs suffered by sub-acute PCV2 infection resulting in PMWS associated with PNES. The lesions of PNES were initially observed at the same period (4-8 weeks of age) the higher seroprevalence of PCV2 infection, as is shown in Table 1.

The results of the present study indicate that PNES co-existing with PCV2 infection in many cases. The prevention and control of PCVAD are based on proper immunization (vaccination) and management practices.¹⁹ Nowadays, at least four commercial vaccines are available against PCVAD in piglets and sows. The vaccines have succeeded in reducing losses caused by PCV2 in Europe, Canada and the USA.²⁵ The findings of our study agree with the results of previous studies,^{1,14,22} with the difference that we managed to reduce the losses due to PCV2 infection associated with PNES, using an inactivated vaccine in 2 doses scheme (early at 7th day of age and at day of weaning).

In conclusion, sub-acute PCV2 infection could be included in triggering factors PNES in weaners. The mass vaccination against PCV2 of infected piglets might be effective in reduction of clinical signs and losses of PNES in cases of PCV2 infection associated with PNES.

References

- Petersen HH, Nielsen EO, Hassing AG, et al. Prevalence of clinical signs of disease in Danish finisher pigs. *Vet Rec* 2008; 162(12): 377-382.
- Cameron RDA. Diseases of the Skin. In: Straw BE, Zimmerman JJ, D'Allaire SD, et al., Eds. *Diseases of Swine*, 9th ed. Iowa, Ames: Iowa State Press 2006: 179-198.
- Richardson A, Morter RL, Rebar AH, et al. Lesions of porcine necrotic ear syndrome. *Vet Pathol* 1984; 21 (2): 152-157.
- Fraser CM, Bergeron JA, Mays A, et al. The Merck Veterinary Manual, 7th ed. Rahway, New Jersey: Merck & Co. 1991: 308.
- Mirt D. Lesions of so-called flank biting and necrotic ear syndrome in pigs. *Vet Rec* 1999; 144: 92-96.
- Tanabe T, Hisaaki S, Hideki S, et al. Correlation between occurrence of exudative epidermitis and exfoliative toxin-producing ability of *Staphylococcus hyicus*. *Vet Microbiol* 1996; 48: 9-17.
- Molnár T, Glávits R, Szeredi L, et al. Occurrence of porcine dermatitis and nephropathy syndrome in Hungary. *Acta Vet Hung* 2002; 50: 5-16.
- Thacker EL. Mycoplasmal Diseases. In: Straw BE, Zimmerman JJ, D'Allaire SD, et al., Eds. *Diseases of Swine*, 9th ed. Iowa, Ames: Iowa State Press 2006: 701-717.

9. Busch ME, Wachmann H, Nielsen EO, et al. Risk factors for each necrosis and tail lesions in weaners. In Proceedings of 20th International Pig Veterinary Society Congress, Durban, South Africa 2008: OR.12.12.
10. Osweiler, GD. Occurrence of Mycotoxins in Grains and Feed. In: Straw BE, Zimmerman JJ, D'Allaire SD, et al. Eds. Diseases of Swine, 9th ed. Iowa, Ames: Iowa State Press 2006: 915-929.
11. Schroder-Petersen DL, Simonsen HB. Tail biting in pigs. *Vet J* 2001; 196-210.
12. Truszczyński M, Pejsak Z. *Mycoplasma suis* and porcine eperythrozoonosis, including achievements of the last years, *Medycyna Wet* 2009; 65: 223-227.
13. Allan GM, Ellis JA. Porcine circovirus: a review. *J Vet Diagn Invest* 2000; 12(1): 3-14.
14. Madec F, Rose N. Post-weaning multisystemic wasting syndrome (PMWS), in pigs: An up-date with still questions. In Proceedings of International Society for Animal Hygiene, Warsaw Poland, 2005: 367.
15. Zlotowski, P, Correa AMR, Barcellos DESN, et al. Presence of PCV2 in ear lesions in the course of PCVAD in growing pigs. In Proceedings of 20th International Pig Veterinary Society Congress, Durban, South Africa 2008; 555.
16. Choi C, Chae C. Colocalization of porcine reproductive and respiratory syndrome virus and porcine circovirus 2 in porcine dermatitis and nephropathy syndrome by double- labeling technique. *Vet Pathol* 2001; 38: 436-441.
17. Thibault S, Drolet R, Germain MC, et al. Cutaneous and systemic necrotizing vasculitis in swine. *Vet Pathol* 1998; 35: 108-116.
18. Lainson FA, Aitchison KD, Donachie W, et al. Typing of *Pasteurella multocida* isolated from pigs with and without porcine dermatitis and nephropathy syndrome. *J Clin Microbiol* 2002; 40: 588-593.
19. Thomson JR, Higgins RJ, Smith WJ, et al. Porcine dermatitis and nephropathy syndrome: clinical and pathological features of cases in the United Kingdom (1993-1998). *J Vet Med A Physiol Pathol Clin Med*, 2002; 49: 430-437.
20. Henry SC, Tokach LM. Porcine circovirus-associated disease in Kansas. In Proceedings of Allen D. Leman Swine Conference, St. Paul – Minnesota – USA 2006: 110-111.
21. Desrosiers R. Overview of PCVD - The Disease in Eastern Canada & US vs. Europe. *Advances in Pork Production* 2007; 18: 35.
22. Pejsak Z, Markowska-Daniela I, Pomorska-Móla M, et al. Ear necrosis reduction in pigs after vaccination against PCV2. *Res Vet Sci* 2011; 91(1): 125-128.
23. Papatsiros VG. Exploration of the connection between porcine necrotic ear syndrome and PCV2 infection. *J Anim Vet Adv* 2011; 10(2): 185-187.
24. Van Esch E, Wellenberg GJ. IgM and IgG antibody responses in sera from pigs experimentally infected with PCV2. In Proceedings of 5th International Symposium on Emerging and Re-emerging Pig Diseases, 2007: 68.
25. Opriessnig T, Meng XJ, Halbur PG. Porcine circovirus type 2 associated disease -Update on current terminology, clinical manifestations, pathogenesis, diagnosis, and intervention strategies. *Vet Diagn Invest* 2007; 19: 591-615.

Archive