



# Fine Needle Aspiration Cytology of Orbital and Ocular Adnexal Lesions

Mozhgan Rezaei Kanavi, MD

Ocular Tissue Engineering Research Center, Shahid Beheshti University of Medical Sciences, Tehran, Iran

*J Ophthalmic Vis Res* 2016; 11 (3): 243-244.

Fine needle aspiration cytology (FNAC) of orbital tumors as a rapid and minimally invasive diagnostic technique backs to 1975<sup>[1]</sup> and since then it was widely used as a primary investigative procedure for the diagnosis and management of various orbital and eyelid lesions.<sup>[2]</sup> This technique when performed in experienced hands is safe and of great value in the diagnosis of new primary, recurrent, and metastatic orbital tumors.<sup>[2-4]</sup> Moreover, it provides the considerable advantages to both patient and orbital surgeon in terms of shortening the hospitalization period, reduction of health care costs, and proper management of orbital lesions.<sup>[3]</sup> The reported diagnostic accuracy of this technique for orbital and adnexal lesions ranged from 47% to 100% and its diagnostic value has been increased with the help of various ancillary methods.<sup>[2,3,5-10]</sup> In a series by Nag et al,<sup>[11]</sup> the sensitivity and specificity of FNAC in the diagnosis of orbital lesions was 86.6% and 100%, respectively. Although no major surgical intervention should be planned only based on FNAC results, this technique can be beneficial for planning further medical or limited surgical management of the orbital and adnexal lesions.<sup>[2,3]</sup> Moreover, if FNAC results are interpreted in the light of clinical history, clinical features, and imaging appearances of the lesion, they may eliminate the subsequent need for incisional or excisional biopsy.<sup>[12]</sup>

Effective FNAC results will be obtained by a proper teamwork between an orbital surgeon expert in the procedure technique and a cytopathologist experienced in orbital pathology.<sup>[2,10,13]</sup> Potential pitfalls of FNAC of orbital lesions include (i) lack of enthusiasm for performing FNAC due to orbital structural complexity and fear of globe and optic nerve injuries; (ii) absence of an experienced cytopathologist as well as challenges faced with in the diagnosis of extreme heterogeneity of lesions occurring in the orbit and ocular adnexa; and (iii) challenges in sampling deep-seated retrobulbar lesions, lymphoid lesions, and highly fibrotic tumors which affects the accuracy of FNAC.<sup>[7,10,13-15]</sup> Comprehensive awareness from such issues ahead appears required to minimize the risks and

complications of FNAC. For instance, imaging guidance such as computed tomography or ultrasonography in localizing deep-seated retrobulbar lesions is a safe and feasible method which reduces the risk of orbital contents injuries and increases the effectiveness of FNAC.<sup>[16-20]</sup> Moreover, implementation of ancillary techniques such as immunocytochemistry in FNAC were of great help in definitive diagnosis of orbital and ocular adnexal lesions.<sup>[3,15,19]</sup> In a paper by Khan et al on the role of fine needle aspiration cytology as a diagnostic tool in orbital and adnexal lesions, the importance of these ancillary techniques was not clearly demonstrated.<sup>[21]</sup> In their study, it was uncertain how the authors could distinguish an amelanotic malignant melanoma from a schwannoma or an inflammatory pseudotumor from a lymphoma on cytopathology without performing special immunocytochemical studies.

The authors investigated the role of FNAC in the diagnosis of palpable orbital and ocular adnexal masses and comparable to the most recent studies<sup>[12,15]</sup> showed a concordance rate of 90% between the FNAC and histopathological results.<sup>[21]</sup> In their series, it was not indicated whether the size, location, and the radiologic appearance of the lesions in terms of being focal or diffuse might have any effect on the rate of insufficient aspirates or the diagnostic accuracy of FNAC. Furthermore, similar to other FNAC-based studies, this study had limitations regarding being non-randomized and retrospective. Hence, validating FNAC as a harmless and effective diagnostic method needs a large-scale, randomized, prospective, and multicenter study. Nonetheless, the high success rates of FNAC of orbital and adnexal lesions in the series reported by Khan et al<sup>[21]</sup> and prior studies<sup>[11,12,14,15]</sup> are certainly of value to both orbital surgeons and patients. Via implementation of this safe technique, orbitotomies may be avoided in the lesions which can be managed with medical therapies, as in infectious, lympho-proliferative, and non-resectable lesions. FNAC can also be of diagnostic value in benign resectable lesions requiring a minimal surgery. Moreover, short time hospitalization and rapid recovery

of patients reduces the financial burden on the healthcare system when FNAB is performed instead of orbitotomy. To achieve a highly successful and uncomplicated FNAC, appropriate patient selection, involvement of experienced surgeons and cytopathologists, use of ancillary tests, and implementation of imaging guidance are necessitated.

## REFERENCES

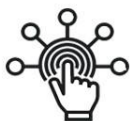- Schyberg E. Fine needle biopsy of orbital tumours [proceedings]. *Acta Ophthalmol Suppl* 1975;125:11.
- Agrawal P, Dey P, Lal A. Fine-needle aspiration cytology of orbital and eyelid lesions. *Diagn Cytopathol* 2013;41:1000-1011.
- Tijl JW, Koornneef L. Fine needle aspiration biopsy in orbital tumours. *Br J Ophthalmol* 1991;75:491-492.
- Midena E, Segato T, Piermarocchi S, Boccato P. Fine needle aspiration biopsy in ophthalmology. *Surv Ophthalmol* 1985;29:410-422.
- Krohel GB, Tobin DR, Chavis RM. Inaccuracy of fine needle aspiration biopsy. *Ophthalmology* 1985;92:666-670.
- Heerde VP, Peterse JL. Fine needle aspiration of the orbit. *Orbit* 1985;4:217-220.
- Kennerdell JS, Slamovits TL, Dekker A, Johnson BL. Orbital fine-needle aspiration biopsy. *Am J Ophthalmol* 1985;99:547-551.
- Westman-Naeser S, Naeser P. Tumours of the orbit diagnosed by fine needle biopsy. *Acta Ophthalmol (Copenh)* 1978;56:969-976.
- Tarkkanen A, Koivuniemi A, Liesmaa M, Merenmies L. Fine-needle aspiration biopsy in the diagnosis of orbital tumours. *Graefes Arch Clin Exp Ophthalmol* 1982;219:165-170.
- Zajdela A, Vielh P, Schlienger P, Haye C. Fine-needle cytology of 292 palpable orbital and eyelid tumors. *Am J Clin Pathol* 1990;93:100-104.
- Nag D, Bandyopadhyay R, Mondal SK, Nandi A, Bhaduri G, Sinha SK. The role of fine needle aspiration cytology in the diagnosis of orbital lesions. *Clin Cancer Investig J* 2014;3:21-25.
- Wiktorin AC, Dafgård Kopp EM, Tani E, Söderén B, Allen RC. Fine-needle aspiration biopsy in orbital lesions: A retrospective study of 225 cases. *Am J Ophthalmol* 2016;166:37-42.
- Liu D. Complications of fine needle aspiration biopsy of the orbit. *Ophthalmology* 1985;92:1768-1771.
- Kennerdell JS, Dekker A, Johnson BL. Orbital fine needle aspiration biopsy: The results of its use in 50 patients. *Neuroophthalmol* 1980;1:117-121.
- Nair LK, Sankar S. Role of fine needle aspiration cytology in the diagnosis of orbital masses: A study of 41 cases. *J Cytol* 2014;31:87-90.
- Arora R, Rewari R, Betheria SM. Fine needle aspiration cytology of eyelid tumors. *Acta Cytol* 1990;34:227-232.
- Das DK, Das J, Bhatt NC, Chachra KL, Natarajan R. Orbital lesions. Diagnosis by fine needle aspiration cytology. *Acta Cytol* 1994;38:158-164.
- Dey P, Radhika S, Rajwanshi A, Ray R, Nijhawan R, Das A. Fine needle aspiration biopsy of orbital and eyelid lesions. *Acta Cytol* 1993;37:903-907.
- Zeppa P, Tranfa F, Errico ME, Troncone G, Fulciniti F, Vetrani A, et al. Fine needle aspiration (FNA) biopsy of orbital masses: A critical review of 51 cases. *Cytopathology* 1997;8:366-372.
- Gupta S, Sood B, Gulati M, Takhtani D, Bapuraj R, Khandelwal N, et al. Orbital mass lesions: US-guided fine-needle aspiration biopsy – Experience in 37 patients. *Radiology* 1999;213:568-572.
- Khan L, Malukani K, Malaiya S, Yeshwante P, Ishrat S, Nandedkar SS. Role of fine needle aspiration cytology as a diagnostic tool in orbital and adnexal lesions. *J Ophthalmic Vis Res* 2016;11:287-295.

This is an open access article distributed under the terms of the Creative Commons Attribution-NonCommercial-ShareAlike 3.0 License, which allows others to remix, tweak, and build upon the work non-commercially, as long as the author is credited and the new creations are licensed under the identical terms.

Access this article online	
Quick Response Code: 	Website: <a href="http://www.jovr.org">www.jovr.org</a>
	DOI: 10.4103/2008-322X.188391

**How to cite this article:** Kanavi MR. Fine needle aspiration cytology of orbital and ocular adnexal lesions. *J Ophthalmic Vis Res* 2016;11:243-4.

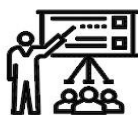# SID



سرویس های ویژه



سرویس ترجمه تخصصی



کارگاه های آموزشی



بلاگ مرکز اطلاعات علمی



عضویت در خبرنامه



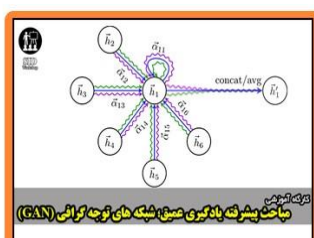
فیلم های آموزشی

## کارگاه های آموزشی مرکز اطلاعات علمی جهاد دانشگاهی



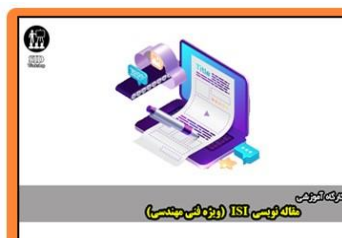آموزش آنلاین ابزار پژوهش کمی (کاربره نرم افزار SPSS)

کارگاه آنلاین کاربرد نرم افزار SPSS در پژوهش



مباحث پیشرفته یادگیری عمیق شبکه های توجه گرافی (GAN)

مباحث پیشرفته یادگیری عمیق؛ شبکه های توجه گرافی (Graph Attention Networks)



مقاله نویسی ISI (روزه علمی مهندسی)

کارگاه آنلاین مقاله نویسی IEEE و ISI ویژه فنی و مهندسی