

# SID



سرویس های ویژه



سرویس ترجمه تخصصی



کارگاه های آموزشی



بلاگ مرکز اطلاعات علمی



عضویت در خبرنامه



فیلم های آموزشی

## کارگاه های آموزشی مرکز اطلاعات علمی جهاد دانشگاهی



کارگاه آنلاین آشنایی با پایگاه های اطلاعات علمی بین المللی و ترند های جستجو



مباحث پیشرفته یادگیری عمیق؛ شبکه های توجه گرافی (Graph Attention Networks)



کارگاه آنلاین مقاله نویسی IEEE و ISI ویژه فنی و مهندسی

## Case Report

# Favorable Long-term Prognosis of Cataract Surgery in Herpes Zoster Ophthalmicus

Kulbhushan Prakash Chaudhary, MD; Deepti Mahajan, MS; Praveen Panwar, MS

Department of Ophthalmology, Indira Gandhi Medical College, Shimla, Himachal Pradesh, India

### Abstract

**Purpose:** Scleritis is a rare presentation of herpes zoster ophthalmicus, complicated most commonly by iridocyclitis and raised intraocular pressure. These complications can recur in subsequent years, therefore they should be managed well.

**Case Report:** We describe a female patient who developed scleritis, complicated cataract and secondary glaucoma 2 years after being diagnosed by HZO. Secondary glaucoma was managed medically, and the patient underwent extracapsular cataract extraction for the complicated cataract. Final visual acuity was 6/6 and IOP was 22.4 mm Hg. This is a rare report describing favorable long-term (>20 years) prognosis for surgical management of cataract associated with HZO together with scleritis, secondary glaucoma and post-herpetic neuralgia.

**Conclusion:** A favorable outcome may be attained with surgery for complicated cataract associated with HZO if the condition is managed optimally and intraocular inflammation is well controlled.

**Keywords:** Complicated Cataract; Herpes Zoster Ophthalmicus; Post-herpetic Neuralgia; Scleritis; Secondary Glaucoma

*J Ophthalmic Vis Res* 2016; 11 (2): 221-224.

### INTRODUCTION

It has been estimated that the lifetime risk of developing herpes zoster (HZ) viral infection is 10-20%.<sup>[1]</sup> Scleritis, episcleritis, and complicated cataract can develop in subsequent years secondary to the inflammation.<sup>[2]</sup> Reactivation of the varicella-zoster virus (VZV) originates from sensory ganglia. When the infection involves the first division of the trigeminal nerve (ophthalmic division), the disorder is termed herpes zoster ophthalmicus (HZO).<sup>[3]</sup> Despite advances in therapy, HZO-related complications have been reduced but not eliminated.

Herein, we describe a patient in whom complications of HZO, were well managed and intraocular inflammation was well controlled. We obtain a favorable surgical outcome following cataract surgery. This patient represents is a rare case of long-term favorable prognosis for management of HZO induced scleritis, complicated cataract, secondary glaucoma and post-herpetic neuralgia.

### CASE REPORT

A 50-year-old female patient presented with fever, malaise, severe pain, swelling, and redness in the left eye, accompanied by vesicular eruptions on the skin of the eyelid and forehead in the year 1993. Visual acuity (VA) was 6/6 and 6/18 in the right and left eyes, respectively. Corneal sensitivity was decreased on the affected side,

This is an open access article distributed under the terms of the Creative Commons Attribution-NonCommercial-ShareAlike 3.0 License, which allows others to remix, tweak, and build upon the work non-commercially, as long as the author is credited and the new creations are licensed under the identical terms.

For reprints contact: [reprints@medknow.com](mailto:reprints@medknow.com)

**How to cite this article:** Chaudhary KP, Mahajan D, Panwar P. Favorable long-term prognosis of cataract surgery in herpes zoster ophthalmicus. *J Ophthalmic Vis Res* 2016;11:221-4.

### Correspondence to:

Deepti Mahajan, MS. Arunodya, Cemetery Road, Sanjauli, Shimla - 171 006, Himachal Pradesh, India.  
E-mail: [mahajandeepti22@gmail.com](mailto:mahajandeepti22@gmail.com)

Received: 27-09-2014

Accepted: 21-01-2015

### Access this article online

#### Quick Response Code:



Website:  
[www.jovr.org](http://www.jovr.org)

DOI:  
10.4103/2008-322X.183922

and multiple fine micro-dendritic lesions were present on the inferior nasal, superonasal and mid-peripheral part of the cornea. Slit lamp examination revealed +2 cells in the anterior chamber and fine KPs distributed over the corneal endothelium. Fundus examination revealed an cup disc ratio of 0.3 in the right eye and 0.4 in the left eye with macular hyperpigmentation. She was diagnosed with an acute attack of severe HZO in her left eye, complicated by keratouveitis. Diseases such as HIV, immunosuppression, and malignancy were ruled out by history. Rheumatoid factor (Rh) was not present in this patient. It was evaluated to rule out rheumatoid arthritis which may have caused complicated cataract. The presence of Rh in serum could also have indicated the occurrence of suspected autoimmune activity unrelated to rheumatoid arthritis. Her random blood sugar level was normal.

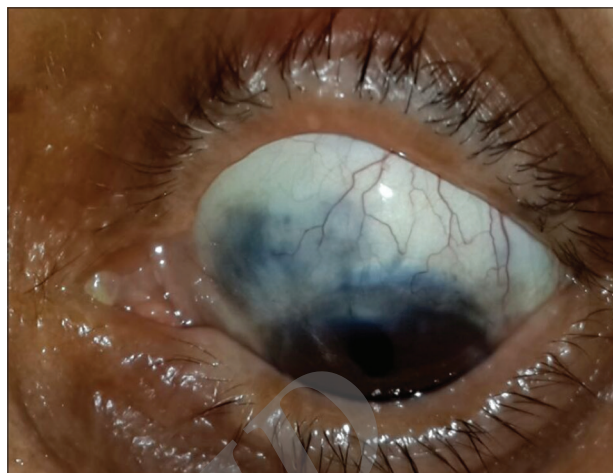
The patient was treated with acyclovir (Acivir) 800 mg 5 times for 5 days and carbamazepine (Carbatrol) 200 mg for 1-week with topical steroids – G. Betensol – N 1 hourly.

One year later, she presented with severe agonizing pain in the left eye. Slit lamp examination revealed thinning of the sclera on the superotemporal part of the anterior sclera, but no ectasia was present. Intraocular pressure (IOP) was 25.8 mmHg on the affected side. At this stage the patient was treated with non-steroidal anti-inflammatory drugs (Propin 17%) B.D, topical steroids - (G. Betnesol etne, and beta blocker - (Glucotim 5%) B.D.

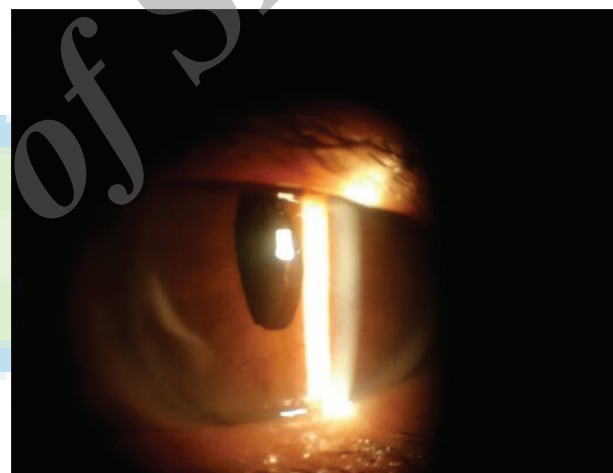Patient remained asymptomatic for one year. In 1995, she presented with decreased vision in the left eye down to 6/36. She was diagnosed by complicated cataract with posterior synechiae at the 8 o'clock position, pigment dispersion on the endothelium, and HZO induced scleritis. She was given treatment for recurrent herpetic infection with acyclovir (Acivir) 400 mg B.D. for 6 months. When the eye was silent after 6 months and no intraocular inflammation was present, cataract extraction with posterior chamber intraocular lens (P.C.I.O.L) implantation was performed by extra-capsular cataract extraction (ECCE) [Figure 1]. Post-operatively, she was given topical steroids -G. Betamethasone 0.1% BD for 6 months, tablet Prednisolone 20 mg OD post cibal, G.Timolol 5% BD and tab Nimesulide 100 mg BD.

Best corrected visual acuity was 6/6 [Figure 2] and IOP on follow-up visits was normal with the use of antiglaucoma medications. Her random blood sugar was done on follow-up visits, which have been normal to date. She frequently visits the eye OPD with pain, for which she is prescribed lubrication – G. Misty. Her IOP on follow-up visit on 19.5.2014 was 22.4 mmHg in both eyes, VA was 6/6, and fundus examination revealed temporal disc pallor and an inactive hypopigmented lesion superior to the inferior temporal arcade and on the macula,

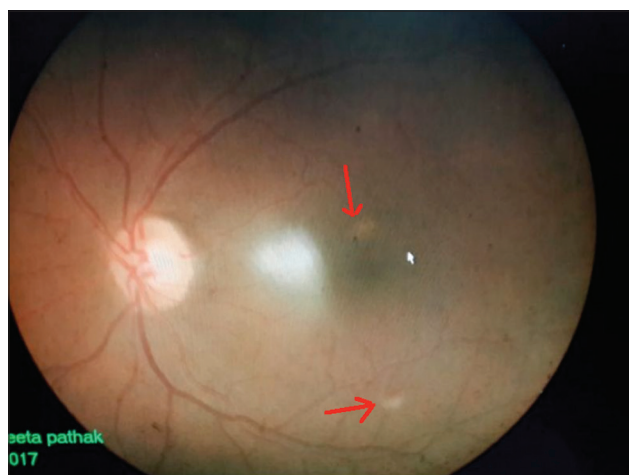
which were probably due to quiescent prior localized neuroretinitis [Figure 3].



**Figure 1.** Diffuse scleritis in the superotemporal part of the left eye superior to the limbus.



**Figure 2.** Slit lamp examination after extra capsular cataract extraction showing vertically oval dilated pupil.



**Figure 3.** Fundus-hypopigmented lesion superior to the inferior temporal arcade and on the macula, with macular hyperpigmentation.



## DISCUSSION

The exact pathogenesis of other ocular ophthalmic zoster complications is poorly understood but clearly involves viral replication in the early stages and then the inflammatory response.<sup>[4]</sup>

Systemic antiviral agents reduce the complications of ocular disease and should be prescribed for all patients with HZO. If possible, treatment should begin within 72 hours of the onset of herpetic infection when the cutaneous lesions are active. Oral acyclovir, 800 mg five times daily, is prescribed for 7 to 10 days. Valcyclovir, Famcyclovir may also be used.

Acutely elevated IOP occurs when keratitis and uveitis complicate herpes zoster. The incidence of secondary glaucoma ranges from 16% to 56%;<sup>[5]</sup> In this report, uveitis and glaucoma occurred early in the course of HZO, which in most cases was responsive to treatment with glaucoma medication and topical corticosteroids. Filtration surgery is required by 15% of patients when medication does not control IOP.

Topical corticosteroid medication plays an important role in preventing active inflammation from clogging or swelling of the trabecular meshwork. When IOP responds rapidly to the application of corticosteroids, one may conclude that trabeculitis plays a role in the glaucoma. Concern about a possible steroid-induced increase in IOP should not take precedence over appropriately aggressive corticosteroid treatment for active intraocular inflammation. Aqueous suppressant medication is the mainstay of medical therapy. If maintenance of corticosteroid treatment is warranted, glaucoma treatment is escalated as needed to protect the optic nerve and avoid vision loss.

Secondary cataract can result from uveitis or prolonged topical or systemic corticosteroid therapy. The cataracts of HZO are typically posterior subcapsular in location.

An infectious cause is responsible for approximately 5-10% of cases of anterior scleritis. The outcome of infectious scleritis is generally worse than with non-infectious scleritis, with only 40% of eyes retaining vision better than 20/200 after treatment.<sup>[6]</sup>

Scleromalacia is a rare complication of HZO.<sup>[7,8]</sup> To our knowledge, there are three reported cases of scleromalacia,<sup>[7,8]</sup> following HZO in the literature. Scleromalacia following HZO was preceded by episodes of acute or possibly chronic scleral inflammation.<sup>[9]</sup> Several mechanisms are thought to play a role on the sclera and may well result in scleral wall weakness.<sup>[10]</sup>

After the infection subsides, most patients suffer constant or intermittent discomfort or pain for a period of time in the distribution of their rash, called postherpetic neuralgia. Various systemic analgesics and antiinflammatory, antidepressant, and anticonvulsant medications may be used to address this complication,

which may last for many months and be difficult to control.

In a study including 33 cases of HZO, secondary inflammatory glaucoma 2 (6.06%) cases, secondary complicated cataract 2 (6.06%) cases, post herpetic neuralgia 2(6.06%) cases.

In a series of 172 patients with scleritis, only two had scleritis secondary to herpes zoster infection.<sup>[11]</sup> In a study of 85 patients with lipid keratopathy referred to the Western Ophthalmic Hospital, London, an accurate follow-up of more than one year after surgery was available in 17 cases. Thirteen patients achieved 6/12 or better corrected visual acuity.<sup>[12]</sup>

In a 74-year-old white woman with HZO-associated corneal scarring and mature cataract, visual rehabilitation was accomplished with a Type I Boston keratoprosthesis (KPro) and concurrent extracapsular cataract extraction and P.C.I.O.L placement. The patient's uncorrected VA improved to 20/25; a follow-up of 7 months is available.<sup>[13]</sup>

Although the ocular complications of HZO have been described earlier, no case has been described so far in literature in which a favorable outcome of >20 years in the management of HZO induced scleritis, complicated cataract, secondary glaucoma, and post-herpetic neuralgia. Complicated cataract due to HZO had good surgical prognosis with ECCE both in immediate and long-term follow-up if intraocular inflammation is well managed. There should not be any hurry for surgery, as early surgical intervention will lead to aggravation of the existing condition and the fear of preoperative and postoperative complications associated with inflammation.

In summary, we report a rare case of long-term (exceeding 20 years) favorable prognosis for management of HZO induced scleritis, complicated cataract with secondary glaucoma, and postherpetic neuralgia. Many ophthalmologists are apprehensive about operating on eyes that have been affected by HZO because they fear pre-and postoperative complications associated with inflammation. Cases of HZO, if managed properly, can yield a favorable outcome. In the present study, the patient underwent ECCE, and her present vision is 6/6. Secondary glaucoma was managed medically, and her IOP is now well controlled.

## Acknowledgment

The authors would like to thank the entire ophthalmology department who worked as a team in making the diagnosis and assisting the various procedures done for the patient.

## Financial Support and Sponsorship

Nil.

## Conflicts of Interest

There are no conflicts of interest.

## REFERENCES

1. Katz J, Cooper EM, Walther RR, Sweeney EW, Dworkin RH. Acute pain in herpes zoster and its impact on health-related quality of life. *Clin Infect Dis* 2004;39:342-348.
2. Marsh RJ, Cooper M. Ophthalmic herpes zoster. *Eye (Lond)* 1993;7(Pt 3):350-370.
3. Thean JH, Hall AJ, Stawell RJ. Uveitis in Herpes zoster ophthalmicus. *Clin Experiment Ophthalmol* 2001;29:406-410.
4. Womack LW, Liesegang TJ. Complications of herpes zoster ophthalmicus. *Arch Ophthalmol* 1983;101:42-45.
5. Panek WC, Holland GN, Lee DA, Christensen RE. Glaucoma in patients with uveitis. *Br J Ophthalmol* 1990;74:223-227.
6. Duke Elder S. Textbook of Ophthalmology. Vol. 2. London: Kimpton; 1938. p. 1904.
7. Dugmore W. Intercalary staphyloma in a case of herpes zoster ophthalmicus. *Br J Ophthalmol* 1967;51:350-351.
8. Jallet G, Lecuyer J, Béchetoille A. A rare complication of ophthalmic zona: Scleral perforation with hernia of the ciliary body. *Bull Soc Ophthalmol Fr* 1977;77:489-490.
9. Hedges TR 3<sup>rd</sup>, Albert DM. The progression of the ocular abnormalities of herpes zoster. Histopathologic observations of nine cases. *Ophthalmology* 1982;89:165-177.
10. Livir-Rallatos C, El-Shabrawi Y, Zafirakis P, Pellett PE, Stamey FR, Foster CS. Recurrent nodular scleritis associated with varicella zoster virus. *Am J Ophthalmol* 1998;126:594-597.
11. Gahl WA, Thoene JG, Schneider JA. Cystinosis. *N Engl J Med* 2002;347:111-121.
12. Marsh RJ, Cooper M. Ocular surgery in ophthalmic zoster. *Eye (Lond)* 1989;3(Pt 3):313-317.
13. Todani A, Gupta P, Colby K. Type I Boston keratoprosthesis with cataract extraction and intraocular lens placement for visual rehabilitation of herpes zoster ophthalmicus: The "KPro Triple". *Br J Ophthalmol* 2009;93:119.

Archive of SID

# SID



سرویس های ویژه



سرویس ترجمه تخصصی



کارگاه های آموزشی



بلاگ مرکز اطلاعات علمی



عضویت در خبرنامه



فیلم های آموزشی

## کارگاه های آموزشی مرکز اطلاعات علمی جهاد دانشگاهی



کارگاه آنلاین آشنایی با پایگاه های اطلاعات علمی بین المللی و ترند های جستجو



مباحث پیشرفته یادگیری عمیق؛ شبکه های توجه گرافی (Graph Attention Networks)



کارگاه آنلاین مقاله نویسی IEEE و ISI ویژه فنی و مهندسی