

# SID



سرویس های ویژه



سرویس ترجمه تخصصی



کارگاه های آموزشی



بلاگ مرکز اطلاعات علمی

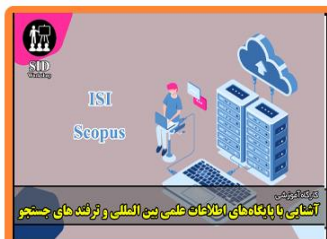

عضویت در خبرنامه



فیلم های آموزشی

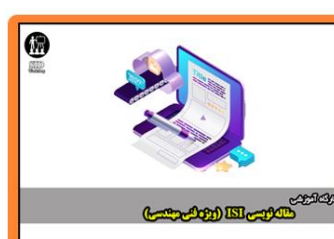## کارگاه های آموزشی مرکز اطلاعات علمی جهاد دانشگاهی



کارگاه آنلاین آشنایی با پایگاه های اطلاعات علمی بین المللی و ترند های جستجو



مباحث پیشرفته یادگیری عمیق؛ شبکه های توجه گرافی (Graph Attention Networks)



کارگاه آنلاین مقاله نویسی IEEE و ISI ویژه فنی و مهندسی

## Original Article

# Long-term Outcomes of Amniotic Membrane Transplantation in Contact Lens-Induced Pseudomonas Keratitis with Impending Corneal Perforation

Mehrdad Mohammadpour, MD; Fatemeh Alsadat Sabet, MD, MPH

Eye Research Center, Farabi Eye Hospital, Tehran University of Medical Sciences, Tehran, Iran

### Abstract

**Purpose:** To report the anatomical and visual outcomes of double layered amniotic membrane transplantation (AMT) in eyes with advanced Pseudomonas keratitis leading to Descemetocoele formation.

**Methods:** This prospective interventional case series included 6 eyes of 6 female patients with pseudomonas keratitis caused by contact lens-induced infection who underwent double layered AMT. Surgery was performed after the ulcers were found to be poorly responsive to antibiotics, and severe thinning or Descemetocoele had developed. All patients underwent a complete examination pre- and postoperatively, as well as anterior segment optical coherence tomography (OCT) and pachymetry or Orbscan after the procedure.

**Results:** Mean follow-up period was 24 months. There was neither frank corneal perforation nor a need for emergent corneal transplantation in any of the eyes. All patients had visual acuity of hand motions before the procedure which improved to 20/50 to 20/30 three months after surgery. No surgical or postoperative complication occurred in this series.

**Conclusion:** Double layered AMT may result in acceptable anatomical outcomes in patients with advanced Pseudomonas keratitis with Descemetocoele formation and can eliminate the need for emergent corneal transplantation.

**Keywords:** Amniotic Membrane Transplantation; Pseudomonas Keratitis; Optical Coherence Tomography

*J Ophthalmic Vis Res* 2016; 11 (1): 37-41.

### INTRODUCTION

Bacterial infections of the cornea necessitate emergent management because without proper treatment they can lead to grave complications such as Descemetocoele formation, corneal perforation, glaucoma, cataract,

endophthalmitis and even loss of vision. The condition is more problematic when the infection is caused by certain micro-organisms such as *Pseudomonas aeruginosa*, which is usually associated with wearing contaminated contact lenses. This organism can damage the cornea due to excessive proteolytic activity mediated by its toxins and enzymes.<sup>[1,2]</sup>

Interventions used for descemetocoeles, including tissue adhesives and glues, bandage contact lenses, and lamellar or penetrating keratoplasty, are not effective in approximately half of such cases.<sup>[3]</sup> Amniotic membrane

#### Correspondence to:

Mehrdad Mohammadpour, MD. Associate Professor of Ophthalmology, Eye Research Center, Farabi Eye Hospital, Tehran University of Medical Sciences, Qazvin Square, Tehran 13366, Iran.

E-mail: mahammadpour@yahoo.com

Received: 09-03-2015

Accepted: 09-09-2015

#### Access this article online

##### Quick Response Code:



Website:  
[www.jovr.org](http://www.jovr.org)

DOI:  
10.4103/2008-322X.180712

This is an open access article distributed under the terms of the Creative Commons Attribution-NonCommercial-ShareAlike 3.0 License, which allows others to remix, tweak, and build upon the work non-commercially, as long as the author is credited and the new creations are licensed under the identical terms.

For reprints contact: [reprints@medknow.com](mailto:reprints@medknow.com)

**How to cite this article:** Mohammadpour M, Sabet FA. Long-term outcomes of amniotic membrane transplantation in contact lens-induced pseudomonas keratitis with impending corneal perforation. *J Ophthalmic Vis Res* 2016;11:37-41.

transplantation (AMT) is an alternative method which can be used to treat acute cases of inflammatory descemetocele when the risk of corneal graft rejection is high.<sup>[4]</sup> Amniotic membrane has several biologic features including anti-microbial, anti-inflammatory and anti-proteolytic effects which may be beneficial in patients with corneal ulcers.<sup>[4]</sup> However, this membrane may also act as a barrier and decrease antibiotic penetration.<sup>[5]</sup>

There are three different surgical methods for amniotic membrane transplantation. In first method, the so-called "inlay or graft technique", the amniotic membrane is used as a scaffold for epithelial cell migration and better re-epithelialization. The membrane may also be used as an overlay or patch technique. In the third method, the membrane is sutured to the intact edges of the lesion and based on the depth of perforation, single or multilayered transplantation are performed.<sup>[6]</sup> Previous studies have not determined long term restoration of corneal thickness and anatomy after AMT for corneal descemetoceles.

The current case series aims to describe the healing process of corneal descemetoceles in patients who underwent double-layered AMT for Pseudomonas keratitis using micrometric imaging methods including anterior segment optical coherence tomography (OCT) and corneal pachymetry map or Orbscan.

## METHODS

This prospective interventional case series study was performed from June 2010 to December 2012. We report the results of AMT on 6 eyes of 6 patients referred to

Farabi Hospital, Tehran University of Medical Sciences, Tehran, Iran. All affected subjects were female patients who were admitted with a diagnosis of corneal thinning and descemetocele formation due to bacterial keratitis [Table 1]. The risk factor for corneal ulcer was use of cosmetic contact lenses. They reported not to follow hygienic standards completely. Only case #4 who was a medically prescribed contact lens wearer reported complete adherence to contact lens hygiene.

All patients had been treated with empirical topical broad-spectrum antibiotics emergently. Bacterial culture and antibiograms were performed in all patients at our center using a standard method, and appropriate antibiotic therapy was commenced based on the results. Pseudomonas aeruginosa was confirmed after scraping and culture in all subjects. The appropriate topical antibiotic<sup>[7]</sup> was applied at least one week prior to surgery.

The indication for surgery was corneal descematocele formation and impending corneal perforation despite intensive treatment with fortified antibiotics. All patients were operated by the same surgeon and with the same method using double-layered AMT. Preoperative examinations in all patients included Snellen visual acuity, refraction (if possible after acute phase when inflammation was resolved.), slit lamp biomicroscopy and indirect ophthalmoscopy for both eyes.

The study was approved by Institutional Review Board at Tehran University of Medical Sciences and adhered to the principles of the Declaration of Helsinki. The operation and informed consent was signed by all patients who were counseled regarding the surgical method and possible complications.

**Table 1. Demographic data and pre- and postoperative characteristics of patients with Pseudomonas keratitis with impending corneal perforation**

No	Age (y)	Gender	Eye	Diagnosis	Pre-op Visual acuity	Antibiotic therapy	Surgery	Post-op visual acuity	Post-op findings
1	24	Female	OD	Pseudomonas keratitis with impending perforation (central ulcer + descemetocele 7.8×7.9*)	HM	Cefazolin, Ceftazidime	Double layer AMT + blepharorrhaphy	20/30	Completely healed epithelium, fading deep corneal scar
2	44	Female	OS	Pseudomonas keratitis, advanced thinning 3×3*	HM	Ceftazidime, Amikacin	AMT + blepharorrhaphy	20/40	Completely healed epithelium
3	21	Female	OS	Pseudomonas keratitis central thinning 4×4*	HM	Ceftazidime, Amikacin	AMT + blepharorrhaphy	20/40	Completely healed epithelium
4	19	Female	OD	Pseudomonas keratitis advanced thinning 5×5*	HM	Ceftazidime, Amikacin	AMT + blepharorrhaphy	20/50	Completely healed epithelium
5	37	Female	OD	Pseudomonas keratitis advanced thinning with pseudo-ptyergium	HM	Ceftazidime, Amikacin	AMT + blepharorrhaphy and injection of bevacizumab because of neovasculariation <sup>[8,9]</sup>	20/50	Completely healed epithelium and resolution of neovascularization
6	21	Female	OD	Pseudomonas keratitis partially central corneal ulcer 3×3*	HM	Cefazoline, Ceftazidime	AMT + blepharorrhaphy	20/50	Completely healed epithelium

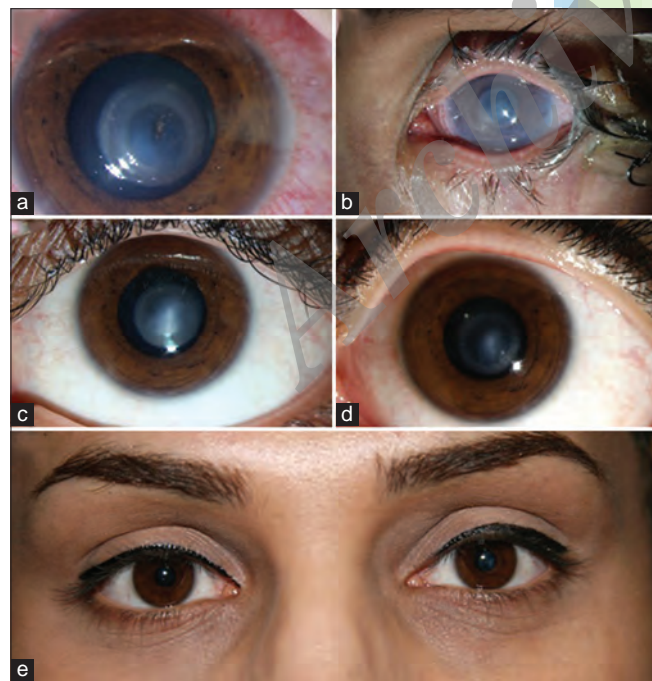
Op, operation; OD, oculus dexter; OS, oculus sinister; HM, hand motions; y, year; AMT, amniotic membrane transplantation. \*Measurements are in mm<sup>2</sup>

All procedures were performed under topical anesthesia using tetracaine eye drops. The necrotic edges of the stromal ulcer were debrided and two layers of amniotic membrane were sutured to the intact borders of the ulceration with the stromal side of the membrane down. Afterwards, a layer of amniotic membrane was sutured to the limbus as graft using a single running 10-0 nylon suture. Then the eye was patched at the conclusion of surgery.

After the operation, all patients were recommended to use antibiotic (Gentamycin 0.3% drop 3 times a day for 14 days) and steroid drop (Prednisolone Sodium Phosphate 1%, 4 times a day that was tapered down during 2 months) until complete resolution of inflammation. The initial examination was performed after admission and the complete pre-operative examination started 48 hours after the acute phase. The post-operative examination included Snellen E-chart visual acuity test, refraction, slit lamp biomicroscopy to verify the progression of re-epithelialization, indirect ophthalmoscopy, OCT (Visante Anterior Segment OCT, Carl Zeiss Meditec, Dublin, California, USA) and corneal pachymetry or orbscan. They were visited 3, 6 and 24-months after operation.

## RESULTS

The surgery was performed in less than one week after admission and patients were under close observation



**Figure 1.** Amniotic membrane transplantation (AMT) in case #3. The photographs show progression of treatment: (a) Preoperatively; (b) immediately after the operation; (c) 3 months after surgery; (d) 24 months post-operation; (e) general appearance two years after transplantation.

post-operatively at hospital for almost 7 days. There was no corneal perforation and none of the patients needed emergency corneal transplantation. All patients had visual acuity of hand motions before surgery which improved to 20/50 to 20/30 three months after the procedure. No surgical or postoperative complication occurred in this study [Table 1].

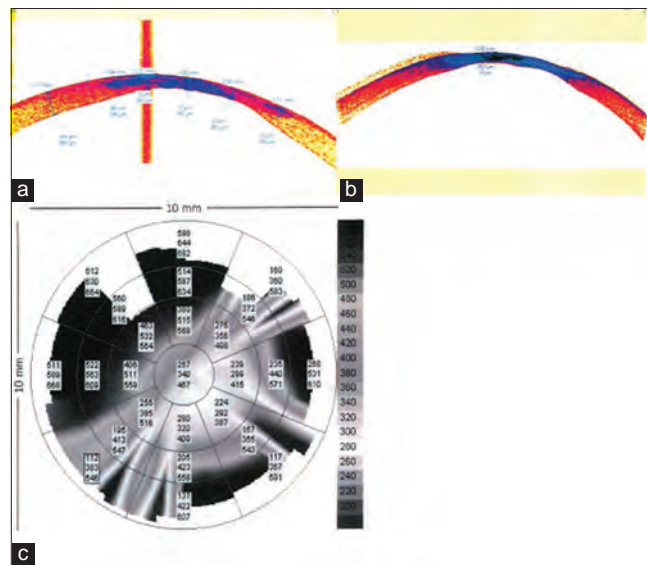
## Representative Cases

### Case #3

This 21-year-old female subject was hospitalized for pseudomonas keratitis. Past medical history was unremarkable. Examination revealed mild left scleral edema with central corneal thinning measuring  $4 \times 4$  mm. She received sensitivity-confirmed ceftazidime and amikacin eye drops every one hour for one week [Figure 1a]. Postoperative visual acuity was 20/50 three months after surgery and 20/40 after one year without any complication. OCT three months and one year after surgery, and pachymetry one year after surgery showed remarkable healing [Figures 1 and 2].

### Case #4

A 19-year-old female patient with a pseudomonas keratitis in her right eye was admitted. She did not have any systemic diseases and had used contact lenses for medical purposes and was following acceptable hygiene instructions. At presentation, visual acuity was hand motions and examination revealed eyelid swelling with purulent discharge, corneal thinning of about 5 mm in



**Figure 2.** Amniotic membrane transplantation (AMT) in case #3. (a) Optical coherence tomography (OCT) image three months postoperatively; (b) OCT and (c) pachymetry one year after surgery show nearly complete anatomical repair of the cornea.

diameter, with infiltration and injection, without any hypopyon. She was treated with ceftazidime and amikacin every one hour for one week after the antibiogram confirmed sensitivity to these antibiotics. Visual acuity increased to 20/200 and 20/50, respectively, 20 days and three months after AMT. Improvement in corneal thickness and integrity was evident on OCT three and 24 months following surgery, and on Orbscan 24 months after the operation [Figures 3 and 4].

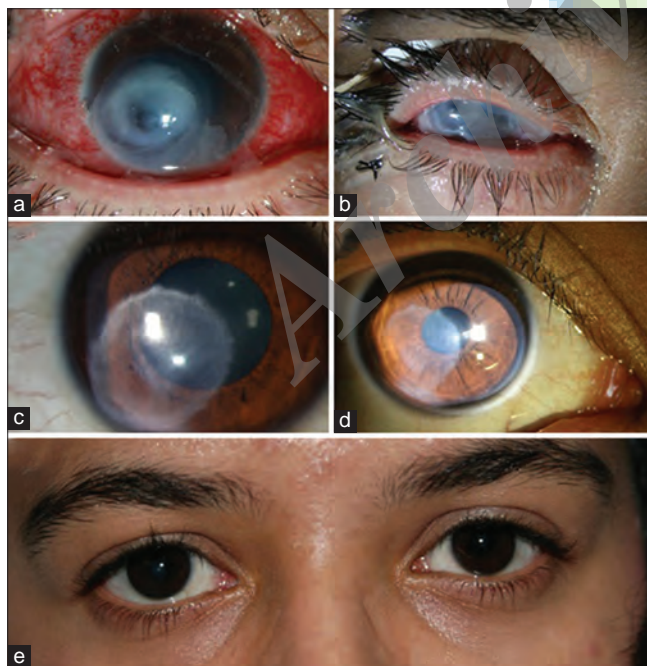## DISCUSSION

AMT is beneficial for preventing corneal perforation caused by corneal thinning and melting in Pseudomonas keratitis.<sup>[2]</sup> It is of high importance to treat patients with appropriate antibiotics before and after transplantation.<sup>[10]</sup> In the present study, broad spectrum antibiotics were administered empirically followed by a more specific medication after sensitivity analysis was obtained. The patients received double-layered AMT and were followed for approximately 2 years. Pre- and post-operative corneal thickness and anatomy were evaluated by anterior segment OCT and pachymetry or Orbscan which demonstrated remarkable progression in corneal healing. Furthermore, all treated eyes obtained final visual acuity of more than 20/50 at final follow-up.

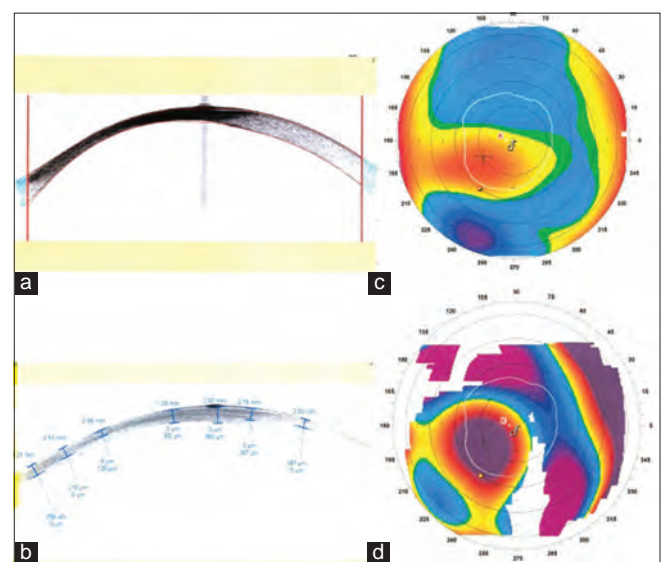
AMT has been used for corneal perforations due to various etiologies with a wide range of clinical outcomes. In spite of the variable results, an improvement

in corneal thinning was reported after AMT.<sup>[11]</sup> The anti-inflammatory and anti-angiogenic properties of amniotic membrane can eliminate the need for urgent keratoplasty which entails a high risk of graft rejection in the setting of acute bacterial ulcers. Chen et al have reported the outcomes of single-layered AMT in a series of patients with impending corneal perforation caused by pseudomonas keratitis. Final maximum visual acuity was 20/100 in this report.<sup>[2]</sup> In another series of patients with herpetic keratitis who received multilayered AMT, visual acuity was improved to a maximum of 20/50.<sup>[12]</sup> Visual acuity of 20/400 to 20/60 was achieved one year after surgery in another study.<sup>[3]</sup> Solomon et al also reported the results of multilayered AMT in 33 cases of non-traumatic corneal ulceration caused by different etiologies including inflammatory diseases and various infections. They concluded that AMT can be effective temporary treatment for corneal descemetocelae or perforations.<sup>[13]</sup> A case series consisting of 12 patients reported no perforation or neovascularization after using double layered AMT in severe bacterial keratitis with various pathogens.<sup>[14]</sup> Recently, a case report of a large corneal perforation which healed with double layered AMT described no surgical complications in an emergency setting.<sup>[15]</sup>

OCT imaging was performed immediately after AMT in one case of severe pneumococcal infection. This report concluded that AMT is a potential alternative to other treatments.<sup>[16]</sup> Additionally, this method was found effective for treating corneal perforations caused by other etiologies such as thermal or chemical burns<sup>[17-19]</sup> or limbal stem cell deficiency.<sup>[20]</sup>



**Figure 3.** Amniotic membrane transplantation in case #4. Progression of treatment: (a) Preoperative appearance; (b) immediately following the operation; (c) three months post operation; (d) 24 months after surgery; (e) general appearance 24 months post-operatively.



**Figure 4.** Amniotic membrane transplantation in case #4. (a) Optical coherence tomography (OCT) 3 months after the operation; (b) OCT 24 months post-operatively; (c) anterior (C) and posterior (d) corneal surface depicted by Orbscan two years after surgery; both imaging modalities show significant amelioration of the Descemetocelae.

Complications have been reported with multilayered AMT. Methicillin-resistant *staphylococcus aureus* can become superimposed on amniotic membrane.<sup>[21]</sup> Additionally, this membrane can act as a barrier against penetration of antibiotics.<sup>[5]</sup> Resch et al report that amniotic membrane reduces ofloxacin penetration and that cryopreservation of the membrane does not improve its permeability.<sup>[5]</sup> In contrast, some other studies have proposed that this membrane acts as a slow releasing reservoir of drugs.<sup>[22]</sup> Overall, the low rate of infections after AMT shows that this modality can result in acceptable outcomes particularly if the membrane preparation method is based on FDA standards.<sup>[23]</sup> In our study, no super-infection occurred following AMT.

In summary, this case series reported good postoperative visual outcomes, improvement in corneal thickness documented by OCT and pachymetry, and absence of complications after double layered AMT in Pseudomona keratitis.

### Financial Support and Sponsorship

Nil.

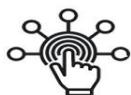### Conflicts of Interest

There are no conflicts of interest.

### REFERENCES

- Sheha H, Liang L, Li J, Tseng SC. Sutureless amniotic membrane transplantation for severe bacterial keratitis. *Cornea* 2009; 28:1118-1123.
- Chen JHC, Ma DHK, Tsai RJF. Amniotic membrane transplantation for pseudomonal keratitis with impending perforation. *Chang Gung Med J* 2002;25:144-152.
- Ma DHK, Wang SF, Su WY, Tsai RJ. Amniotic membrane graft for the management of scleral melting and corneal perforation in recalcitrant infectious scleral and corneoscleral ulcers. *Cornea* 2002;21:275-283.
- Shimmura S, Shimazaki J, Ohashi Y, Tsubota K. Antiinflammatory effects of amniotic membrane transplantation in ocular surface disorders. *Cornea* 2001;20:408-413.
- Resch MD, Resch BE, Csizmazia E, Imre L, Nemeth J, Revesz P, et al. Permeability of human amniotic membrane to ofloxacin *in vitro*. *Invest Ophthalmol Vis Sci* 2010;51:1024-1027.
- Jhanji V, Young AL, Mehta JS, Sharma N, Agarwal T, Vajpayee RB. Management of corneal perforation. *Surv Ophthalmol* 2011;56:522-538.
- Mohammadpour M, Mohajernejhadfard Z, Khodabande A, Vahedi P. Antibiotic susceptibility patterns of pseudomonas corneal ulcers in contact lens wearers. *Middle East Afr J Ophthalmol* 2011;18:228-231.
- Hashemian MN, Zare MA, Rahimi F, Mohammadpour M. Deep intrastromal bevacizumab injection for management of corneal stromal vascularization after deep anterior lamellar keratoplasty, a novel technique. *Cornea* 2011;30:215-218.
- Mohammadpour M. Deep intrastromal injection of bevacizumab for the management of corneal neovascularization. *Cornea* 2013;32:109.
- Heiligenhaus A, Heinz C, Schmitz K, Tappeiner C, Bauer D, Meller D. Essentials in Ophthalmology, Amniotic Membrane Transplantation for the Treatment of Corneal Ulceration in Infectious Keratitis. Springer. *Cornea and External Eye Disease* 2008;15-36.
- Kim JS, Kim JC, Hahn TW, Park WC. Amniotic membrane transplantation in infectious corneal ulcer. *Cornea* 2001;20:720-726.
- Kruse FE, Rohrschneider K, Voelcker HE. Multilayer amniotic membrane transplantation for reconstruction of deep corneal ulcers. *Ophthalmology* 1999;106:1504-1511.
- Solomon A, Meller D, Prabhasawat P, John T, Espana EM, Steuhl KP, et al. Amniotic membrane grafts for nontraumatic corneal perforations, descemetocelles, and deep ulcers. *Ophthalmology* 2002;109:694-703.
- Gicquel JJ, Bejjani RA, Ellies P, Mercie M, Dighiero P. Amniotic membrane transplantation in severe bacterial keratitis. *Cornea* 2007;26:27-33.
- Grau AE, Duraxn JA. Treatment of a large corneal perforation with a multilayer of amniotic membrane and tachoSil. *Cornea* 2012;31:98-100.
- Nubile M, Carpineto P, Lanzini M, Ciancaglini M, Zuppari E, Mastropasqua L. Multilayer amniotic membrane transplantation for bacterial keratitis with corneal perforation after hyperopic photorefractive keratectomy. *J Cataract Refract Surg* 2007;33:1636-1640.
- Shimazaki J, Yang H, Tsubota K. Amniotic membrane transplantation for ocular surface reconstruction in patients with chemical and thermal burns. *Ophthalmology* 1997;104:2068-2076.
- Gris O, del Campo Z, Wolley-Dod C, Guell JL, Velasco F, Adan A. Conjunctival healing after amniotic membrane graft over ischemic sclera. *Cornea* 2003;22:675-678.
- Kim HK, Park HS. Fibrin glue-assisted augmented amniotic membrane transplantation for the treatment of large noninfectious corneal perforations. *Cornea* 2009;28:170-176.
- Tseng SCG, Prabhasawat P, Barton K, Gray T, Meller D. Amniotic membrane transplantation with or without limbal allografts for corneal surface reconstruction in patients with limbal stem cell deficiency. *Arch Ophthalmol* 1998;116:431-441.
- Hori Y, Inoue R, Ikuno Y, Tano Y. Severe methicillin-resistant staphylococcus aureus infection after multilayer amniotic membrane transplantation. *Jpn J Ophthalmol* 2009;53:61-62.
- Resch MD, Resch BE, Csizmazia E, Imre L, Nemeth J, Szabo-Revesz P, et al. Drug reservoir function of human amniotic membrane. *J Ocul Pharmacol Ther* 2011;27:323-326.
- Marangon FB, Alfonso EC, Miller D, Remonda NM, Muallem MS, Tseng SC. Incidence of microbial infection after amniotic membrane transplantation. *Cornea* 2004;23:264-269.

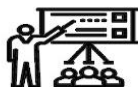# SID



سرویس های ویژه



سرویس ترجمه تخصصی



کارگاه های آموزشی



بلاگ مرکز اطلاعات علمی

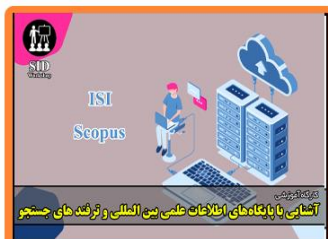

عضویت در خبرنامه

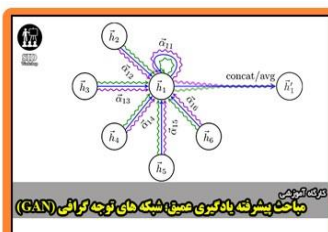


فیلم های آموزشی

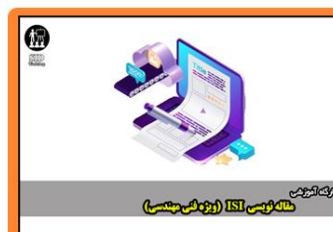## کارگاه های آموزشی مرکز اطلاعات علمی جهاد دانشگاهی



کارگاه آنلاین آشنایی با پایگاه های اطلاعات علمی بین المللی و ترند های جستجو



مباحث پیشرفته یادگیری عمیق؛ شبکه های توجه گرافی (Graph Attention Networks)



کارگاه آنلاین مقاله نویسی IEEE و ISI ویژه فنی و مهندسی