

# Delayed Diagnosis of Alport Syndrome Without Hematuria

Chen Yin-Yin,<sup>1</sup> Peng You-Ming,<sup>2</sup> Liang Yu-Mei<sup>1</sup>

<sup>1</sup>Department of Nephrology, Hunan Provincial People's Hospital, Hunan Normal University, Changsha, China

<sup>2</sup>Department of Nephrology, Second Xiangya Hospital, Renal Research Institute of Central South University, Central South University, Changsha, China

**Keywords.** Alport syndrome, kidney failure, hematuria

Alport syndrome is a progressive hereditary disease caused by mutations in the genes encoding type IV collagen. Persistent microscopic hematuria is the hallmark of Alport syndrome, occurring in almost all boys according to previous reports. We report the case of a 20-year-old man presented with proteinuria but no hematuria that was initially misdiagnosed with refractory nephrotic syndrome and was eventually diagnosed with Alport syndrome following kidney and skin biopsy. During the follow-up period, he experienced a rapid progression to end-stage renal disease. Timely diagnosis of Alport syndrome is important, because patients may benefit from early intervention and avoid suffering from unnecessary nephrotoxic drug use.

IJKD 2014;8:250-1  
www.ijkd.org

## INTRODUCTION

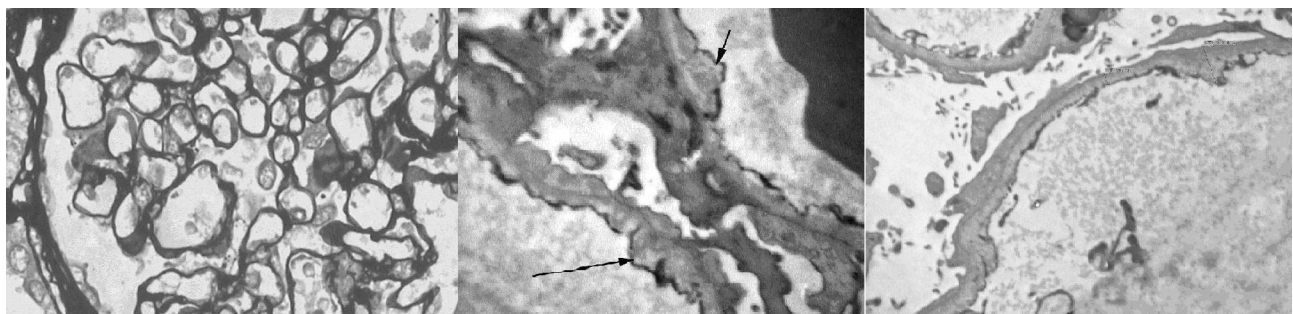
Alport syndrome is a disease caused by mutations in the genes encoding type IV collagen. Hematuria is the hallmark of Alport syndrome, occurring in almost all of the boys with X-linked Alport syndrome and autosomal recessive Alport syndrome.<sup>1</sup> We here report a boy who suffered from delayed diagnosed of Alport syndrome because of the absence of hematuria and had juvenile-onset kidney failure.

## CASE REPORT

A 20-year-old man was referred to our unit because of edema for 6 months. Urinalysis showed proteinuria (3+) and no erythrocytes from the onset of the disease. He was once diagnosed

with refractory nephrotic syndrome at another hospital and was treated with prednisolone and cyclophosphamide. However, the response was unsatisfactory. There was no significant illness in the past. A review of family history revealed that his mother had hearing loss and proteinuria but no kidney impairment.

The patient had generalized edema on examination. Workup revealed proteinuria of 4.6 g/d but no hematuria. Slit lamp examination of the lens was normal. Audiography of the ears revealed mild sensorineural deafness. The light and immunohistochemical features of renal biopsy were suggestive of minimal change disease, but no focal segmental glomerulosclerosis (Figure). Electron microscopy showed alternating zones



**Left,** Light microscopy showed minimal change disease, but no focal segmental glomerulosclerosis. **Middle,** Electron microscopy showed alternating zones of glomerular basement membrane thinning and thickening, splitting, or lamellation. **Right,** Diffuse podocyte foot process effacement was found. These morphologic findings led to the diagnosis of Alport syndrome.

of glomerular basement membrane thinning and thickening, splitting or lamellation. Diffuse podocyte foot process effacement was found. These morphologic findings led to the diagnosis of Alport syndrome (Figure). Because of the absence of hematuria, the most common and earliest manifestation of Alport syndrome, skin biopsies was performed for prudential reasons, which showed interrupted staining for the  $\alpha 5(\text{IV})$  chain. Hence, he was started on a benazepril-based regimen along with furosemidum and aweto. The patient achieved remission. However, the 1-year follow-up showed the patient rapidly progressed to chronic kidney failure (Table).

## DISCUSSION

To date, this is a rare case report of a patient with Alport syndrome without hematuria, whose immunostaining of skin biopsy specimens for  $\alpha 5(\text{IV})$  showed a discontinuous staining pattern, meaning *COL4A5* mutations, which suggests X-linked Alport syndrome.

The mechanisms of phenotype differences such as presenting hematuria or not are multifactorial.<sup>1</sup> In females X-inactivation has been suspected to be a reason for presentation variability.<sup>1,2</sup> In mice, the X-inactivated is influenced by the X controlling element on the X chromosome.<sup>3</sup> Humans do not have an X controlling element locus like the mouse; however, other genes are likely to play a similar role. In males, the clinical presentation is thought to related to mutant *COL4A5* mRNA expression as well as other epigenetic regulation pathways.<sup>2</sup> In the absence of the usual collagen  $\alpha 3\alpha 4\alpha 5(\text{IV})$  network, there may be substitution or compensation by  $(\alpha 1)2\alpha 2(\text{IV})$  network and other matrix proteins. These components contribute to the glomerular filter by imparting appropriate barrier properties

to the glomerular basement membrane, thereby attenuate hematuria.<sup>3</sup> Macroscopic hematuria is fairly common in children with Alport syndrome, but tends to disappear with age. Thickening with age, glomerular basement membrane becomes less susceptible to rupture.

In conclusion, although hematuria is nearly universal, the absence of microscopic hematuria cannot exclude male Alport syndrome. An early diagnosis is important to avoid missing a period during which the maximal benefit from intervention may be derived and avoid unnecessary nephrotoxic drug use.

## CONFLICT OF INTEREST

None declared.

## REFERENCES

1. Jais JP, Knebelmann B, Giatras I, et al. X-linked Alport syndrome: natural history and genotype-phenotype correlations in girls and women belonging to 195 families: a "European Community Alport Syndrome Concerted Action" study. *J Am Soc Nephrol*. 2003;14:2603-10.
2. Rheault MN, Kren SM, et al. X-inactivation modifies disease severity in female carriers of murine X-linked Alport syndrome. *Nephrol Dial Transplant*. 2010;25:764-9.
3. Chadwick LH, Pertz LM, et al. Genetic control of X chromosome inactivation in mice: definition of the Xce candidate interval. *Genetics*. 2006;173:2103-10.

Correspondence to:

Peng You-Ming, MD

Department of Nephrology, Second Xiangya Hospital, Renal Research Institute of Central South University, Central South University, Changsha, China

E-mail: hechenghecheng@gmail.com

Received May 2013

Revised October 2013

Accepted October 2013

## Follow-up Evaluations

Parameter	Date				
	March 2011	June 2011	September 2011	December 2011	May 2012
Blood urea nitrogen, mmol/L	14.7	17.3	20.2	19.8	26.2
Serum creatinine, $\mu\text{mol/L}$	212.8	266.3	379.1	559.4	623.4
Estimated glomerular filtration rate, mL/min/1.73 m <sup>2</sup>	38.0	30.4	21.3	14.4	11
Proteinuria	4+	3+	4.0 g/d	2+	1+
Hematuria	No	No	$\leq 1$ cell/HPF	No	No