

Case Report

Intraosseous Ancient Schwannoma of the Mandible: A Case Report

Shadi Saghafi, Jahanshah Salehinejad, Amin Rahpeyma,
Reza Zare-Mahmoodabadi, Saeedeh Khageh Ahmadi

Dept. of Oral and Maxillofacial Pathology, Faculty of Dentistry and Dental Research Center, Mashhad University of Medical Sciences, Mashhad, Iran

ABSTRACT

Schwannoma (neurilemmoma) is a benign tumor originates from Schwann cells. Ancient (degenerated) schwannoma is a long-standing schwannoma with degenerative changes. Head and neck region is one of the most common sites for nerve sheath tumors but intraosseous schwannoma is rare. The mandible is the most common site of occurrence for this lesion. We report a rare case of intraosseous ancient schwannoma of the mandible in a 27-year-old woman patient. The tumor located in the ramus and angle region.

Key words: Schwannoma, Mandible

Introduction

Schwannoma is a benign encapsulated neoplasm which growth slowly. It originates from Schwann cells, the sheath cells that cover the myelinated nerve fibers (1). It is more common in lower extremities and about 25% of cases occur in the head and neck region (2).

Intraoral schwannomas are rare, particularly in the intraosseous region of the jaw, and less than 1% of tumors occur there. The most common site of occurrence is the mandible (3). Chi in a review of

the English-language literature identified 43 cases of intraosseous schwannoma of the jaws over fifty years. Only five cases were in the maxilla and others were in the mandible (4).

Ancient schwannoma is a rare variant long-standing schwannoma with degenerative changes. It was first described by Ackerman and Taylor in 1951(5). Subhashraj reviewed only nine cases of intraoral ancient schwannoma until Jan 2009 and no case of intraosseous mandibular ancient schwannoma has been identified(6). The predilection of schwannoma to the mandible is due

Received: 21 June 2010

Accepted: 10 October 2010

Address communications to: Dr. Jahanshah Salehinejad, Department of Oral and Maxillofacial Pathology, Faculty of Dentistry and Dental Research Center, Mashhad University of Medical Sciences, Mashhad, Iran

Email: salehinejadj@mums.ac.ir

to presence of a canal that transmits a neurovascular bundle of comparable length and diameter (4).

This article presents a case of intraosseous ancient schwannoma in the posterior region of mandible, which is quite rare.

Case Report

In Jan 2008, a healthy 27- year-old woman admitted to the Department of oral surgery in the Mashhad Dental School with a swelling in the left mandible angle without pain, tenderness, or limitation in mouth opening. She had noticed the problem from two years ago. A multilocular radiolucent lesion in the left mandible, ramus and angle region was seen on panoramic radiograph that destroyed bone around the root of teeth #17 and #18 (universal system). There was no root resorption and remaining fine septas were present in radiolucent lesion (Fig.1).

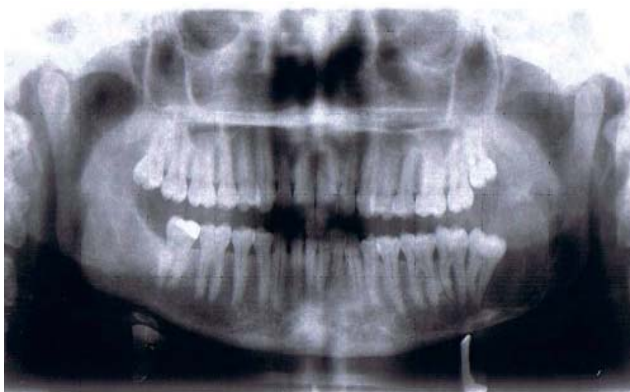


Fig.1: A panoramic radiograph shows a multilocular radiolucency in the left mandible (arrows).

In CT scan that was taken before any biopsy, there was marked expansion and thinning of cortex. There was some speckled fine calcification in the lesion (Fig.2). The clinical diagnosis was ameloblastoma and myxoma. An initial diagnostic incisional biopsy indicated, the lesion could be an ancient schwannoma.

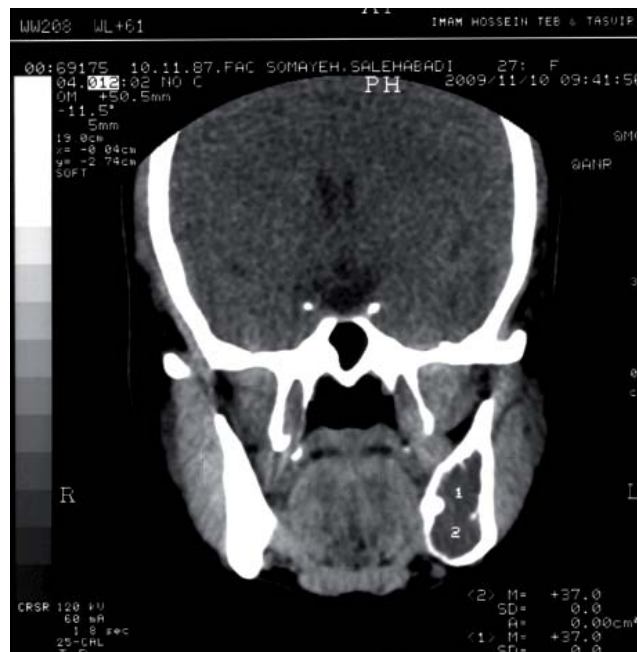

Fig.2: CT scan showing marked expansion and thinning of cortex on the left side of mandible

Under general anesthesia with intraoral approach by retromolar incision and blunt dissection accessed to the lesion. Overlying thin buccal bone was removed with large round bur. The tumor was curetted and after discover of inferior alveolar nerve (IAN), it was dissected from the lesion (Fig.3). The specimen was sent to the Pathology Department, and microscopic examination revealed benign proliferation of Schwann cells in a fibrous stroma with myxoid changes. There were some foci composed of many atypical cells containing hyperchromatic and pleomorphic nuclei. Capillaries of various sizes, infiltration of inflammatory cells and foci of calcification were present (Fig.4).

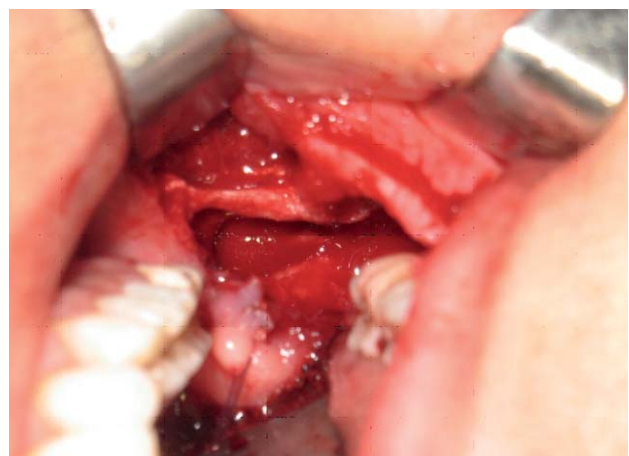
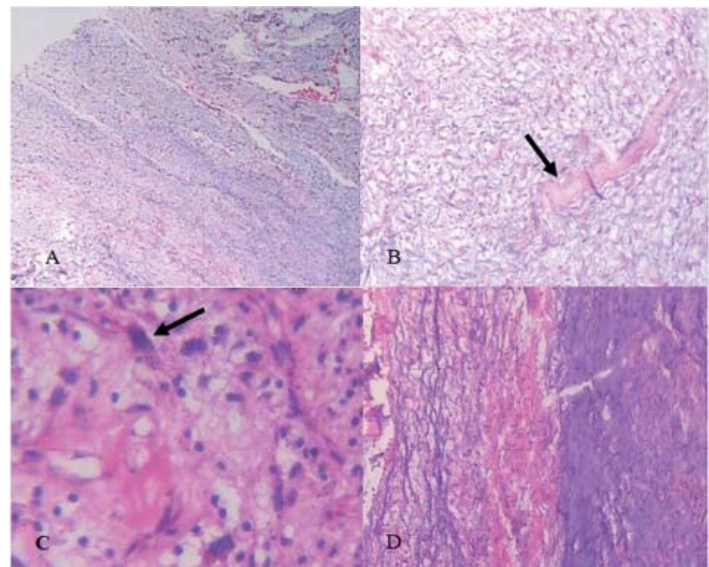


Fig. 3: Intra-operative photograph showing preservation of the involved nerve

Fig.4: Photographs show A: proliferation of Schwann cells in a fibrous stroma ($\times 40$). B: Myxoid changes and hyalinization is also seen (arrowhead) ($\times 100$).C: atypical cells containing hyper chromatic and pleomorphic nuclei (arrow head) ($\times 400$).D: Calcification ($\times 40$). (H&E staining)



An immunohistochemical stain for S-100 protein was done that was strongly positive (Fig.5). These findings were compatible with a diagnosis of ancient schwannoma.

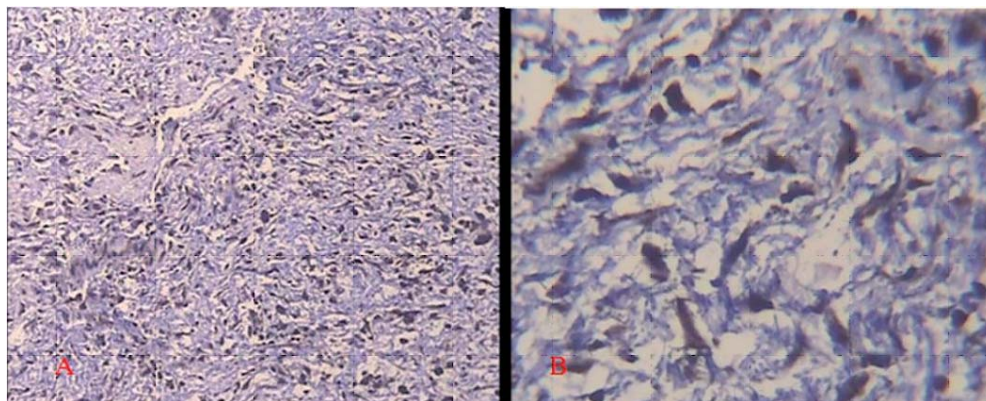


Fig. 5: Intense positive staining for S-100 protein in the spindle-shaped cells. (Immunohistochemical stain with anti S-100 protein antibody, original magnification A: $\times 100$, B: $\times 400$)

Patient was follow up for 9 months and in her last graph, there was bone healing and no clinical sign of recurrence.

Discussion

Schwannoma is a benign neurogenic tumor that arises from Schwann cells of peripheral nerve sheaths. Clinically tumor may be present for years before becoming symptomatic (1). Ancient schwannoma is a long standing Schwannoma with degenerative changes. It rarely affects the head and neck area and intraoral lesions are even rare. Eversole and Howell reported the first ancient schwannoma of head and neck region in 1971(7).

Intraosseous schwannomas are very rare .In jaws, mandible is more common affected, particularly in

the posterior segment of the body and ramus (1, 3). In 39 cases of intraosseous schwannoma of the mandible reviewed by Chi, 28cases were localized on the posterior body/ascending ramus region (4).

Degenerative changes in ancient schwannoma including cystic, necrosis, xanthomatous change, fibrosis, perivascular hyalinization, calcification, and degenerative nuclei with pleomorphism and hyperchromasia. These degenerative features are attributed to the increase in tumor size and aging of the tumor (8).

Ancient schwannomas are benign, slow-growing tumors with rare malignant transformation but

nuclear atypia and hyperchromasia lead to confusion this tumor with malignancy (MPNST) (8). Dahl in 1977 reported that from 11 ancient schwannomas, 6 cases were misdiagnosed as sarcoma (9). And may also misdiagnosed with myxoid neurofibroma and nerve sheath myxoma.

Increase in the size of the schwannoma over time could result to vascular insufficiency, leading to areas of tumor degeneration (8). Our case was a large intraosseous schwannoma that extends from lingula to second mandibular molar.

There is a female predilection for schwannoma and the majority of tumors arise between the age 10 and 40 years (10). Chi reported that the average age for patients with mandibular schwannoma was 34 years (4).

Radiological findings for intraosseous schwannomas are often non-specific and show well-defined unilocular or multilocular radiolucencies that may resemble odontogenic cysts or ameloblastoma. CT scan can be helpful in correct preoperative diagnosis (11).

In our case, clinical, radiographic and surgical finding were similar to ameloblastoma or myxoma and the correct diagnosis was made after histopathologic examination. The goal of treatment for benign schwannoma is complete excision with preservation of the involved nerve if possible (12).

In surgical treatment of schwannomas because nerve bundles are present in periphery of the tumor, we can conservatively dissect tumor from the nerve. This is more important in schwannoma of the neck, parotid region and mandibular bone to preserve the function of vagus nerve (speaking) facial nerve (facial expression) and inferior alveolar nerve (lip sensation) (2, 5, 6).

In summary, in this report, we described a case of an ancient schwannoma that is extremely rare in intraosseous regions. This could be the second reported case of ancient schwannoma arising in mandible found in a 27 years old female patient. Salehinejad reported the first case (13). Ancient schwannomas are benign and complete resection is usually curative with a good prognosis.

Acknowledgement

Special thanks to Dr. Parviz. Mahmoudi & Dr. A.H.Jafarian. The authors declare that there is no conflict of interests.

References

1. Sufian Z, Mazhar A, Lateef JZ, Rana SK. Intraosseous schwannoma of head of first metatarsal: A rare entity. *Indian J Pathol Microbiol* 2009,52(2):286-8.
2. Bayindir T, Kalcioğlu MT, Kizilay A, Karadag N, Akarcay M. Ancient schwannoma of the parotid gland: a case report and review of the literature. *J Craniomaxillofac Surg* 2006,34(1):38-42.
3. Nakasato T, Katoh K, Ehara S, Tamakawa Y, Hoshino M, Izumizawa M, *et al.* Intraosseous neurilemmoma of the mandible. *AJNR Am J Neuroradiol* 2000,21(10):1945-7.
4. Chi AC, Carey J, Muller S. Intraosseous schwannoma of the mandible: a case report and review of the literature. *Oral Surg Oral Med Oral Pathol Oral Radiol Endod* 2003, 96(1):54-65.
5. Nakano CG, Massarollo LC, Volpi EM, Barbosa Junior JG, Arias V, Ueda RY. Ancient schwannoma of the vagus nerve, resection with continuous monitoring of the inferior laryngeal nerve. *Braz J Otorhinolaryngol* 2008, 74(2):316.
6. Subhashraj K, Balanand S, Pajaniammalle S. Ancient schwannoma arising from mental nerve. A case report and review. *Med Oral Patol Oral Cir Bucal* 2009;14(1):E12-E14.
7. Eversole LR, Howell RM. Ancient neurilemmoma of the oral cavity. *Oral Surg Oral Med Oral Pathol* 1971, 32(3):440-3.
8. Choudry HA, Nikfarjam M, Liang JJ, Kimchi ET, Conter R, Gusani NJ, *et al.* Diagnosis and management of retroperitoneal ancient schwannomas. *World J Surg Oncol* 2009;7:12.:12.
9. Dahl I. Ancient neurilemmoma (schwannoma). *Acta Pathol Microbiol Scand A* 1977,85(6):812-8.
10. Salla JT, Johann AC, Garcia BG, Aguiar MC, Mesquita RA. Retrospective analysis of oral peripheral nerve sheath tumors in Brazilians. *Braz Oral Res* 2009, 23(1):43-8.
11. Zachariades N, Skoura C, Papageorgiou G,

Chrissomali E. Giant ancient neurilemmoma of the cervical region: report of case. *J Oral Maxillofac Surg* 2001;59(6):668-72.

12. Ugokwe K, Nathoo N, Prayson R, Barnett GH. Trigeminal nerve schwannoma with ancient change. Case report and review of the literature. *J Neurosurg*

2005;102(6):1163-5.

13. Salehinejad J, Babazadeh F, Saghafi S, Zare-mahmoodabadi R, Rajaie A. Intra-osseous degenerated neurilemmoma of the mandible in a 23 year-old woman. *J Mash Dent Sch* 2010;33(4):353-60.

Surf and download all data from SID.ir: www.SID.ir

Translate via STRS.ir: www.STRS.ir

Follow our scientific posts via our Blog: www.sid.ir/blog

Use our educational service (Courses, Workshops, Videos and etc.) via Workshop: www.sid.ir/workshop