

Biotinidase Deficiency: A Reversible Neurometabolic Disorder (An Iranian Pediatric Case Series)

How to Cite This Article: Karimzadeh P, Ahmadabadi F, Jafari N, Jabbehdari S, Alaei MR, Ghofrani M, Taghdiri MM, Tonekaboni SH. Biotinidase Deficiency: A Reversible Neurometabolic Disorder (An Iranian Pediatric Case Series). *Iran J Child Neurol*. 2013 Autumn; 7(4):47- 52.

Parvaneh KARIMZADEH MD^{1,2},
Farzad AHMADABADI MD¹,
Narjes JAFARI MD¹,
Sayena JABBEHDARI¹,
Mohammad Reza ALAEE MD^{1,3},
Mohammad GHOFRANI MD^{1,2},
Mohammad Mahdi TAGHDIRI MD^{1,2},
Seyed Hassan TONEKABONI MD^{1,2}

1. Pediatric Neurology Research Center, Shahid Beheshti University of Medical Sciences, Tehran, Iran
2. Pediatric Neurology Department, Mofid Children's Hospital, Shahid Beheshti University of Medical Sciences, Tehran, Iran
3. Department of Pediatric Endocrinology, Pediatric Neurology Research Center, Shahid Beheshti University of Medical Sciences, Tehran, Iran

Corresponding Author:
Jafari N. MD
Mofid Children's Hospital, Shariati Ave, Tehran, Iran
Email: jafareadr@gmail.com, jafari@sbmu.ac.ir

Received: 29-Dec-2012
Last Revised: 10-Mar-2013
Accepted: 23-Apr -2013

Abstract

Objective

Biotinidase deficiency is one of the rare congenital metabolic disorders with autosomal recessive inheritance. If this disorder is diagnosed in newborn period, could be prevented well from mental and physical developmental delay and most of clinical manifestations.

Materials & Methods

The patients were diagnosed as biotinidase deficiency in Neurology Department of Mofid Children's Hospital in Tehran, Iran, between 2009 and 2012 were included in this study. This study was conducted to define the age, gender, past medical history, developmental status, general appearance, clinical manifestations, neuroimaging findings, and response to treatment in 16 patients with biotinidase deficiency in this department.

Results

In clinical presentation, cutaneous lesions were not found in 37% of the patients and 43% patients had not alopecia. 75% patients had abnormal neuroimaging that in 56% of them, generalized brain atrophy and myelination delay were found. Results of the present study showed the efficacy of biotin in early diagnosed patients with seizure and dermatological manifestations. The seizure and skin manifestations were improved after biotin therapy.

Conclusion

According to the results of this study, we suggest that early assessment and diagnosis have an important role in the prevention of disease progression and clinical signs.

Keywords: Biotinidase deficiency; Neurometabolic disorder; Developmental delay; Early diagnosis

Introduction

Biotin is a very important vitamin that found in some foods. It plays an important role as cofactor for pyruvate, propionyl-CoA, beta-methylcrotonyl-CoA and two isoenzymes of acetyl-CoA carboxylase in gluconeogenesis, amino acid catabolism, and fatty acid synthesis (1).

Biotinidase deficiency is a rare and treatable inherited neurometabolic disorder (2) with an estimated incidence of 1:61, 067 population. This disorder in its severe form is much rarer with incidence of 1:137401 (3). Clinical findings of this disorder include neurological (seizure, ataxia, hypotonia, neurodevelopmental delay),

dermatological (eczematous skin rash, seborrheic dermatitis), immunological, ophthalmological, respiratory problems (hyperventilation, apnea and laryngeal stridor), and alopecia (1,4).

Laboratory findings include abnormal organic acids in the urine, metabolic acidosis and elevated lactate and pyruvate levels in blood. Diagnosis can be confirmed by measuring blood biotinidase activity (5,6).

Neuroradiological findings include encephalopathy and cerebral atrophy, cerebral edema and bilateral compensatory ventriculomegaly (4). Neurological, cutaneous and neuroimaging findings can improve or become normal after biotin treatment in biotinidase deficiency (4,7). Some of these symptoms can be cured but some of them remain such as hearing loss, ophthalmic defects and mental retardation (8,9).

Materials & Methods

Patients were diagnosed as biotinidase deficient according to clinical manifestations, developmental milestones, dermatological symptoms, seizures and neuroimaging findings. Diagnosis was confirmed in all the patients based on assessment of biotinidase activity at metabolic disorders reference laboratory in Germany. The results of biotin therapy were assessed in all the patients. The mean dosage of biotin was 5-20 mg/day.

Patients' data were evaluated and categorized as age, gender, development status, general appearance, clinical manifestations, and neuroimaging findings. The data of this observational study were analyzed using descriptive method and no statistical testing was applied.

Results

Sixteen patients were included in this study. They were 7 males and 9 females and the age range was from 1.5 months to 52 months. All patients were offspring of consanguineous marriage, so that in 13 patients, their parents were first cousin and in 3 other patients, their parents were second cousin. Five patients had a history of neonatal hospitalization because of respiratory distress, icter, seizure, or irritability.

13 patients had a history of seizure that most common form of seizures was tonic and myoclonic seizures

(37.5%). In past medical history, one patient had a history of recurrent vomiting and another one had anorexia; two other patients had a history of recurrent respiratory and urinary infections; one of the patients had a history of loss of consciousness attacks; one had bilateral undescended testicles; and two cases had a history of severe restlessness. In physical examination, 10 patients had cutaneous involvement; 3 had erythematous lesions in pre-orifices (oral and anal), one had cradle cap (Seborrheic dermatitis) lesions, and one had erythematous, maculopapular and crusted lesions. 8 patients had alopecia and one of them had blond hair. Weights of 3 patients were less than 5% percentile and 3 other patients had microcephaly (less than 5% percentile). Five patients had motor vision disorders (3 with strabismus and 2 with nystagmus). Hypertonicity was found in 8 patients.

Three patients had abnormal visual evoked potential (VEP) and 4 patients had abnormality in their auditory brainstem response (ABR). In lab data, 8 patients had increased levels of ammonia and lactate. Three cases had high AST and ALT. CBC, VBG (except one patient with acidosis), serum levels of calcium, phosphorus, triglyceride, and cholesterol were normal. Abdominal sonography showed hepatomegaly in one patient. Electroencephalography (EEG) in 6 patients was abnormal and had not special pattern. In neuroimaging data, 12 patients had abnormal neuroimaging that in 9 patients, generalized brain atrophy and myelination delay were found in brain imaging, CT scan showed multiple calcification in 1 case. One patient had left hemiatrophy, two showed dysmyelination in white matter, and one had abnormal signal changes in basal ganglia.

All of the cutaneous and hair symptoms were cured with biotin therapy after 3 to 6 months. Seizure in all patients was stopped (except one patient that in this patient, seizure was decreased).

In 3 patients with vision and hearing disorders, their symptoms decreased (Table 1).

Discussion

The results of this study demonstrated that biotin therapy in patients with biotinidase deficiency can reduce, prevent or improve neurological, dermatological and other manifestations of biotinidase

deficiency. Dermatological manifestations included alopecia, loss of hair color, hypopigmentation, and eczematous and erythematous perioral and perianal papules. These findings are secondary to abnormal fatty acid synthesis because of carboxylase deficiency. Dermatological manifestations responded to administration of biotin 3 to 6 months after initiation of the treatment. The most frequent seizure types in patients with biotinidase deficiency were tonic and myoclonic. Generalized tonic seizures were seen in three patients and myoclonic seizures were seen in three cases and all of them were resolved with biotin therapy. It is important that seizures did not respond to conventional therapies, but had rapid improvement in response to biotin therapy. Cutaneous symptoms and neurodevelopmental delay were also improved after treatment with biotin.

These findings are similar to the results of studies by Wolf and Grunewald et al. that reported biotin therapy in biotinidase deficient infants with seizures (untreatable form of seizures with antiepileptic drugs), cutaneous manifestation, visual and auditory abnormalities, neuroradiological findings such as encephalopathy, and lab data such as elevated blood lactate and pyruvate concentrations is important to reduce these manifestations (1,10). If biotinidase deficient patients do not treated by biotin at early stages or infancy, irreversible neurological damage, dermatological manifestations and other symptoms will progress (11). Symptoms of biotinidase deficiency in this study are similar to previous study that contained cutaneous lesions, alopecia, neurodevelopmental delay, and brain atrophy, but in our study, there were special notices, such as all patients were the offspring of consanguineous marriage. Cutaneous lesions were not found in 6 patients and 7 patients did not have alopecia and symptoms in their hair.

MRI in half of the patients was abnormal. Cutaneous symptoms were cured with biotin therapy, and neurological symptoms such as seizure, vision and hearing impairments improved.

In conclusion, this study demonstrated that using biotin as an early treatment in biotinidase deficiency has a therapeutic effect in patients with this reversible neurometabolic disorder. Our study showed that all

patients were the offspring of consanguineous marriage. Cutaneous lesions were not found in 37% of patients and 43% patients did not have alopecia or any other symptoms in their hair, so absence of these symptoms do not reject the existence of biotinidase deficiency.

Acknowledgments

We thank Wagnester laboratory in Germany for conducting laboratory tests for identifying neurometabolic disorders. We thank Ms. Arezou Kermani - Jalilvand for editing the manuscript. Also, we are grateful to all parents of the patients for their cooperation and permission to publish this study.

Author contributions

PK was responsible for study design and collection and interpretation of clinical data and oversaw all stages of revision and editing. NJ contributed in collection of data and wrote the first draft of this manuscript. Other coauthor was involved in data collection and interpretation. All authors reviewed the draft of this article and agreed to submit of the final version of the manuscript.

Declaration of conflicting interests

None declared.

Funding

The authors received no financial support for the research and publication of this article.

Ethical approval

Institutional ethical approval for the conduct of this study was obtained from the Pediatric Neurology Research Center of Shahid Beheshti University of Medical Sciences, Tehran, Iran. All parents signed a written consent for participation in the study.

Table 1. Patients and Disease Characteristics Before Biotin Therapy in Biotinidase Deficiency Cases

Patients/Index	No.1	No.2	No.3	No.4	No.5	No.6	No.7	No.8	No.9	No.10	No.11	No.12	No.13	No.14	No.15	No.16
Age (Month)	3	48	8	5	3	3	18	15	3	4	10	14	8	4	1.5	52
Sex	F	F	F	M	M	M	M	F	F	F	M	M	F	M	F	F
Neonatal hospitalization	-	restlessness	-	-	-	restlessness	-	-	Restlessness	-	-	-	-	Seizure, icter	-	Respiratory distress
Development	Delay	Delay	Delay	Delay	Delay	Delay	Delay	Regression	Delay	-	Delay	Regression	Delay	Delay	-	Regression
PMH	Bad odor	Recurrent infection	-	-	-	Anorexia LOC attack	-	-	Restlessness	Vomiting	Bilateral UDT	-	-	-	-	Recurrent infection
Skin	Maculopapular diaper rash	Maculopapular	Maculopapular	Maculopapular	Maculopapular	Crusted erythema	-	Maculopapular	Maculopapular	-	-	Skin lesions	-	Erythema	-	-
Hair	Alopecia	-	-	Alopecia	Alopecia	-	-	-	Alopecia	-	Alopecia	Alopecia	Lucid	Alopecia	Alopecia	-
Organomegaly	-	-	-	-	-	-	-	-	-	-	-	-	-	-	-	-
Consanguineous Marriage	First cousin	First cousin	First cousin	First cousin	First cousin	First cousin	First cousin	Second cousin	First cousin	First cousin	Second cousin	First cousin	First cousin	First cousin	second cousin	First cousin
Weight	NI	NI	NI	NI	NI	NI	dec.	NI	NI	dec.	dec.	NI	NI	NI	NI	NI
HC	NI	dec.	NI	NI	NI	NI	NI	NI	dec.	NI	NI	NI	NI	dec.	NI	NI
Eye movement	NI	Strabism	NI	Nystagmus	NI	NI	Nystagmus	NI	NI	NI	NI	NI	NI	Nystagmus	NI	Strabism
Visuality	dec	NI	NI	NI	NI	NI	NI	NI	NI	NI	NI	NI	NI	NI	NI	dec.
Movement Disorder	-	-	-	-	-	Myoclonus	-	Dystonia	-	-	-	-	-	-	-	-
Tonicity	dec	inc.	dec.	inc.	inc.	inc.	inc.	inc.	-	dec.	inc.	inc.	-	-	-	dec.
DTR	NI	NI	NI	inc.	inc.	inc.	inc.	inc.	NI	NI	inc.	NI	NI	NI	NI	dec.
Seizure	Infantile spasm	-	+	+	+	Myoclonic	Resistant partial	-	+	Tonic-myoclonic	Tonic	Myoclonic	-	+	Tonic	+
Lactate	NI	inc.	NI	inc.	inc.	NI	inc.	NI	inc.	inc.	NI	NI	inc.	NI	NI	inc.
Ammonia	NI	NI	NI	NI	NI	NI	NI	NI	NI	NI	NI	NI	NI	NI	NI	NI
Pyruvate	NI	NI	NI	NI	NI	NI	NI	NI	NI	NI	NI	NI	NI	NI	NI	NI
ALT	NI	inc.	NI	NI	NI	inc.	NI	NI	NI	NI	NI	NI	NI	NI	inc.	NI
AST	NI	inc.	NI	NI	NI	inc.	NI	NI	NI	NI	NI	NI	NI	NI	inc.	NI
ABR	Disturbed	Disturbed	NI	NI	NI	NI	NI	NI	NI	NI	NI	NI	NI	Severely disturbed	NI	Disturbed
EEG	Moderate	Mild	NI	NI	NI	NI	NI	NI	Moderate	-	Mild	NI	NI	NI	Mild	Mild
Imaging changes	Myelination delay	Atrophy	-	Atrophy	-	-	Hyper-intensity in white matter on T2 MRI	-	Myelination delay	Myelination delay	Multiple calcification in CT, normal MRI	Severe brain atrophy	Atrophy	Brain atrophy	Left hemi-atrophy, generalized atrophy	Brain atrophy, subdural effusion
VEP	Disturbed	Disturbed	-	NI	NI	NI	NI	Disturbed	Disturbed	NI	NI	NI	NI	Disturbed	NI	NI

Abbreviations: F, female; M, male; NI, normal; dec, decrease; inc, increase; PMH, past medical history; HC, head circumference; DTR, deep tendon reflex; VEP, visual evoked potential; EEG, electroencephalography; Mild, mildly abnormal (involvement <30%); Moderate, moderately abnormal (involvement >30% but not all of the EEG trace)

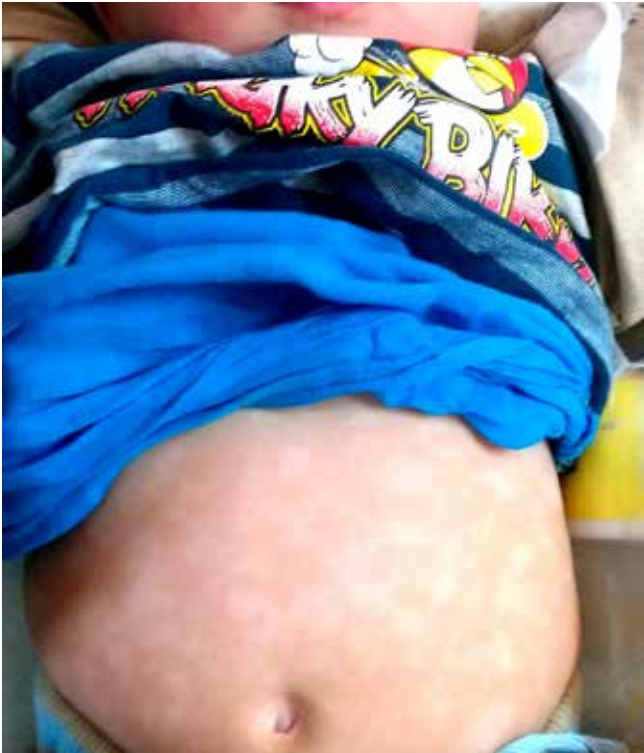

Fig 1. 4 month -Boy- case of biotinidase deficiency pre treatment

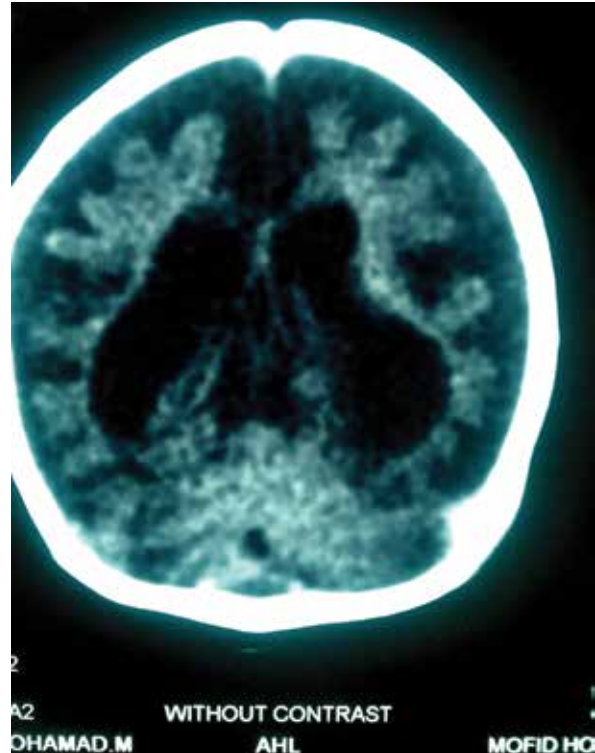


Fig2. Case of biotinidase deficiency-with severe brain atrophy

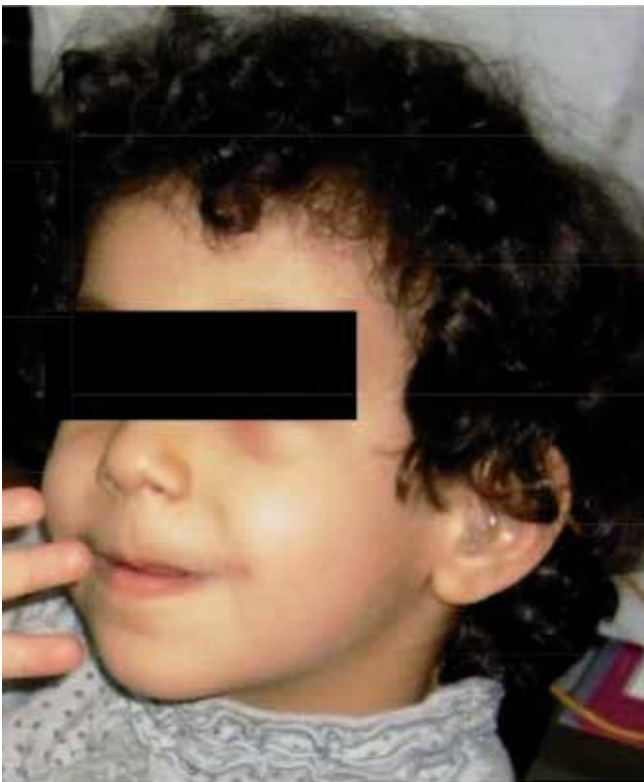

Fig3. 50 month-Girl-case of biotinidase deficiency after treatment

References

1. Wolf B. Disorders of biotin metabolism. In: Scriver CR, Beaudet AL, Sly W, et al., eds. *The Metabolic and Molecular Bases of Inherited Disease*, 8th ed. New York, NY: McGraw-Hill; 2001: 3935-3962.
2. Rathi N, Rathi M. Biotinidase deficiency with hypertonica as unusual feature. *Indian Pediatr.* 2009;46(1):65-67.
3. Wolf B. Worldwide survey of neonatal screening for biotinidase deficiency. *J Inher Metab Dis.* 1991;14(6):923-7.
4. Dahiphale R, Jain S, Agrawal M. Biotinidase deficiency. *Indian Pediatr.* 2008;45(9):777-779.
5. Heard GS, Secor McVoy JR, Wolf B. A screening method for biotinidase deficiency in newborns. *Clin Chem.* 1984;30(1):125-7.
6. Desai S, Ganesan K, Hegde A. Biotinidase deficiency: a reversible metabolic encephalopathy. neuroimaging and MR spectroscopic findings in a series of four patients. *Pediatr Radiol.* 2008;38(8):848-856. Epub 2008 Jun 11.
7. Wolf B. The neurology of biotinidase deficiency. *Mol*

- Genet Metab. 2011;104(1-2):27-34. Epub 2011 Jun 12.
8. Wastell HJ, Bartlett K, Dale G, et al. Biotinidase deficiency: a survey of 10 cases. Arch Dis Child. 1998; 63(10):1244-1249.
 9. Wolf B, Pomponio RJ, Norrgard KJ, et al. Delayed-onset profound biotinidase deficiency. J Pediatr. 1998; 132(2):362-365.
 10. Grunewald S, Champion MP, Leonard JV, et al. Biotinidase deficiency: a treatable leukoencephalopathy. Neuropediatrics. 2004; 35(4):211-216.
 11. Wolf B, Spencer R, Gleason T. Hearing loss is a common feature of symptomatic children with profound biotinidase deficiency. J Pediatr. 2002; 140(2):242-246.

Archive of SID