

# SID



سرویس های ویژه



سرویس ترجمه تخصصی



کارگاه های آموزشی



بلاگ مرکز اطلاعات علمی



عضویت در خبرنامه



فیلم های آموزشی

## کارگاه های آموزشی مرکز اطلاعات علمی جهاد دانشگاهی



کارگاه آنلاین آشنایی با پایگاه های اطلاعات علمی بین المللی و ترند های جستجو



مباحث پیشرفته یادگیری عمیق؛ شبکه های توجه گرافی (Graph Attention Networks)



کارگاه آنلاین مقاله نویسی IEEE و ISI ویژه فنی و مهندسی

# Current Understanding on Pain Mechanism in Migraine and Cluster Headache

Alina Buture,<sup>1\*</sup> Rubesh Gooriah,<sup>1</sup> Randa Nimeri,<sup>1</sup> and Fayyaz Ahmed<sup>1</sup>

<sup>1</sup>Department of Neurology, Hull Royal Infirmary, Hull, UK

\*Corresponding author: Alina Buture, Department of Neurology, Hull Royal Infirmary, Anlaby Road, Hull HU3 2JZ, UK. E-mail: alina.buture@hey.nhs.uk

Received 2015 December 16; Revised 2016 February 15; Accepted 2016 March 02.

## Abstract

**Context:** Migraine and cluster headache are undoubtedly painful conditions. The respective pathogenesis of these two conditions is incompletely understood. In both cases, the treatments used have largely been empirical and have relied to a much lesser extent on our understanding of the mechanisms causing pain. We hereby review the pain mechanisms in migraine and cluster headache, two of the commonest primary headache disorders.

**Evidence Acquisition:** A review of the English literature was conducted by searching PubMed for studies on pain mechanism in migraine and cluster headache. We entered [migraine] and [pain mechanism] in Pubmed and 488 articles were obtained. Articles were then included according to their relevance to the topic. Similarly, [cluster headache] and [pain mechanism] revealed 79 search results.

**Results:** There is evidence that the trigeminovascular system and neurogenic inflammation play important roles, together with certain areas of the brain, leading to these conditions being termed 'neurovascular headaches'. Functional imaging findings suggest a possible role of the dorsolateral pons in generating migraine attacks while the role of the hypothalamus in cluster headache is more firmly established.

**Conclusions:** Migraine and cluster headache have complex pathophysiologies. The exact mechanism causing pain in both conditions is incompletely understood and more research needs to be undertaken in this area.

**Keywords:** Migraine, Cluster Headache, Pain

## 1. Context

Migraine and cluster headaches are primary headache disorders. Migraine is typically characterized by moderate to severe attacks of unilateral pulsating headache, aggravated by routine activity and associated with nausea and/or photophobia and phonophobia (1). The two main sub-types of migraine are: migraine without aura and migraine with aura. Migraine with aura is associated with focal transient neurological deficit such as: visual, speech and/or language, sensory, motor, brainstem or retinal deficit (1). The widely accepted theory suggests that cortical spreading depression (CSD), a wave of neuronal hyperactivity followed by an area of cortical depression, accounts for the aura (2,3). It was previously believed that migraine was associated with cerebral or meningeal vasodilatation. There are no human studies to prove this theory. Schoomman et al. conducted a 3 Tesla magnetic resonance angiography (3T MRA) study on nitroglycerine induced migraine attacks compared with placebo group. During migraine, blood vessel diameters were no different from baseline, nor between headache and non-headache sides (4).

Cluster headache (CH), the commonest of the trigemi-

nal autonomic cephalalgias is one of the most painful conditions an individual can experience (5). CH attacks are characterised by recurrent, severe, unilateral pain which is orbital, periorbital, temporal, or any combination of these sites, lasting 15 - 180 minutes (1). The pain of cluster headache is associated with ipsilateral conjunctival injection, lacrimation, nasal congestion, rhinorrhoea, forehead and facial sweating, miosis, ptosis and/or eyelid oedema, and/or with restlessness or agitation (1). Female patients who suffer from CH attacks describe the pain as 'worse than childbirth' (6). The pain intensity is estimated to be 100 to 1000 times worse than migraine (7). CH has three cardinal features: the distribution of pain in the first division of the trigeminal nerve, the autonomic features and the stereotyped activation.

For a long time, cephalic pain has been considered separate from other forms of pain, and we have therefore witnessed these two research fields develop independently. More recently, it has become evident that several conditions causing prolonged or chronic pain are associated with chronic activation and sensitization of peripheral nociceptors and/or central nociceptive neurons in the dorsal

horn. Integrating these concepts into basic research on migraine pathophysiology, a new animal model for the enduring headache of migraine has been developed. However, the use of laboratory animals and in vitro models is hindered by the fact that no reliable biological markers for the measurement of cephalic pain exist. There is also doubt as to whether experimental animals (e.g. rats or cats) experience headache similar to humans. Therefore, pain studies in humans during migraine or cluster attacks using modern imaging techniques have offered new insights into the pathophysiology of headache. We discuss the pain mechanisms in migraine and cluster headache derived from our understanding of the processes involved in these two conditions and the areas of the brain involved.

## 2. Evidence Acquisition

An electronic search of PubMed for all publications on pain mechanism in migraine and cluster headache was performed. We used the key words: 'pain mechanism migraine', 'pain mechanism cluster headache', 'imaging migraine' and 'imaging cluster headache'. We searched articles published between 1980 and 2015. Relevant studies were included.

## 3. Results

### 3.1. The Trigeminovascular System and the Trigemino-cervical Complex

The trigeminovascular system is the only sensory (afferent) innervation of the cerebral vessels but it also has an afferent function in pathophysiological settings (8). Its cell bodies are located in the trigeminal ganglion and they are bipolar. The peripheral fibers make a synaptic connection with the vessel, and other cranial structures, particularly the pain-producing large cranial vessels and dura mater (9, 10). These fibers are mainly found in the first (ophthalmic) division of the trigeminal nerve and have a widespread ramified network that may innervate several vessels ipsilaterally (11, 12). In both migraine and CH, pain occurs as a result of activation of the trigeminovascular system. This explains the distribution of pain in the ophthalmic division of the trigeminal nerve, which is more characteristic in CH attacks. It is unclear how the migraine attack is triggered but it is thought that CSD can activate the trigeminovascular system.

However, patients with migraine often experience cephalic pain outside the distribution of the ophthalmic division of the trigeminal nerve and sometimes pain at the back of the head, innervated by the greater occipital nerve (GON), can be the sole manifestation. This can be

explained by the convergence of trigeminal and cervical afferents on to neurons in the trigemino-cervical complex (TCC). The TCC is a part of brainstem and includes the caudal part of trigeminal nucleus caudalis and the dorsal horns of C1-C2 segments of spinal cord (13). Migraine attacks are a manifestation of central and peripheral sensitization. The central sensitization hypothesis suggests an altered processing sensory signal in the brainstem, where the neurons of trigemino-cervical (TCC) system become hyperexcitable (14, 15). Once the attack has begun, central neurons can propagate information about the pain process without the need for further external stimuli. The symptoms of central sensitization consist of reduced pain threshold and exaggerated pain response outside the original site of pain (16-18). The most common symptom of central sensitization is a phenomenon called allodynia (19). Cutaneous allodynia represents pain evoked by applying non-noxious stimuli to normal skin (19). Cutaneous allodynia could be evoked by activities such as: shaving, combing the hair, wearing glasses, contact lenses, earrings or tight clothing and might contribute to the transformation of episodic migraine to chronic migraine. Peripheral sensitization depends on the activation of peripheral nociceptors (20). The primary afferent nociceptive neurons express increased responsiveness to external thermal or mechanical stimuli at the site of inflammation or injury (21). Clinically, the peripheral sensitization is associated with the presence of throbbing headache and its aggravation during physical activities that increase the intracranial pressure such as bending over, breath-holding, coughing (21, 22). The sensitization of the nociceptors that innervate the meninges may contribute to such intracranial hypersensitivity (23, 24). The first order neuron in the trigeminal ganglion receives input from the dural blood vessels and the signal is transmitted to the second-order neuron in the trigeminal brainstem nuclear system and therefore to the third-order neuron in the thalamus (25). The clinical expression of first-order-neuron sensitization is the throbbing pain that characterizes migraine attacks (25). When the sensitization spreads to the second-order neuron in the trigeminovascular system scalp sensitivity and allodynia occurs (25). The sensitization of third-order neuron in the thalamus is expressed clinically by extracranial hypersensitivity (24).

In CH, activation of the trigeminovascular system triggers autonomic manifestations through the trigemino-autonomic reflex. The trigeminal nucleus caudalis has a functional brainstem connection with the superior salivatory nucleus (26) from which the parasympathetic efferent fibers of the facial nerve arise. Activation of parasympathetic fibers causes rhinorrhea, lacrimation, and nasal congestion while sympathetic malfunction results in ptosis, miosis. The excessive facial sweating present during CH

attacks is due to sympathetic over activity (27). Parasympathetic activation is mediated through the 7th nerve (28). The fibers originating from the superior salivatory nucleus synapse in the pterygopalatine ganglia. Blockade of the sphenopalatine ganglion is known to relieve the symptoms of CH. The postganglionic fibres innervate the cerebral blood vessels and the lacrimal and nasal glands. High flow-oxygen is an efficient abortive therapy for cluster headache (29). A study on rats conducted by Akerman et al. suggested that oxygen might act on parasympathetic outflow to the cranial vasculature and trigeminovascular system (30).

### 3.2. Neurogenic Inflammation

Neurogenic inflammation refers to a neurally mediated inflammatory response in meningeal tissue characterised by vasodilatation, leakage of plasma protein from blood vessels and mast cell degranulation. Neuropeptides such as calcitonin-gene related peptide (CGRP), substance P (SP) and vasoactive intestinal peptide (VIP) are released when the trigeminal fibres or trigeminal ganglion is activated (31, 32). This release of neuropeptides has been proposed as a pain mechanism in migraine and other primary headaches (33, 34). Histochemical studies on rats have revealed the presence of calcitonin gene related peptide (CGRP) and substance P in small nerve fibers that innervate the dura mater of the rat (35, 36). The nociceptive information is transmitted from meningeal blood vessels to the trigeminal nucleus caudalis through A $\delta$  and C type nerve fibers arising from the trigeminal ganglion (37). The release of CGRP, a powerful vasodilator, from afferent terminals produces dilatation of the dural vessels and an increase in blood flow (35, 38). CGRP immunoreactive fibers are more abundant around the middle meningeal artery (MMA) whereas SP fibers are mostly found around main cerebral arteries (35). Another important mediator in migraine and other primary headaches is VIP. Elevated concentrations of CGRP, SP and VIP have been found in plasma samples during migraine attacks (39-41) and also in attacks of CH (28, 42-44). VIP derives from parasympathetic afferents (41) and raised levels in CH attacks are likely to reflect parasympathetic activation. CGRP is probably the most important of these mediators and this is evidenced by the successful treatment of migraine with antibodies against CGRP (45) and antagonists of its receptor (46, 47). Triptans appear to relieve pain by regulating CGRP levels (48).

CGRP mediates the release of histamine from mast cells and interacts with nitric oxide (NO) (49, 50). NO is another potent vasodilator found in different tissues including meningeal circulation (49, 51). Vasodilation resulting from the interaction between NO and CGRP release may

also play a role in the peripheral sensitization of perivascular afferent fibres (52). The infusion of nitrovasodilators can trigger CH attacks similar to spontaneous attacks, suggesting a role for NO in nociceptive processes (53). There is an obvious link between CGRP, vasodilatation and pain but its exact role during an attack is not yet very clear. While CGRP has a vasodilatory effect, SP and neurokinin A (NKA) increase vascular permeability in response to trigeminal nerve activation (31, 32). SP neurons display unique properties in that impulses may travel either orthodromically or antidromically in the various ramifications of the axons, and that the transmitter may be released both in the central and peripheral ends of the neuron (54). It has been hypothesized that activation of SP neurons in the ophthalmic and maxillary divisions can cause all the symptoms of an acute CH attack, and this could explain the improvement witnessed with blockade of the Gasserian or sphenopalatine ganglia (54).

### 3.3. Functional and Structural Brain Changes

Initial imaging in migraine focused on changes in cerebral blood flow during attacks. Studies by Olesen and Friberg (55) using single photon emission computed tomography (SPECT) revealed a focal reduction of cerebral blood flow for migraine attacks with aura, usually in the posterior parts of one hemisphere. Studies of cerebral blood flow in cluster headache are scarce and the majority has employed SPECT giving variable results. Some have reported an increase, some a decrease and others no differences in cortical blood flow (56). Modern functional imaging techniques have shed light on the regions of the brain involved in migraine and cluster headache, some being more specific to pain than others. These areas are discussed in more detail below.

### 3.4. Migraine

Evidence for the role of the brainstem as a generator has been gathering for some time. Weiller et al. using positron emission tomography (PET) imaging, found that following the administration of sumatriptan succinate in 9 patients during spontaneous migraine attacks, brainstem activation persisted even after sumatriptan had relieved the pain (57). The areas of maximum intensity were around the dorsal midbrain and dorsolateral pons (DLP) (57). A further PET study involving 5 patients who were not taking any migraine prophylaxis revealed significant activation of the dorsolateral pons during spontaneous migraine attacks, further reinforcing the idea that migraine is a subcortical disorder (58). There are proponents for the theory that the origin of migraine headache is in the periaqueductal gray (PAG). This notion gained popularity

when a clinical study in which implantation of stimulating electrodes in the PAG of 175 intractable pain patients resulted in short-lasting (12 patients) or long-lasting (3 patients) post-operative migraine-like headache (59). However, it should be noted that electrical stimulation of the PAG did not trigger a migraine in 174 of the 175 patients and that post-operative headache is usually observed following procedures involving craniectomy (60). Borsook and Burnstein make a good case against the brainstem as a migraine generator, arguing that it is inconceivable that the PAG, which is positioned to modulate pain at all spinal segment levels, would only generate cephalic pain but no pain in other body parts (61). In fact, DLP activation is not specific to migraine and is commonly seen in patients with neuropathic and visceral pain (62). DLP activation also can be present in response to bladder distension (63), changes in heart rate, plasma catecholamines during rectal distention (64) and sympathetic-nerve-related activity (65). These studies showed that the activation of the DLP is not specific to pain either.

Therefore, one of the challenges with PET studies is to differentiate between areas activated by general pain and areas that might be specific for migraine. One approach is to compare areas of activation and deactivation during a migraine attack and after effective abortive therapies. Areas activated during migraine attack are anticipated to be deactivated after triptan therapy whereas areas that generate pain remain active. In addition to the DLP, several other areas of the brain have shown activation on functional imaging. Afridi et al. detected activation in the thalamus, insula, anterior and posterior cingulate gyri, cerebellum, prefrontal cortex and temporal lobes (58). Other areas of increased activation include the red nucleus (66), substantia nigra (66) and hypothalamus (66) while areas of decreased activation include the somatosensory cortex (67), nucleus cuneiformis (61), caudate (68) and putamen (68). However, these regions again do not appear to be specific to migraine and most are generally activated in functional imaging studies on pain and collectively are known as the pain matrix. There is evidence for almost indistinguishable activation patterns in other pain conditions, such as low back pain, neuropathic pain, fibromyalgia, irritable bowel syndrome, and cardiac pain (69). It is therefore possible that the differences between somatic pain and migraine pain are not due to differences in central pain processing. In addition to functional alterations, structural changes have been noted in these areas. A Voxel-based morphometry and diffuse tensor imaging studies revealed gray matter volume reductions in the insula, motor/premotor cortex, prefrontal cortex, cingulate cortex, posterior parietal cortex, and orbitofrontal cortex (70), thickening of the somatosensory cortex (71) and in-

creased gray matter density in the caudate (68).

Functional MRI studies have shown activation of the pulvinar in patients with migraine attacks with extracephalic allodynia (72). The authors concluded that sensitized posterior thalamic neurons mediate the spreading of multimodal allodynia and hyperalgesia beyond the locus of migraine headache (72). Medication overuse headache is a well-known problem in chronic migraine patients. Orbitofrontal cortex (OFC) hypofunction was a consistent finding in patients with medication overuse and after withdrawal of analgesics in a fludeoxyglucose F18 (FDG)-PET study conducted by Fumal et al. (73). The study aim was to test how medication overuse transforms episodic migraine into chronic migraine (73). The hypometabolic areas before withdrawal were the bilateral thalamus, orbitofrontal cortex (OFC), anterior cingulate gyrus, insula/ventral striatum and right inferior parietal lobule, while the cerebellar vermis was hypermetabolic (74). The orbitofrontal cortex was the only structure that did not recover after withdrawal of analgesics. The authors concluded that medication overuse is associated with reversible changes in the chronic pain processing structure, except OFC hypofunction that is seen in patients with drug addiction as well (73). More recently, functional imaging studies have shown activation of posterior/dorsal thalamic areas in spontaneous migraine (74). Animal studies on cats have identified trigeminothalamic projections in the posterior (Po), lateral posterior/dorsal (LP/LD) and ventral posteromedial (VPM) thalamic nuclei (75). Neuroanatomical studies showed that thalamo-cortical projections are defined by their thalamic nucleus of origin (74). Neurons in VPM project in primary, secondary sensory cortices and insula suggesting a role in the location, quality and intensity of pain (74). Contrariwise, thalamic neurons from Po, LP and LD nuclei project to brain areas such as the motor, auditory, olfactory, retrosplenial, ectorhinal, and visual cortices suggesting involvement in motor function, visual and auditory perception, spatial orientation, olfaction, difficulty focusing, transient amnesia, allodynia, common neurological symptoms during migraine (76).

### 3.5. Cluster Headache

Studies conducted by Kudrow et al. were the first to implicate the hypothalamus in the pathogenesis of CH with the demonstration of lower levels of testosterone during a bout (77). This was supported by studies showing observations of disordered circadian rhythm for cortisol, luteinizing hormone, growth hormone, and prolactin (78) and a suppressed nocturnal peak in melatonin is seen during the active phase of a CH (79). Neuroimaging further supports the role of the hypothalamus in CH. PET imaging studies in nitroglycerine-provocation or spontaneous CH have

found activation in the posterior hypothalamic gray matter (80). The activation pattern was not seen in patients with migraine or experimental ophthalmic division head pain, suggesting the involvement of hypothalamus in the pain process (80). Findings from PET studies were supported by Voxel-based morphometric MR imaging that has found significant structural differences in the hypothalamic posterior gray matter compared with controls (81). Sprenger et al. used PET with the opioidergic ligand [11C] diprenorphine on CH patients in and out of a bout and have found decreased tracer binding in the pineal gland, suggesting that the descending opioidergic mechanisms in the pineal gland and hypothalamus may play a role in the generation of cluster headache attacks (82). There is evidence of anatomical connections between the hypothalamus and the trigeminal nucleus (83) and between the hypothalamus and the superior salivatory nucleus (84). The importance of the superior salivatory nucleus activation has been shown in a novel model of TAC (30).

Imaging studies in CH have also implicated other brain areas that are generally associated with the pain matrix. The initial studies used single photon emission computed tomography (SPECT). Di Piero et al. conducted a Xe-133 SPECT study that showed differences in the cerebral blood flow in the contralateral primary sensorimotor and thalamic regions compared to control subjects (85). These findings suggested the involvement of central tonic pain in the pathogenesis of CH. Hsieh et al. conducted a PET study on nitroglycerine-induced CH attacks that showed increased cerebral blood flow in the right caudal and rostrocaudal anterior cingulate cortex (ACC), temporopolar region, supplementary motor area, bilaterally in the primary motor and premotor areas, opercular region, insula/putamen, and lateral inferior frontal cortex (86). The same study showed reduction in cerebral blood flow bilaterally in the posterior-parietal cortex, occipito-temporal region and prefrontal cortex (86). The authors suggested that there is a preference for the non-dominant hemisphere in chronic pain processing (86). A FDG-PET study that measured the cerebral glucose metabolism during and outside the bout showed increased metabolism in the perigenual ACC, posterior cingulate cortex, the OFC, the nucleus accumbens, ventrolateral prefrontal cortex, dorsolateral prefrontal cortex and temporal cortex, and decreased metabolism in the cerebellopontine area (87). The same study revealed hypometabolism in the perigenual ACC, prefrontal and OFC in and out of the CH bout compared with normal group (87). The authors concluded that the hypometabolism in and out of a bout in the PACC, a structure involved in the central descending opioidergic pain control system, may predispose to CH and to its recurrence (87).

#### 4. Conclusions

Migraine and CH are neurovascular disorders with multiple processes and complex pathophysiologies. We have acquired better understanding of the role of the trigeminal vascular system in causing pain in these disorders. However, it is clear that other brain areas and trigeminothalamic projections all have a role to play in migraine. In CH, it is evident that activation of the hypothalamus is the key in generating attacks. Our understanding of the pain mechanisms of these two conditions continues to improve and is crucial for the development of novel treatments. Research in this field, using animal models and the ever-advancing techniques of functional imaging, will undeniably assist in the quest for specific drugs for these painful disorders.

#### Footnotes

**Authors' Contribution:** All authors contributed to manuscript writing and review.

**Financial Disclosure:** Fayyaz Ahmed has received honorarium to deliver training workshops for Allergan paid to the British association for the study of headache (BASH) and has received honorarium to attend Allergan Advisory Board meetings. He is on the standing committee of the headache guidelines (CG150 Revision) for the national institute of clinical excellence, he is trustee for the migraine trust, and is an educational officer for BASH. The authors report no other conflicts of interest in this work.

#### References

1. Headache Classification Committee of the International Headache Society. The international classification of headache disorders, (beta version). *Cephalalgia*. 2013;**33**(9):629–808.
2. Lauritzen M. Pathophysiology of the migraine aura. The spreading depression theory. *Brain*. 1994;**117** ( Pt 1):199–210. [PubMed: 7908596].
3. Ayata C. Cortical spreading depression triggers migraine attack: pro. *Headache*. 2010;**50**(4):725–30. doi: 10.1111/j.1526-4610.2010.01647.x. [PubMed: 20456160].
4. Schoonman GG, van der Grond J, Kortmann C, van der Geest RJ, Terwindt GM, Ferrari MD. Migraine headache is not associated with cerebral or meningeal vasodilatation—a 3T magnetic resonance angiography study. *Brain*. 2008;**131**(Pt 8):2192–200. doi: 10.1093/brain/awn094. [PubMed: 18502781].
5. Bahra A, May A, Goadsby PJ. Cluster headache: a prospective clinical study with diagnostic implications. *Neurology*. 2002;**58**(3):354–61. [PubMed: 11839832].
6. Halker R, Vargas B, Dodick DW. Cluster headache: diagnosis and treatment. *Semin Neurol*. 2010;**30**(2):175–85. doi: 10.1055/s-0030-1249226. [PubMed: 20352587].
7. Rozen TD. Cluster headache as the result of secondhand cigarette smoke exposure during childhood. *Headache*. 2010;**50**(1):130–2. doi: 10.1111/j.1526-4610.2009.01542.x. [PubMed: 19804394].

8. May A, Goadsby PJ. The trigeminovascular system in humans: pathophysiological implications for primary headache syndromes of the neural influences on the cerebral circulation. *J Cereb Blood Flow Metab.* 1999;**19**(2):115–27. doi: [10.1097/00004647-199902000-00001](https://doi.org/10.1097/00004647-199902000-00001). [PubMed: [10027765](https://pubmed.ncbi.nlm.nih.gov/10027765/)].
9. McNaughton FL. The innervation of the intracranial blood vessels and dural sinuses. *Proc Assoc Res Nerv Mental Dis.* 1938;**18**:178–200.
10. McNaughton FL, Feindel WH. Innervation of intracranial structures: a reappraisal. In: Rose FC, editor. *Physiological Aspects of Clinical Neurology*. Blackwell Scientific Publications; 1977. pp. 279–93.
11. Liu-Chen LY, Han DH, Moskowitz MA. Pia arachnoid contains substance P originating from trigeminal neurons. *Neuroscience.* 1983;**9**(4):803–8. doi: [10.1016/0306-4522\(83\)90268-3](https://doi.org/10.1016/0306-4522(83)90268-3).
12. Liu-Chen LY, Mayberg MR, Moskowitz MA. Immunohistochemical evidence for a substance P-containing trigeminovascular pathway to pial arteries in cats. *Brain Res.* 1983;**268**(1):162–6. doi: [10.1016/0006-8993\(83\)90402-x](https://doi.org/10.1016/0006-8993(83)90402-x).
13. Pietrobon D, Moskowitz MA. Pathophysiology of migraine. *Annu Rev Physiol.* 2013;**75**:365–91. doi: [10.1146/annurev-physiol-030212-183717](https://doi.org/10.1146/annurev-physiol-030212-183717). [PubMed: [23190076](https://pubmed.ncbi.nlm.nih.gov/23190076/)].
14. Dodick D, Silberstein S. Central sensitization theory of migraine: clinical implications. *Headache.* 2006;**46** Suppl 4:S182–91. doi: [10.1111/j.1526-4610.2006.00602.x](https://doi.org/10.1111/j.1526-4610.2006.00602.x). [PubMed: [17078850](https://pubmed.ncbi.nlm.nih.gov/17078850/)].
15. Tajti J, Vecsei L. [The mechanism of peripheral and central sensitization in migraine. A literature review]. *Neuropsychopharmacol Hung.* 2009;**11**(1):15–21. [PubMed: [19731814](https://pubmed.ncbi.nlm.nih.gov/19731814/)].
16. McMahon SB, Lewin GR, Wall PD. Central hyperexcitability triggered by noxious inputs. *Curr Opin Neurobiol.* 1993;**3**(4):602–10. [PubMed: [8219728](https://pubmed.ncbi.nlm.nih.gov/8219728/)].
17. Woolf CJ. Evidence for a central component of post-injury pain hypersensitivity. *Nature.* 1983;**306**(5944):686–8. [PubMed: [6656869](https://pubmed.ncbi.nlm.nih.gov/6656869/)].
18. Woolf CJ. Somatic pain-pathogenesis and prevention. *British J Anaesthesia.* 1995;**75**(2):169–76. doi: [10.1093/bja/75.2.169](https://doi.org/10.1093/bja/75.2.169).
19. Burstein R, Yarnitsky D, Goor-Aryeh I, Ransil BJ, Bajwa ZH. An association between migraine and cutaneous allodynia. *Ann Neurol.* 2000;**47**(5):614–24. [PubMed: [10805332](https://pubmed.ncbi.nlm.nih.gov/10805332/)].
20. Burstein R, Zhang X, Levy D, Aoki KR, Brin MF. Selective inhibition of meningeal nociceptors by botulinum neurotoxin type A: therapeutic implications for migraine and other pains. *Cephalalgia.* 2014;**34**(11):853–69. doi: [10.1177/0333102414527648](https://doi.org/10.1177/0333102414527648). [PubMed: [24694964](https://pubmed.ncbi.nlm.nih.gov/24694964/)].
21. Blau JN, Dexter SL. The site of pain origin during migraine attacks. *Cephalalgia.* 1981;**1**(3):143–7. [PubMed: [7346182](https://pubmed.ncbi.nlm.nih.gov/7346182/)].
22. Rasmussen BK, Jensen R, Olesen J. A population-based analysis of the diagnostic criteria of the International Headache Society. *Cephalalgia.* 1991;**11**(3):129–34. [PubMed: [1889068](https://pubmed.ncbi.nlm.nih.gov/1889068/)].
23. Strassman AM, Raymond SA, Burstein R. Sensitization of meningeal sensory neurons and the origin of headaches. *Nature.* 1996;**384**(6609):560–4. doi: [10.1038/384560a0](https://doi.org/10.1038/384560a0). [PubMed: [8955268](https://pubmed.ncbi.nlm.nih.gov/8955268/)].
24. Burstein R, Yamamura H, Malick A, Strassman AM. Chemical stimulation of the intracranial dura induces enhanced responses to facial stimulation in brain stem trigeminal neurons. *J Neurophysiol.* 1998;**79**(2):964–82. [PubMed: [9463456](https://pubmed.ncbi.nlm.nih.gov/9463456/)].
25. Mathew NT. Pathophysiology of chronic migraine and mode of action of preventive medications. *Headache.* 2011;**51** Suppl 2:84–92. doi: [10.1111/j.1526-4610.2011.01955.x](https://doi.org/10.1111/j.1526-4610.2011.01955.x). [PubMed: [21770930](https://pubmed.ncbi.nlm.nih.gov/21770930/)].
26. Nakai M, Tamaki K, Ogata J, Matsui Y, Maeda M. Parasympathetic cerebrovasodilator center of the facial nerve. *Circ Res.* 1993;**72**(2):470–5. [PubMed: [8093431](https://pubmed.ncbi.nlm.nih.gov/8093431/)].
27. Spencer SE, Sawyer WB, Wada H, Platt KB, Loewy AD. CNS projections to the pterygopalatine parasympathetic preganglionic neurons in the rat: a retrograde transneuronal viral cell body labeling study. *Brain Res.* 1990;**534**(1-2):149–69. [PubMed: [1705849](https://pubmed.ncbi.nlm.nih.gov/1705849/)].
28. Goadsby PJ, Edvinsson L. Human in vivo evidence for trigeminovascular activation in cluster headache. Neuropeptide changes and effects of acute attacks therapies. *Brain.* 1994;**117**( Pt 3):427–34. [PubMed: [7518321](https://pubmed.ncbi.nlm.nih.gov/7518321/)].
29. Cohen AS, Burns B, Goadsby PJ. High-flow oxygen for treatment of cluster headache: a randomized trial. *JAMA.* 2009;**302**(22):2451–7. doi: [10.1001/jama.2009.1855](https://doi.org/10.1001/jama.2009.1855). [PubMed: [19996400](https://pubmed.ncbi.nlm.nih.gov/19996400/)].
30. Akerman S, Holland PR, Summ O, Lasalandra MP, Goadsby PJ. A translational in vivo model of trigeminal autonomic cephalalgias: therapeutic characterization. *Brain.* 2012;**135**(Pt 12):3664–75. doi: [10.1093/brain/aww249](https://doi.org/10.1093/brain/aww249). [PubMed: [23065481](https://pubmed.ncbi.nlm.nih.gov/23065481/)].
31. Di Marzo V, Blumberg PM, Szallasi A. Endovanilloid signaling in pain. *Curr Opin Neurobiol.* 2002;**12**(4):372–9. [PubMed: [12139983](https://pubmed.ncbi.nlm.nih.gov/12139983/)].
32. Foreman JC. Peptides and neurogenic inflammation. *Br Med Bull.* 1987;**43**(2):386–400. [PubMed: [2446695](https://pubmed.ncbi.nlm.nih.gov/2446695/)].
33. Moskowitz MA. The neurobiology of vascular head pain. *Ann Neurol.* 1984;**16**(2):157–68. doi: [10.1002/ana.410160202](https://doi.org/10.1002/ana.410160202). [PubMed: [6206779](https://pubmed.ncbi.nlm.nih.gov/6206779/)].
34. Moskowitz MA. Neurogenic inflammation in the pathophysiology and treatment of migraine. *Neurology.* 1993;**43**(6 Suppl 3):S16–20. [PubMed: [8389008](https://pubmed.ncbi.nlm.nih.gov/8389008/)].
35. Messlinger K, Hanesch U, Baumgartel M, Trost B, Schmidt RF. Innervation of the dura mater encephali of cat and rat: ultrastructure and calcitonin gene-related peptide-like and substance P-like immunoreactivity. *Anat Embryol (Berl).* 1993;**188**(3):219–37. [PubMed: [7504417](https://pubmed.ncbi.nlm.nih.gov/7504417/)].
36. von Düring M, Bauersachs M, Bohmer B, Veh RW, Andres KH. Neuropeptide Y- and substance P-like immunoreactive nerve fibers in the rat dura mater encephali. *Anat Embryol (Berl).* 1990;**182**(4):363–73. [PubMed: [1701289](https://pubmed.ncbi.nlm.nih.gov/1701289/)].
37. Mayberg MR, Zervas NT, Moskowitz MA. Trigeminal projections to supratentorial pial and dural blood vessels in cats demonstrated by horseradish peroxidase histochemistry. *J Comp Neurol.* 1984;**223**(1):46–56. doi: [10.1002/cne.902230105](https://doi.org/10.1002/cne.902230105). [PubMed: [6200513](https://pubmed.ncbi.nlm.nih.gov/6200513/)].
38. Edwards RM, Stack EJ, Trizna W. Calcitonin gene-related peptide stimulates adenylate cyclase and relaxes intracerebral arterioles. *J Pharmacol Exp Ther.* 1991;**257**(3):1020–4. [PubMed: [1710661](https://pubmed.ncbi.nlm.nih.gov/1710661/)].
39. Ashina M, Bendtsen L, Jensen R, Schifter S, Olesen J. Evidence for increased plasma levels of calcitonin gene-related peptide in migraine outside of attacks. *Pain.* 2000;**86**(1-2):133–8. [PubMed: [10779670](https://pubmed.ncbi.nlm.nih.gov/10779670/)].
40. Goadsby PJ, Edvinsson L. The trigeminovascular system and migraine: studies characterizing cerebrovascular and neuropeptide changes seen in humans and cats. *Ann Neurol.* 1993;**33**(1):48–56. doi: [10.1002/ana.410330109](https://doi.org/10.1002/ana.410330109). [PubMed: [8388188](https://pubmed.ncbi.nlm.nih.gov/8388188/)].
41. Goadsby PJ, Edvinsson L, Ekman R. Vasoactive peptide release in the extracerebral circulation of humans during migraine headache. *Ann Neurol.* 1990;**28**(2):183–7. doi: [10.1002/ana.410280213](https://doi.org/10.1002/ana.410280213). [PubMed: [1699472](https://pubmed.ncbi.nlm.nih.gov/1699472/)].
42. Goadsby PJ, Edvinsson L. Evidence of trigeminovascular activation in man during acute cluster headache. *Cephalalgia.* 1993;**13**(suppl 13):30.
43. Sicuteri F, Fanciullacci M, Geppetti P, Renzi D, Caleri D, Spillantini MG. Substance P mechanism in cluster headache: evaluation in plasma and cerebrospinal fluid. *Cephalalgia.* 1985;**5**(3):143–9. [PubMed: [2412704](https://pubmed.ncbi.nlm.nih.gov/2412704/)].
44. Goadsby PJ, Edvinsson L. Neuropeptides in headache. *Eur J Neurol.* 1998;**5**:329–41.
45. Dodick DW, Goadsby PJ, Spierings EL, Scherer JC, Sweeney SP, Grayzel DS. Safety and efficacy of LY2951742, a monoclonal antibody to calcitonin gene-related peptide, for the prevention of migraine: a phase 2, randomised, double-blind, placebo-controlled study. *Lancet Neurol.* 2014;**13**(9):885–92. doi: [10.1016/S1474-4422\(14\)70128-0](https://doi.org/10.1016/S1474-4422(14)70128-0). [PubMed: [25127173](https://pubmed.ncbi.nlm.nih.gov/25127173/)].
46. Ho TW, Edvinsson L, Goadsby PJ. CGRP and its receptors provide new insights into migraine pathophysiology. *Nat Rev Neurol.* 2010;**6**(10):573–82. doi: [10.1038/nrneuro.2010.127](https://doi.org/10.1038/nrneuro.2010.127). [PubMed: [20820195](https://pubmed.ncbi.nlm.nih.gov/20820195/)].
47. Olesen J, Diener HC, Husstedt IW, Goadsby PJ, Hall D, Meier U, et al. Calcitonin gene-related peptide receptor antagonist BIBN 4096 BS for the acute treatment of migraine. *N Engl J Med.* 2004;**350**(11):1104–10. doi: [10.1056/NEJMoa030505](https://doi.org/10.1056/NEJMoa030505). [PubMed: [15014183](https://pubmed.ncbi.nlm.nih.gov/15014183/)].

48. Goadsby PJ, Akerman S, Storer RJ. Evidence for postjunctional serotonin (5-HT<sub>1</sub>) receptors in the trigeminocervical complex. *Ann Neurol*. 2001;**50**(6):804-7. [PubMed: [11761480](#)].
49. Korytko PJ, Boje KM. Pharmacological characterization of nitric oxide production in a rat model of meningitis. *Neuropharmacology*. 1996;**35**(2):231-7. [PubMed: [8734493](#)].
50. Buzzi MG, Moskowitz MA. The pathophysiology of migraine: year 2005. *J Headache Pain*. 2005;**6**(3):105-11. doi: [10.1007/s10194-005-0165-2](#). [PubMed: [16355290](#)].
51. Buchanan JE, Phillis JW. The role of nitric oxide in the regulation of cerebral blood flow. *Brain Res*. 1993;**610**(2):248-55. [PubMed: [8319087](#)].
52. Strecker T, Dux M, Messlinger K. Nitric oxide releases calcitonin-gene-related peptide from rat dura mater encephali promoting increases in meningeal blood flow. *J Vasc Res*. 2002;**39**(6):489-96. [PubMed: [12566974](#)].
53. Olesen J, Thomsen LL, Lassen LH, Olesen J. The nitric oxide hypothesis of migraine and other vascular headaches. *Cephalalgia*. 1995;**15**(2):94-100. [PubMed: [7641257](#)].
54. Hardebo JE. The involvement of trigeminal substance P neurons in cluster headache. An hypothesis. *Headache*. 1984;**24**(6):294-304. [PubMed: [6083992](#)].
55. Olesen J, Friberg L. Xenon-133 SPECT studies in migraine without aura. In: Olesen J, editor. *Migraine and other headaches: the vascular mechanisms*. London: Raven Press; 1991. p. 237-43.
56. Henry PY, Vernhiet J, Orgogozo JM, Caille JM. Cerebral blood flow in migraine and cluster headache. Compartmental analysis and reactivity to anaesthetic depression. *Res Clin Stud Headache*. 1978;**6**:81-8. [PubMed: [725260](#)].
57. Weiller C, May A, Limmroth V, Juptner M, Kaube H, Schayck RV, et al. Brain stem activation in spontaneous human migraine attacks. *Nat Med*. 1995;**1**(7):658-60. [PubMed: [7585147](#)].
58. Afridi SK, Giffin NJ, Kaube H, Friston KJ, Ward NS, Frackowiak RS, et al. A positron emission tomographic study in spontaneous migraine. *Arch Neurol*. 2005;**62**(8):1270-5. doi: [10.1001/archneur.62.8.1270](#). [PubMed: [16087768](#)].
59. Raskin NH, Hosobuchi Y, Lamb S. Headache may arise from perturbation of brain. *Headache*. 1987;**27**(8):416-20. [PubMed: [3667258](#)].
60. Kaur A, Selwa L, Fromes G, Ross DA. Persistent headache after supratentorial craniotomy. *Neurosurgery*. 2000;**47**(3):633-6. [PubMed: [10981750](#)].
61. Moulton EA, Burstein R, Tully S, Hargreaves R, Becerra L, Borsook D. Interictal dysfunction of a brainstem descending modulatory center in migraine patients. *PLoS One*. 2008;**3**(11):e3799. doi: [10.1371/journal.pone.0003799](#). [PubMed: [19030105](#)].
62. Dunckley P, Wise RG, Fairhurst M, Hobden P, Aziz Q, Chang L, et al. A comparison of visceral and somatic pain processing in the human brainstem using functional magnetic resonance imaging. *J Neurosci*. 2005;**25**(32):7333-41. doi: [10.1523/JNEUROSCI.1100-05.2005](#). [PubMed: [16093383](#)].
63. Xiang B, Biji S, Liu JX, Chu WC, Yeung DK, Yeung CK. Functional brainstem changes in response to bladder function alteration elicited by surgical reduction in bladder capacity: a functional magnetic resonance imaging study. *J Urol*. 2010;**184**(5):2186-91. doi: [10.1016/j.juro.2010.06.095](#). [PubMed: [20850835](#)].
64. Suzuki H, Watanabe S, Hamaguchi T, Mine H, Terui T, Kanazawa M, et al. Brain activation associated with changes in heart rate, heart rate variability, and plasma catecholamines during rectal distention. *Psychosom Med*. 2009;**71**(6):619-26. doi: [10.1097/PSY.0b013e31819b69ca](#). [PubMed: [19561165](#)].
65. Barman SM, Gebber GL, Kitchens H. Rostral dorsolateral pontine neurons with sympathetic nerve-related activity. *Am J Physiol*. 1999;**276**(2 Pt 2):H401-12. [PubMed: [9950839](#)].
66. Cao Y, Aurora SK, Nagesh V, Patel SC, Welch KM. Functional MRI-BOLD of brainstem structures during visually triggered migraine. *Neurology*. 2002;**59**(1):72-8. [PubMed: [12105310](#)].
67. Tessitore A, Russo A, Esposito F, Giordano A, Tagliatela G, De Micco R, et al. Interictal cortical reorganization in episodic migraine without aura: an event-related fMRI study during parametric trigeminal nociceptive stimulation. *Neurol Sci*. 2011;**32 Suppl 1**:S165-7. doi: [10.1007/s10072-011-0537-0](#). [PubMed: [21533737](#)].
68. Maleki N, Becerra L, Nutile L, Pendse G, Brawn J, Bigal M, et al. Migraine attacks the Basal Ganglia. *Mol Pain*. 2011;**7**:71. doi: [10.1186/1744-8069-7-71](#). [PubMed: [21936901](#)].
69. Baliki MN, Geha PY, Apkarian AV, Chialvo DR. Beyond feeling: chronic pain hurts the brain, disrupting the default-mode network dynamics. *J Neurosci*. 2008;**28**(6):1398-403. doi: [10.1523/JNEUROSCI.4123-07.2008](#). [PubMed: [18256259](#)].
70. Kim JH, Suh SI, Seol HY, Oh K, Seo WK, Yu SW, et al. Regional grey matter changes in patients with migraine: a voxel-based morphometry study. *Cephalalgia*. 2008;**28**(6):598-604. doi: [10.1111/j.1468-2982.2008.01550.x](#). [PubMed: [18422725](#)].
71. DaSilva AF, Granziera C, Snyder J, Hadjikhani N. Thickening in the somatosensory cortex of patients with migraine. *Neurology*. 2007;**69**(21):1990-5. doi: [10.1212/01.wnl.0000291618.32247.2d](#). [PubMed: [18025393](#)].
72. Burstein R, Jakubowski M, Garcia-Nicas E, Kainz V, Bajwa Z, Hargreaves R, et al. Thalamic sensitization transforms localized pain into widespread allodynia. *Ann Neurol*. 2010;**68**(1):81-91. doi: [10.1002/ana.21994](#). [PubMed: [20582997](#)].
73. Fumal A, Laureys S, Di Clemente L, Boly M, Bohotin V, Vandenheede M, et al. Orbitofrontal cortex involvement in chronic analgesic-overuse headache evolving from episodic migraine. *Brain*. 2006;**129**(Pt 2):543-50. doi: [10.1093/brain/awh691](#). [PubMed: [16330505](#)].
74. Nosedà R, Burstein R. Migraine pathophysiology: anatomy of the trigeminovascular pathway and associated neurological symptoms, CSD, sensitization and modulation of pain. *Pain*. 2013;**154 Suppl 1** doi: [10.1016/j.pain.2013.07.021](#). [PubMed: [24347803](#)].
75. Angus-Leppan H, Olausson B, Boers P, Lambert GA. Convergence of afferents from superior sagittal sinus and tooth pulp on cells in the thalamus of the cat. *Cephalalgia*. 1995;**15**(3):191-9. [PubMed: [753808](#)].
76. Nosedà R, Jakubowski M, Kainz V, Borsook D, Burstein R. Cortical projections of functionally identified thalamic trigeminovascular neurons: implications for migraine headache and its associated symptoms. *J Neurosci*. 2011;**31**(40):14204-17. doi: [10.1523/JNEUROSCI.3285-11.2011](#). [PubMed: [21976505](#)].
77. Kudrow L. Plasma testosterone and LH levels in cluster headache. *Headache*. 1977;**17**:91-2.
78. Leone M, Patrino G, Vescovi A, Bussone G. Neuroendocrine dysfunction in cluster headache. *Cephalalgia*. 1990;**10**(5):235-9. [PubMed: [2272093](#)].
79. Chazot G, Claustrat B, Brun J, Jordan D, Sassolas G, Schott B. A chronobiological study of melatonin, cortisol growth hormone and prolactin secretion in cluster headache. *Cephalalgia*. 1984;**4**(4):213-20. [PubMed: [6518501](#)].
80. May A, Bahra A, Buchel C, Frackowiak RS, Goadsby PJ. Hypothalamic activation in cluster headache attacks. *Lancet*. 1998;**352**(9124):275-8. doi: [10.1016/S0140-6736\(98\)02470-2](#). [PubMed: [9690407](#)].
81. May A, Bahra A, Buchel C, Frackowiak RS, Goadsby PJ. PET and MRA findings in cluster headache and MRA in experimental pain. *Neurology*. 2000;**55**(9):1328-35. [PubMed: [11087776](#)].
82. Sprenger T, Willoch F, Miederer M, Schindler F, Valet M, Berthele A, et al. Opioidergic changes in the pineal gland and hypothalamus in cluster headache: a ligand PET study. *Neurology*. 2006;**66**(7):1108-10. doi: [10.1212/01.wnl.0000204225.15947.f8](#). [PubMed: [16606930](#)].
83. Benjamin L, Levy MJ, Lasalandra MP, Knight YE, Akerman S, Classey JD, et al. Hypothalamic activation after stimulation of the superior sagittal sinus in the cat: a Fos study. *Neurobiol Dis*. 2004;**16**(3):500-5. doi: [10.1016/j.nbd.2004.03.015](#). [PubMed: [15262261](#)].
84. Hosoya Y, Sugiura Y, Ito R, Kohno K. Descending projections from the hypothalamic paraventricular nucleus to the A5 area, including the superior salivatory nucleus, in the rat. *Exp Brain Res*. 1990;**82**(3):513-8.



- [PubMed: [2292271](#)].
85. Di Piero V, Fiacco F, Tombari D, Pantano P. Tonic pain: a SPET study in normal subjects and cluster headache patients. *Pain*. 1997;**70**(2-3):185-91. [PubMed: [9150292](#)].
86. Hsieh JC, Hannerz J, Ingvar M. Right-lateralised central processing for pain of nitroglycerin-induced cluster headache. *Pain*. 1996;**67**(1):59-68. [PubMed: [8895232](#)].
87. Sprenger T, Ruether KV, Boecker H, Valet M, Berthele A, Pfaffenrath V, et al. Altered metabolism in frontal brain circuits in cluster headache. *Cephalalgia*. 2007;**27**(9):1033-42. doi: [10.1111/j.1468-2982.2007.01386.x](#). [PubMed: [17666083](#)].

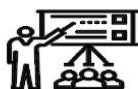# SID



سرویس های ویژه



سرویس ترجمه تخصصی



کارگاه های آموزشی



بلاگ مرکز اطلاعات علمی

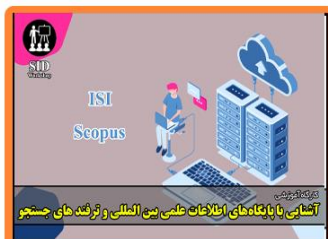

عضویت در خبرنامه

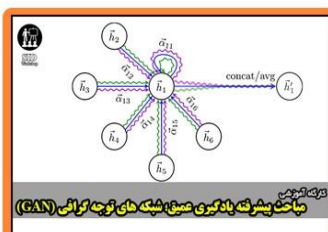


فیلم های آموزشی

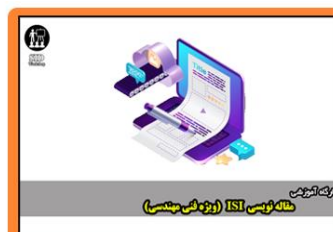## کارگاه های آموزشی مرکز اطلاعات علمی جهاد دانشگاهی



کارگاه آنلاین آشنایی با پایگاه های اطلاعات علمی بین المللی و ترند های جستجو



مباحث پیشرفته یادگیری عمیق؛ شبکه های توجه گرافی (Graph Attention Networks)



کارگاه آنلاین مقاله نویسی IEEE و ISI ویژه فنی و مهندسی