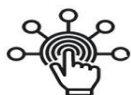

SID



سرویس های ویژه



سرویس ترجمه تخصصی



کارگاه های آموزشی



بلاگ مرکز اطلاعات علمی

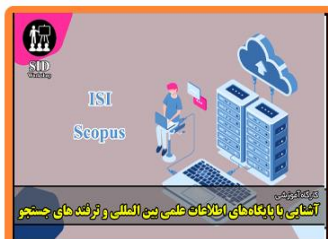

عضویت در خبرنامه

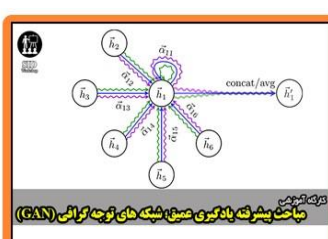


فیلم های آموزشی

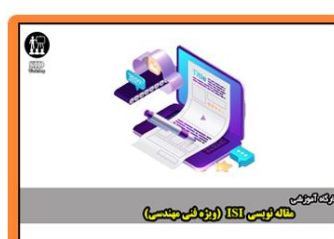کارگاه های آموزشی مرکز اطلاعات علمی جهاد دانشگاهی



کارگاه آنلاین آشنایی با پایگاه های اطلاعات علمی بین المللی و ترند های جستجو



مباحث پیشرفته یادگیری عمیق؛ شبکه های توجه گرافی (Graph Attention Networks)



کارگاه آنلاین مقاله نویسی IEEE و ISI ویژه فنی و مهندسی

Co-Existence of Two Dens Invaginations with One Dens Evagination in a Maxillary Lateral Incisor: A Case Report

Seyed Amir Satvati¹, Mohammad Shooriabi², Rouhollah Sharifi³, Masoud Parirokh⁴, Marzieh Sahebhasagh⁵, Hadi Assadian⁶

¹Assistant Professor, Department of Endodontics, School of Dentistry, North Khorasan University of Medical Sciences, Bojnourd, Iran

²Assistant Professor, Department of Oral Medicine, School of Dentistry Jundishapur University of Medical Sciences, Ahvaz, Iran

³Assistant Professor, Department of Endodontics, School of Dentistry, Kermanshah University of Medical Sciences, Kermanshah, Iran

⁴Professor, Department of Endodontics, School of Dentistry, Kerman University of Medical Sciences, Kerman, Iran

⁵Assistant Professor, Department of Pediatric Dentistry, School of Dentistry, North Khorasan University of Medical Sciences Bojnourd, Iran

⁶Assistant Professor, Department of Endodontics, School of Dentistry, Shahed University

Abstract

A case with two simultaneous dens invaginations (DIs) and one dens evagination (DE) in a permanent maxillary lateral incisor is reported for the first time in a 21-year-old girl.

DE known as talon cusp of the anterior teeth is a rare entity and its co-existence with DI has been reported scarcely in the literature. Simultaneous occurrence of two DIs with one DE has not been reported elsewhere. Undoubtedly, familiarity with the internal anatomy of such a rare condition can help prevent pulpal disease while performing restorative procedures.

Key Words: Dente; Incisor; Tooth Abnormalities

✉Corresponding author:

H. Asadian, Department of Endodontics, School of Dentistry, Shahed University

harrydds@yahoo.com

Received: 16 February 2014

Accepted: 10 April 2014

Journal of Dentistry, Tehran University of Medical Sciences, Tehran, Iran (2014; Vol. 11, No. 4)

INTRODUCTION

Dens invaginatus (DI) is referred to as a developmental anomaly that results from an infolding within the crown prior to calcification [1]. According to the 0.04 to 10% frequency of dens invagination in the currently available literature, this condition is regarded as a rarity [2]. Several hypotheses have been proposed concerning the etiology of invaginated teeth, including constriction of the dental arch on the enamel organ, decreased or increased growth rate of the internal enamel epithelium, distortion of the enamel organ during dental development or insufficient nutrition of a portion of a single tooth germ [3]. The epithelium forms a lining of enamel in a channel inside the dentin of the affected tooth. Following calcifica-

tion of the enamel, it radiographically appears as parallel radiopaque lines within the less radiopaque dentin [4]. The enamel lining is sometimes imperfect and develops caries, which can lead to dentin or pulpal exposure and eventual pulpal pathosis [5]. Maxillary lateral incisors are most commonly affected and bilateral occurrence is not uncommon, involving 43% of all cases [6, 7].

Dens evagination (DE) (also known as talon cusp) is a relatively infrequent developmental abnormality characterized by the existence of an accessory cusp-like structure projecting from the cingulum area or cemento-enamel junction (CEJ) of the maxillary or mandibular anterior teeth both in the primary and permanent dentition [8-10].

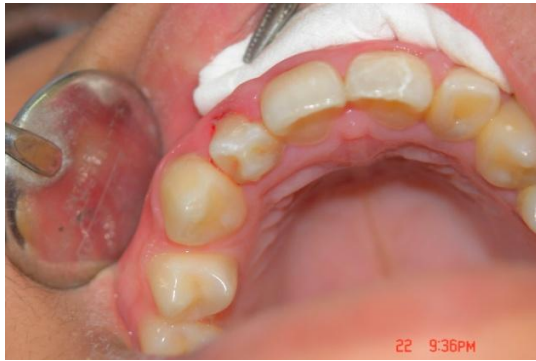

Fig 1. Intra-oral photograph of the maxillary arch shows DE on the maxillary right lateral incisor.

This evagination is composed of enamel, dentin and varying amounts of pulpal tissue [11]. DE can occur in both sexes and the most commonly affected teeth are the permanent maxillary incisors, particularly the lateral. It has also been reported, although less commonly, in the mandibular teeth [12]. The most commonly affected posterior teeth are the premolars [8-10]. Although both DI and DE have been reported frequently in the literature, simultaneous occurrence of these two entities within a single tooth has been noticed only limitedly [13-15]. To the best of our knowledge, co-existence of a DE with two DIs within a single tooth is considered a rarity and has not been encountered in the literature.

CASE REPORT

A 21-year-old girl came to the School of Dentistry, Kerman University of Medical Sciences for her regular dental follow-up visits and was advised to receive a full-mouth periapical radiographic evaluation. The patient did not have any contributory medical history. Extra-oral examination did not indicate any significant finding. Intra-oral examination revealed several carious lesions, restorations and a mild periodontal disease. Presence of a DE was noticeable in the patient's permanent right maxillary lateral incisor (Fig 1). There was no associated swelling or sinus tract. The patient's maxillary left lateral incisor did not have any problem based on clinical and radiographic

evaluations. Periapical radiographic evaluation showed co-existence of two DIs with the aforementioned DE (Fig 2). The periapical region had a normal radiographic appearance. The tooth responded as vital on electrical and thermal pulp sensitivity tests and no periapical lesion was detected radiographically. Pits mesial and distal to the DE were conservatively removed and restored by bonded restorations (3M, ESPE, St Paul, MN). The tooth did not have any occlusal interference. The patient did not express any esthetic or functional problem. Regular clinical and radiographic recall visits were contemplated for the patient.

DISCUSSION

Dens invaginatus is a relatively common dental anomaly. It has been stated that DI affects maxillary lateral incisors in 0.25% to 5.1% of the population [16, 17]. However, double DI in a single tooth has infrequently been reported [14, 18, 19]. DI is clinically important because of the resultant aberration in anatomy. It is possible for dental caries to easily reach the pulp chamber in DI cases. The patient is usually detected incidentally by intraoral periapical radiographs. The reported patient did not have any complaint about the considered tooth and the problem was accidentally diagnosed on full-mouth radiographic examination.

According to Oehlers' description of invagination [20], the case was categorized as "type I" because the invaginated cavities did not extend beyond the cemento-enamel junction. It has been stated that the morphology of the tooth with DI may undergo changes such as increased labio-lingual or mesio-distal dimension, incisal notching associated with a labial groove, a peg-shaped or conical morphology or the presence of an exaggerated palatal cingulum or 'talon cusp' [21, 22]. Simultaneous occurrence of two DIs with one DE in a single tooth has not been previously reported but separate conditions in different teeth have been reported exclusively in the literature.

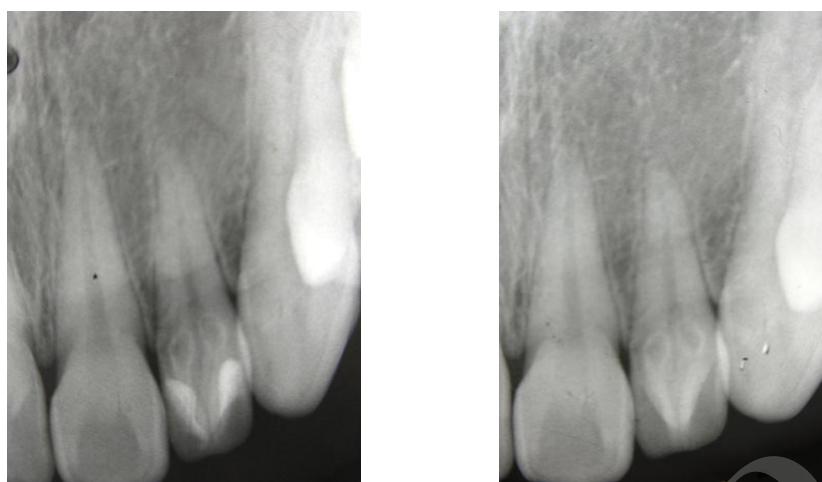


Fig 2. Periapical radiograph of the maxillary right lateral incisor. The white arrow indicates the DE and the black arrows point to the DIs. Note that the two DIs are distinct from the pulp chamber.

In other words we are reporting a case with three simultaneous malformations in a single tooth. This actually makes our case report unique. Presence of canals and cracks that reach the pulpal cavity are numerous in DE. They may result in contamination of the pulp and progressive loss of pulp vitality. Therefore, such teeth should be regularly followed for development of pulpal pathosis.

DE is a rare dental anomaly occurring commonly on the lingual surface of primary or permanent teeth [23, 24]. Usually, grooves or fissures can be found at the junction of the evagination with the lingual tooth surface, which often allows plaque retention, thereby causing caries and endodontic and periodontal inflammation [25]. The etiology of this condition is multifactorial with genetic and environmental factors playing significant roles [26]. It has also been reported that this anomaly is related to Rubinstein-Taybi, Mohr, and Sturge-Weber syndromes and to anomalies including odontome, dens invaginatus, double tooth, supernumerary tooth, peg-shaped lateral incisors, agenesis of canines, mesiodens, megadont, and shovel-shaped incisors [8, 12, 24, 25, 27, 28].

Although there is no strong correlation between the aforementioned syndromes and talon cusp, in a study by Hennekam and Van Doorne [29] on 45 patients with Rubinstein-Taybi syndrome, 92% of these patients had talon cusps. The authors concluded that there was a positive correlation between these two entities.

Other signs of this syndrome such as mental and developmental retardation, thin upper lip, retrognathia, micrognathia and cleft palate were not evident in our patient, therefore the presence of this syndrome was ruled out.

Talon cusp has a prevalence of 0.06-7.7 percent with a predominance in the male gender [12,23, 30, 31]. Although many authors have reported DE in the primary dentition [8, 25], it is seen more frequently in permanent dentition. Talon cusp can cause problems for the patient including poor esthetics, caries, occlusal trauma, displacement of the involved tooth, irritation of the tongue during speech and mastication, periodontal problems, accidental cuspal fracture and attrition causing pulpal exposure or periapical pathosis [11, 12, 32-34]. The radiographic appearance of talon cusp resembles that of a supernumerary tooth

or compound odontoma, consequently increasing the likelihood of misdiagnosis [11, 12, 32]. DE can either be treated conservatively or radically, depending on the shape or size of the affected tooth [11, 28, 33, 35-37].

Treatment remedies may consist of gradual periodic cuspal reduction with fluoride as a desensitizing agent, one-visit reduction with or without endodontic therapy, application of sealants for developmental grooves and placement of esthetic restorations. In this case, simultaneous occurrence of two DIs and one DE was encountered in a permanent maxillary lateral incisor. This patient represented positive responses to vitality tests without any radiographic signs of apical periodontitis. In such cases, it is recommended that the susceptible parts should be sealed prophylactically using restorative materials in order to prevent formation of any communication pathways between the oral environment and pulpal space.

This was carried out in this patient using a composite resin restoration. It has to be taken into consideration that Ohlers' classification is based on the presence of a single dens invagination; whereas, this patient represented two invaginations simultaneously. According to similar reports in the literature [18, 38], this classification should be modified based on the presence of multiple defects.

REFERENCES

- 1- Contemporary terminology for endodontists. In: American Association of Endodontics Glossary. 6th ed. Chicago, IL: American Association of Endodontics; 1998.
- 2- Hovland EJ, Block RM. Nonrecognition and subsequent endodontic treatment of dens invaginatus. *J Endod.* 1977 Sep;3(9):360-2.
- 3- de Sousa SM, Bramante CM. Dens invaginatus: treatment choices. *Endod Dent Traumatol.* 1998 Aug;14(4):152-8.
- 4- Gound TG, Maixner D. Nonsurgical management of a dilacerated maxillary lateral incisor with type III dens invaginatus: a case report. *J Endod.* 2004 Jun;30(6):448-51.
- 5- Kramer IR. The pathology of pulp death in non-carious maxillary incisors with minor palatal invaginations. *Proc R Soc Med.* 1953 Jul;46(7):503-5.
- 6- Marwah N, Goenka P, Nigam AG. Combined Surgical and Nonsurgical Endodontic Therapy in the Treatment of Dens Invaginatus Type 3: A Case Report. *International Journal of Clinical Pediatric Dentistry* 2009;2(3).
- 7- Tarjan I, Rozsa N. Endodontic treatment of immature tooth with dens invaginatus: a case report. *International J Paediatr Dent.* 2001 Mar;9(1):53-6.
- 8- Hattab FN, Yassin OM, Al-Nimri KS. Talon cusp--clinical significance and management: case reports. *Quintessence Int.* 1995 Feb;26(2):115-20.
- 9- Karaca, Toller M. Multiple bilateral dens in dente involving all the premolars. Case report. *Aust Dent J.* 2009 Dec;37(6):449-52.
- 10- Tavano SM, de Sousa SM, Bramante CM. Dens invaginatus in first mandibular premolar. *Endod Dent Traumatol.* 1994 Feb;10(1):27-9.
- 11- Dayal PK, Mani NJ, Verma PK. Talon cusp: a review and case report. *J Dent.* 1980 Mar;8(1):85-7.
- 12- Davis PJ, Brook AH. The presentation of talon cusp: diagnosis, clinical features, associations and possible aetiology. *Br Dent J.* 1986 Feb;160(3):84-8.
- 13- Anthonappa RP, Yiu CK, King NM. A Novel Combination of dens evaginatus and dens invaginatus in a Single Tooth--Review of the Literature and a Case Report. *J Clin Pediatr Dent.* 2008 Spring;32(3):239-42.
- 14- Mupparapu M, Singer SR, Goodchild JH. Dens evaginatus and dens invaginatus in a maxillary lateral incisor: report of a rare occurrence and review of literature. *Aust Dent J.* 2004 Dec;49(4):201-3.
- 15- Marya CM, Parashar V, Grover S, Dahiya V. A rare case of dens evaginatus and dens invaginatus in the same tooth, with a review of

- treatment options. *Gen Dent.* 2011 Jul-Aug;59(4):e182-4.
- 16- Pindborg J. *Pathology of the Dental Hard Tissues.* Philadelphia: WB Saunders; 1970.
- 17- Cakici F, Celikoglu M, Arslan H, Topcuoglu HS, Erdogan AS. Assessment of the prevalence and characteristics of dens invaginatus in a sample of Turkish Anatolian population. *Med Oral Patol Oral Cir Bucal.* 2010 Nov;15(6):e855-8.
- 18- Zengin AZ, Sumer AP, Celenk P. Double dens invaginatus: report of three cases. *Eur J Dent.* 2009 Jan;3(1):67.
- 19- Kiswani K. Concomitant dens evaginatus and dens invaginatus in a maxillary lateral incisor: A case report. *Oral Maxillofac Pathol J.* 2013;4(2).
- 20- Oehlers FA. Dens invaginatus (dilated composite odontome). I. Variations of the invagination process and associated anterior crown forms. *Oral Surg Oral Med Oral Pathol.* 1957 Nov;10(11):1204-18.
- 21- Bishop K, Alani A. Dens invaginatus. Part 2: clinical, radiographic features and management options. *Int Endod J.* 2008 Dec;41(12):1137-54.
- 22- Goncalves A, Goncalves M, Oliveira DP, Goncalves N. Dens invaginatus type III: report of a case and 10-year radiographic follow-up. *Int Endod J.* 2002 Oct;35(10):873-9.
- 23- Dankner E, Harari D, Rotstein I. Dens evaginatus of anterior teeth: Literature review and radiographic survey of 15,000 teeth. *Oral Surg Oral Med Oral Pathol Oral Radiol Endod.* 1996 Apr;81(4):472-5.
- 24- Noikura T, Ooya K, Kikuchi M. Double dens in dente with a central cusp and multituberculism in bilateral maxillary supernumerary central incisors: report of a case. *Oral Surg Oral Med Oral Pathol Oral Radiol Endod.* 1996 Oct;82(4):466-9.
- 25- Mader CL. Talon cusp. *J Am Dent Assoc* 1981 Aug;103(2):244-6.
- 26- Garn SM, Lewis AB, Kerewsky RS. Genetic, nutritional, and maturational correlates of dental development. *J Dent Res.* 1965 Jan-Feb;44 Supp:228-42.
- 27- Natkin E, Pitts DL, Worthington P. A case of talon cusp associated with other odontogenic abnormalities. *J Endod.* 1983 Nov;9(11):491-5.
- 28- Mellor JK, Ripa LW. Talon cusp: a clinically significant anomaly. *Oral Surg Oral Med Oral Pathol.* 1970 Feb;29(2):225-8.
- 29- Hennekam R, Van Doorne JM. Oral aspects of Rubinstein-Taybi syndrome. *Am J Med Genet Suppl.* 1990;6:42-7.
- 30- Sedano HO, Carreon Freyre I, Garza de la Garza ML, Gomar Franco CM, Grimaldo Hernandez C, Hernandez Montoya ME, et al. Clinical orodental abnormalities in Mexican children. *Oral Surg Oral Med Oral Pathol.* 1989 Sep;68(3):300-11.
- 31- Chawla HS, Tewari A, Gopalakrishnan NS. Talon cusp--a prevalence study. *J Indian Soc Pedod Prev Dent.* 1983 Mar;14(1):28-34.
- 32- Henderson HZ. Talon cusp: a primary or a permanent incisor anomaly. *J Indian Dent Assoc.* 1977 Nov-Dec;56(6):45-6.
- 33- Richardson DS, Knudson KG. Talon cusp: a preventive approach to treatment. *J Am Dent Assoc.* 1985 Jan;110(1):60-2.
- 34- Salama FS, Hanes CM, Hanes PJ, Ready MA. Talon cusp: a review and two case reports on supernumerary primary and permanent teeth. *ASDC J Dent Child.* 1990 Mar-Apr;57(2):147-9.
- 35- Tse CM, Walker RT. Endodontic treatment of a canine with a talon cusp. *Dent Traumatol.* 1988 Oct;4(5):235-7.
- 36- Lomcali G, Hazar S, Altinbulak H. Talon cusp: report of five cases. *Quintessence Int.* 1994 Jun;25(6):431-3.
- 37- Abbott PV. Labial and palatal talon cusps on the same tooth: a case report. *Oral Surg Oral Med Oral Pathol Oral Radiol Endod.* 1998 Jun;85(6):726-30.
- 38- Conklin WW. Double bilateral dens invaginatus in the maxillary incisor region. *Oral Surg Oral Med Oral Pathol.* 1975 Jun;39(6):949-52.

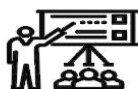SID



سرویس های ویژه



سرویس ترجمه تخصصی



کارگاه های آموزشی



بلاگ مرکز اطلاعات علمی



عضویت در خبرنامه

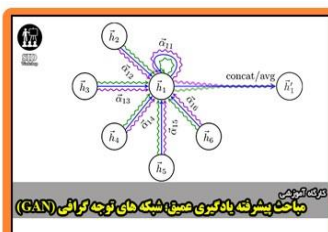


فیلم های آموزشی

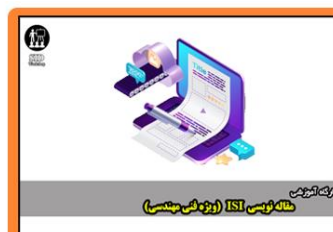کارگاه های آموزشی مرکز اطلاعات علمی جهاد دانشگاهی



کارگاه آنلاین آشنایی با پایگاه های اطلاعات علمی بین المللی و ترند های جستجو



مباحث پیشرفته یادگیری عمیق؛ شبکه های توجه گرافی (Graph Attention Networks)



کارگاه آنلاین مقاله نویسی IEEE و ISI ویژه فنی و مهندسی