

# SID



سرویس های ویژه



سرویس ترجمه تخصصی



کارگاه های آموزشی



بلاگ مرکز اطلاعات علمی



عضویت در خبرنامه



فیلم های آموزشی

## کارگاه های آموزشی مرکز اطلاعات علمی جهاد دانشگاهی



PROPOSAL

پروپوزال

مركز آموزش  
پروپوزال نویسی و پایان نامه نویسی

کارگاه آنلاین  
پروپوزال نویسی و پایان نامه نویسی



مركز آموزش  
روش تحقیق و مقاله نویسی علوم انسانی

کارگاه آنلاین  
روش تحقیق و مقاله نویسی علوم انسانی



ISI  
Scopus

مركز آموزش  
آشنایی با پایگاه های اطلاعات علمی بین المللی و ترکیه های جستجو

کارگاه آنلاین آشنایی با پایگاه های اطلاعات علمی بین المللی و ترکیه های جستجو

# Can Ultrasound Findings be a Good Predictor of Sperm Parameters in Patients With Varicocele? A Cross-Sectional Study

Ali Mahdavi,<sup>1,\*</sup> Reza Heidari,<sup>2</sup> Mehrdad Khezri,<sup>1</sup> Abolfazl Shiravi,<sup>1</sup> Reyhaneh Pirjani,<sup>2</sup> and Reyhaneh Saheb Kashaf<sup>1</sup>

<sup>1</sup>Department of Radiology, Tehran University of Medical Sciences, Tehran, IR Iran

<sup>2</sup>School of Medicine, Tehran University of Medical Sciences, Tehran, IR Iran

\*Corresponding author: Ali Mahdavi, Department of Radiology, Tehran University of Medical Sciences, Tehran, IR Iran. E-mail: mahdavi0ali@yahoo.com

Received 2016 March 08; Revised 2016 June 09; Accepted 2016 June 18.

## Abstract

**Background:** Varicocele, one of the most common causes of sperm abnormalities in men, is the dilation of the testicular vein (the pampiniform venous plexus) by more than 2 mm. Ultrasonography is the primary imaging procedure for varicocele diagnosis. The venous diameter is evaluated using B-mode sonography, and venous reflux is assessed using color Doppler sonography.

**Objectives:** In this study, we investigated the association of ultrasound findings with sperm parameters in patients with varicocele.

**Methods:** Ninety-nine patients with clinically diagnosed varicocele were included in this study, which was performed at a university imaging center. Patients were evaluated for pampiniform venous plexus diameter, venous reflux, and testicular size on both sides. Semen analysis was performed for all patients. The ultrasonography parameters and semen analysis data were compared to assess the correlations between the results.

**Results:** The semen analysis parameters, including semen volume and sperm morphology, count, and motility, significant correlations with the diameter of the varicocele vein but were not correlated with testes size. In addition, the patients with reflux of longer than 1 s and those with reflux of less than 1 s had significant differences in sperm parameters and varicocele size.

**Conclusions:** Our study showed that ultrasonography findings can be a good predictor of sperm parameters in patients with varicocele.

**Keywords:** Sperm Analysis Parameters, Color Doppler Ultrasonography, Varicocele, Correlation

## 1. Background

Varicocele is the abnormal tortuosity and dilation of the testicular veins (the pampiniform plexus) of more than 2 mm caused by venous reflux in the testes (1-5). Varicocele occurs primarily on the left side and is more prevalent at young ages. The prevalence of palpable varicocele is 15% in the general male population and 21% - 39% in subfertile men (6-8). Varicocele is among the most common causes of reduced sperm count and quality, leading to infertility and subfertility (9). Physical examination is the standard diagnostic method for detecting varicocele, but the diagnosis of asymptomatic and impalpable varicocele is difficult. These conditions can be detected only by using ultrasonography (3). Venous reflux is an important standard for the diagnosis of varicocele because reflux of more than 1 s increases the likelihood of infertility (10).

Color Doppler ultrasonography (CDUS) is the most sensitive, non-invasive diagnostic method for diagnosing varicocele. It has a sensitivity of 93%, while clinical exam-

ination has a sensitivity of approximately 71% (11). CDUS evaluates varicocele based on venous diameter, the presence or absence of reflux, and other relevant factors.

## 2. Objectives

In this study, we explored the correlation between ultrasonography (US) and semen analysis parameters.

## 3. Methods

This cross-sectional study was conducted in a university hospital, and the local research and ethics committee approved the research protocol. Patients with clinically confirmed or suspected varicocele (n = 134) were recruited for the study. Informed consent was obtained from each participant. Patients with secondary varicocele, traumatic injury, other pathologic disorders of the testis (e.g. tumor, hydrocele, spermatocele), or inflammation of the

testis or epididymis were excluded. Using a Toshiba ultrasonography instrument (Tokyo, Japan) with a linear, multi-frequency probe (5 - 8.5 MHZ), a primary CDUS analysis was performed with all cases, and patients with venous diameters of more than 2 mm were selected for more analyses. Finally, 99 patients were selected for the study.

The selected cases were further evaluated using CDUS. The patients underwent normal scans using the Valsalva maneuver in the supine position. The evaluated parameters were the venous diameter of the pampiniform plexus, the presence or absence of venous reflux on both sides, and the longitude and transverse diameters of the testes. Reflux was quantified by duration and flow volume. Reflux of longer than 1 s was considered pathologic, while flow volume was calculated by multiplying the area by the mean velocity. Varicocele in the selected cases was classified as grade 0 (2-2.5 mm), grade 1 (2.5-3 mm), grade 2 (3-3.5 mm), or grade 3 (> 3.5 mm).

Then patients were referred to a laboratory for semen analysis, including semen volume and sperm morphology, count, and motility. Analysis was performed based on the world health organization laboratory manual issued in 1993 (9).

Statistical analysis was performed using the SPSS 17 package (Chicago, USA). The correlations between the variables were assessed using Spearman coefficients. The semen analysis parameters and CDUS findings for the samples with venous reflux of longer than 1 s and those with venous reflux of less than 1 s were compared between using student's t-test. P-values of less than 0.05 were considered to be significant.

#### 4. Results

This study was performed with 99 patients with varicocele confirmed by CDUS. The mean age of the selected patients was  $34.3 \pm 6.2$  years (range: 23 - 50 years). Among the participants, 19 had a history of cigarette smoking (19.2%), 12 a history of alcohol use (12.1%), and 9 (9.1%) a history of mumps, while 41 had a history of surgery (6 bilateral and 7 unilateral varicocele surgery). The results for testes size measured in two dimensions and varicocele size are summarized in Tables 1 and 2. All patients had left varicocele, while right varicocele was observed in 53 cases (Table 2). The average size of varicocele on the left side was significantly greater than that of right-side varicocele ( $P < 0.001$ ). Additionally, the grades of varicocele on the right and left sides were recorded. Most varicocele on both sides was grade 1 (42.4%) (Figure 1).

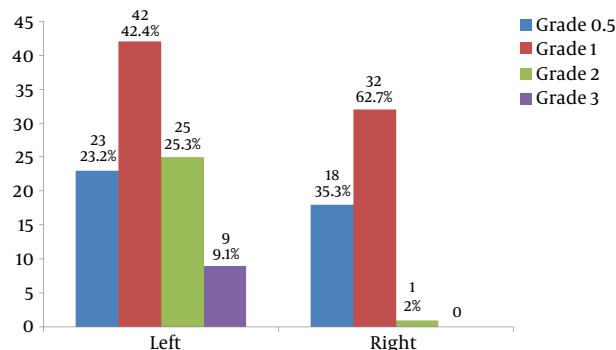
We also determined sperm analysis parameters, as summarized in Table 3. The average semen volume of participants was  $2.6 \pm 1.2$  mL, the average sperm motility was

**Table 1.** Statistics for Testes Size (mm) Measured Into Two Dimensions (L: Longitudinal, T: Transverse)

	N	Min	Max	Mean $\pm$ SD
Right testis size (L)	99	19.00	50.00	41.5152 $\pm$ 4.28420
Right testis size (T)	99	8.00	29.00	21.9000 $\pm$ 3.87877
Left testis size (L)	99	23.00	49.00	40.2929 $\pm$ 4.57645
Left testis size (T)	99	11.00	29.00	20.8889 $\pm$ 3.35605

**Table 2.** Statistics for Varicocele Size (mm) in Each Testis

	N	Min	Max	Mean $\pm$ SD
Left varicocele size	99	2.00	4.40	2.8323 $\pm$ 0.54969
Right varicocele size	53	2	3.30	2.4047 $\pm$ 0.41721



**Figure 1.** Frequency of Grades of Varicocele on Both Sides

$48.9 \pm 24.4\%$ , and the average sperm count was  $45.1 \pm 58.2$  million.

**Table 3.** Statistics for Sperm Analysis Parameters

	N	Min	Max	Mean $\pm$ SD
Semen volume, mL	65	0.50	7.80	2.6031 $\pm$ 1.22219
Total sperm motility, %	83	0.00	96.00	48.8955 $\pm$ 24.37332
Normal sperm morphology, %	83	0.00	83.00	16.0635 $\pm$ 17.86094
Count ( $\times 10^6$ )	86	0.00	437.00	45.0556 $\pm$ 58.24126

The correlation between the sperm analysis parameters and varicocele or testes size was calculated. The correlation coefficients between varicocele size and sperm count in the left and right testes were -0.6 and -0.7, respectively ( $P = 0.001$ ). The correlation coefficients between varicocele size and sperm motility in the left and right testes were -0.61 and -0.78, respectively ( $P = 0.035$ ). The cor-

relation coefficients between varicocele size and abnormal sperm morphology in the left and right testes were 0.53 and 0.74, respectively ( $P = 0.04$ ). The correlation coefficient between varicocele size and semen volume in the left and right testes was  $-0.61$  ( $P = 0.045$ ). The correlation coefficients of testes size with sperm count, sperm motility, abnormal sperm morphology, and semen volume were  $0.35 - 0.49$ ,  $0.3 - 0.48$ ,  $0.25 - 0.45$ , and  $0.15 - 0.25$ , respectively ( $P = 0.3$ ).

Seventy-one (71) of 99 patients with left varicocele (71.7%) had reflux of longer than 1 s, while 14 of 53 patients with right varicocele (26.4%) had reflux of longer than 1 s. The sperm analysis parameters, varicocele size, and testes size were compared between the samples with reflux of longer than 1 s and reflux of less than 1 s in each testis (Tables 4 and 5). For the left testis, the groups had significant differences in semen volume, motility, morphology, and count ( $P < 0.05$ ) but not testis size ( $P > 0.05$ ). Patients with reflux had significantly greater varicocele size than patients without reflux ( $P < 0.05$ ) (Table 4).

Similar findings were obtained for 14 patients with reflux of longer than 1 seconds on the right testis. For right-side varicocele, varicocele size was significantly greater in patients with reflux than patients without reflux ( $P < 0.05$ ). Right testis size was not significantly different between the two groups ( $P > 0.05$ ) (Table 5).

In this investigation, the cut-off point for diagnosis of varicocele was 2 mm and had acceptable sensitivity but not adequate specificity. Therefore, we decided to select a cut-off point with higher specificity, PPV, and NPV. Using statistical analysis, we determined that 2.6 mm was a reliable cut-off value to more effectively detect varicocele.

## 5. Discussion

We showed that semen analysis parameters, including semen volume and sperm morphology, count, and motility, had significant correlations with varicocele diameter but not testes size.

One study (12), which compared sperm analysis data and CDUS findings for 62 patients with varicocele, did not find any significant correlations between the analyzed parameters. This discrepancy with present results can be related to technical faults because ultrasonography is an operator-dependent technique. In addition, semen analysis results depend on the quality of the laboratory tools and technician's skills.

Two studies (13, 14) found that patients with spermatogenesis disorder had smaller testes. Although the present research also found a relationship between testes size and spermatogenesis disorder, this relationship was not statis-

**Table 4.** Comparison of Sperm Analysis Parameters and Color Doppler Ultrasonography Findings for Samples With Reflux Time of Longer or Less Than 1 seconds in the Left Testis

Left Varicocele Reflux of Longer Than 1 s	N	Mean $\pm$ SD	P Value
<b>Volume</b>			0.045
No	20	2.9 $\pm$ 1.3	
Yes	61	2.1 $\pm$ 1.1	
<b>Total motility</b>			0.03
No	22	60.8 $\pm$ 24.9	
Yes	64	40.7 $\pm$ 23.9	
<b>Morphology</b>			0.04
No	21	12.7 $\pm$ 16.3	
Yes	63	22.5 $\pm$ 19.6	
<b>Count</b>			0.02
No	25	55.8 $\pm$ 33.7	
Yes	60	32.4 $\pm$ 76.5	
<b>Right testis size 1</b>			0.6
No	28	41.7 $\pm$ 4.5	
Yes	71	41.3 $\pm$ 4.0	
<b>Right testis size 2</b>			0.36
No	28	23.9 $\pm$ 13.9	
Yes	71	22.0 $\pm$ 3.1	
<b>Left testis size 1</b>			0.3
No	28	40.8 $\pm$ 4.1	
Yes	71	39.8 $\pm$ 5.6	
<b>Left testis size 2</b>			0.38
No	28	21.2 $\pm$ 2.8	
Yes	71	20.6 $\pm$ 3.9	
<b>Left varicocele size</b>			< 0.001
No	28	2.5 $\pm$ 0.4	
Yes	71	3.2 $\pm$ 0.5	

tically significant, which might be due to the lack of a standard method for measuring testes size in this study.

In the present results, patients with reflux of longer than 1 seconds and those with reflux of less than 1 seconds had significantly different semen analysis parameters and varicocele size. Similar findings were reported by (15), who found a significant correlation between bilateral reflux and persistent reflux with sperm abnormalities.

Our inclusion criterion was varicocele diameter of more than 2mm, resulting in the exclusion of 35 men with a history of infertility from the study. However, further analysis revealed that a cut-off point of 2.6 mm in the supine position during the Valsalva maneuver was more

**Table 5.** Comparison of Testes Size and Color Doppler Ultrasonography Findings for Samples With Reflux Time of Longer or Less Than 1 s in the Left Testis

Right Varicocele Reflux of Longer Than 1 s	N	Mean $\pm$ SD	P Value
<b>Right testis size (L)</b>			0.25
No	85	41.8471 $\pm$ 3.52375	
Yes	14	39.5000 $\pm$ 7.28275	
<b>Right testis size (T)</b>			0.31
No	85	23.4235 $\pm$ 10.88618	
Yes	14	20.4286 $\pm$ 4.73472	
<b>Left testis size (L)</b>			0.45
No	85	40.4353 $\pm$ 4.36285	
Yes	14	39.4286 $\pm$ 5.82718	
<b>Left testis size (T)</b>			0.42
No	85	21.0000 $\pm$ 3.16228	
Yes	14	20.2143 $\pm$ 4.44070	
<b>Left varicocele size</b>			0.088
No	85	2.7941 $\pm$ 0.54097	
Yes	14	3.0643 $\pm$ 0.56515	
<b>Right varicocele size</b>			0.04
No	39	2.3397 $\pm$ 0.45914	
Yes	14	2.5857 $\pm$ 0.17913	

reliable and efficient at detecting patients with varicocele (14) used a cut-off point of 2.48 mm in the standing position without the Valsalva maneuver.

We recommend that patients with a varicocele diameter of less than 2 mm be evaluated for venous reflux because reflux can occur without increasing the diameter of the pampiniform vein.

## References

- Arslan H, Sakarya ME, Atilla MK. Clinical value of power Doppler sonography in the diagnosis of varicocele. *J Clin Ultrasound*. 1998;**26**(4):229. [PubMed: 9572392].
- Cornud F, Belin X, Amar E, Delafontaine D, Helenon O, Moreau JF. Varicocele: strategies in diagnosis and treatment. *Eur Radiol*. 1999;**9**(3):536-45. doi: 10.1007/s003300050706. [PubMed: 10087130].
- Keoghane SR, Kabala JE. Varicocele embolisation. *Imaging*. 2001;**13**(1):11-7. doi: 10.1259/img.13.1.130011.
- Sigmund G, Gall H, Bahren W. Stop-type and shunt-type varicoceles: venographic findings. *Radiology*. 1987;**163**(1):105-10. doi: 10.1148/radiology.163.1.3547489. [PubMed: 3547489].
- Heidari R, Alizadeh R, Abbasi N, Pasbakhsh P, Hedayatpour A, Farajpour M, et al. Do Pilea Microphylla Improve Sperm DNA Fragmentation and Sperm Parameters in Varicocelectomized Rats?. *Acta Med Iran*. 2015;**53**(9):547-54. [PubMed: 26553082].
- Gonda RJ, Karo JJ, Forte RA, O'Donnell KT. Diagnosis of subclinical varicocele in infertility. *AJR Am J Roentgenol*. 1987;**148**(1):71-5. doi: 10.2214/ajr.148.1.71. [PubMed: 3024475].
- Hoekstra T, Witt MA. The correlation of internal spermatic vein palpability with ultrasonographic diameter and reversal of venous flow. *J Urol*. 1995;**153**(1):82-4. doi: 10.1097/00005392-199501000-00029. [PubMed: 7966798].
- Meacham RB, Townsend RR, Rademacher D, Drose JA. The incidence of varicoceles in the general population when evaluated by physical examination, gray scale sonography and color Doppler sonography. *J Urol*. 1994;**151**(6):1535-8. [PubMed: 8189565].
- Franken DR, Acosta AA, Kruger TF, Lombard CJ, Oehninger S, Hodgen GD. The hemizona assay: its role in identifying male factor infertility in assisted reproduction. *Fertil Steril*. 1993;**59**(5):1075-80. [PubMed: 8486177].
- Mihmanli I, Kurugoglu S, Cantasdemir M, Zulfikar Z, Halit Yilmaz M, Numan F. Color Doppler ultrasound in subclinical varicocele: an attempt to determine new criteria. *Eur J Ultrasound*. 2000;**12**(1):43-8. [PubMed: 10996769].
- Goldberg S. Diagnostic ultrasound. Philadelphia: Lippincott-Raven; 1998.
- Ghafoori M, Rostampour A. Evaluation of the Relation of Diameter and Reflux to Sperm Analysis in Varicocele Patients in Hashemi Nejad Hospital in the year 2003. *Razi J Med Sci*. 2006;**13**(5):157-64.
- Keene DJ, Sajad Y, Rakoczy G, Cervellione RM. Testicular volume and semen parameters in patients aged 12 to 17 years with idiopathic varicocele. *J Pediatr Surg*. 2012;**47**(2):383-5. doi: 10.1016/j.jpedsurg.2011.11.035. [PubMed: 22325396].
- Akhavan Rezayat K, Mansour Ghanaei F, Alizadeh A, Shafaghi A, Babaei Jandaghi A. Doppler surrogate endoscopy for screening esophageal varices in patients with cirrhosis. *Hepat Mon*. 2014;**14**(1):ee11237. doi: 10.5812/hepatmon.11237. [PubMed: 24497873].
- Tahmasbi M, Assare E. Quantitative doppler assessment of flow characteristics in pampiniform venous plexus, in patients with varicocele: Is there any relationship with semen analysis?. *PJR*. 2016;**20**(3).

# SID



سرویس های ویژه



سرویس ترجمه تخصصی



کارگاه های آموزشی



بلاگ مرکز اطلاعات علمی



عضویت در خبرنامه



فیلم های آموزشی

## کارگاه های آموزشی مرکز اطلاعات علمی جهاد دانشگاهی



PROPOSAL  
پروپوزال

پروپوزال نویسی و پایان نامه نویسی

دکتره تهرانی

کارگاه آنلاین  
پروپوزال نویسی و پایان نامه نویسی



روش تحقیق و مقاله نویسی علوم انسانی

دکتره تهرانی

کارگاه آنلاین  
روش تحقیق و مقاله نویسی علوم انسانی



ISI  
Scopus

آشنایی با پایگاه های اطلاعات علمی بین المللی و ترند های جستجو

دکتره تهرانی

کارگاه آنلاین آشنایی با پایگاه های اطلاعات علمی بین المللی و ترند های جستجو