

A CASE REPORT OF PRIMARY LOCALIZED AMYLOIDOSIS OF EYELID WITH EXTENSIVE CALCIFICATION AND OSSIFICATION, CLINICALLY PRESENTING AS A BONE TUMOR

F. Asadi-Amoli*, N. Rabie and S. Z. Tabatabaie-Mohammadi

Department of Pathology, Farabi Eye Hospital, School of Medicine, Tehran University of Medical Sciences, Tehran, Iran

Abstract- Primary localized amyloidosis of eyelid is a localized type of amyloidosis without evidence of systemic involvement. We report a 75-year-old man suffering of unilateral (left) ptosis due to upper eyelid mass with bony consistency. Eye examination revealed upper lid mass attached to tarsus. No ocular infection or inflammation was found. Pathologist reported diffuse distribution of eosinophilic homogenous deposits of stroma that show apple green birefringence by polarized light compatible with amyloidosis. Primary localized amyloidosis may appear as a bony tumoral mass. It is important to consider secondary localized and systemic amyloidosis in differential diagnosis of the disease.

© 2008 Tehran University of Medical Sciences. All rights reserved.

Acta Medica Iranica 2008; 46(4): 342-344.

Key words: Amyloidosis, eyelid, Congo-red staining

INTRODUCTION

Amyloid is an extracellular eosinophilic homogeneous matrix material that can be deposited in connective tissues and blood vessels anywhere in the body (1-3). This tissue change may have many different causes that are grouped under the term amyloidosis (1). Amyloidosis is classified as systemic and localized (1, 4, 5). In systemic amyloidosis multiple organs may be involved but in localized amyloidosis only one body organ is involved. Primary amyloidosis is an uncommon condition (1, 6, 7) without any systemic or antecedent disorder. Secondary amyloidosis is preceded by chronic inflammatory conditions such as rheumatoid arthritis or is associated with plasma dyscrasia (1).

Primary localized amyloidosis of eyelid develops slowly in healthy, young or middle age (occasionally elderly) persons on a hereditofamilial basis without evidence of systemic amyloidosis (1, 7). It may be followed by ptosis (1, 7-9). In differential diagnosis, secondary localized amyloidosis due to longstanding chronic inflammation like trachoma and systemic amyloidosis must be considered (1, 10).

CASE REPORT

A 75-year-old man referred to Farabi Eye Hospital suffering from unilateral ptosis due to left upper eyelid mass with palpebral conjunctival (tarsal) attachment. He didn't have any systemic symptoms and signs (Fig. 1). Mass had a bony consistency. Eye examination revealed no ocular/visual infection and inflammation. The patient had no systemic signs and symptoms and all hematologic and biochemistry laboratory tests were within normal limits.

Received: 8 Oct. 2006, Revised: 31 Oct. 2006, Accepted: 18 Dec. 2006

*** Corresponding Author:**

Fahimeh Asadi-Amoli, Department of Pathology, Farabi Eye Hospital, School of Medicine, Tehran University of Medical Sciences, Tehran, Iran
Tel: +98 21 5540003-8
Fax: +98 21 55418080
E-mail: path1383@yahoo.com




Fig. 1. A 75-year-old man suffering from unilateral ptosis due to left upper eyelid mass.

First, an incisional biopsy of left eye mass was performed for the patient. In this procedure a tumor with very hard consistency on the tarsus was seen. Tumor and attached conjunctival area were biopsied. The specimens were sent to pathology laboratory, then incision was sutured with 6/0 nylon. After ten days, in second surgery, Weise procedure (blepharotomy) was performed.

The specimen received in formalin solution consisted of two creamy yellow colored tissues with hard and bony consistency measuring $0.7 \times 0.4 \times 0.2$ and $0.3 \times 0.2 \times 0.1$ cm, respectively, totally embedded in one block. Microscopical findings showed amorphous eosinophilic pale hyaline deposits, foci of calcification, extensive foci of ossification near the hyaline area (Fig. 2 and 3) and apple green birefringence in Congo-red staining with polarized light in subepidermal area of eyelid extending to subconjunctival stroma (Fig. 4).

We obtained informed consent to publish details of the patient's history and his picture.

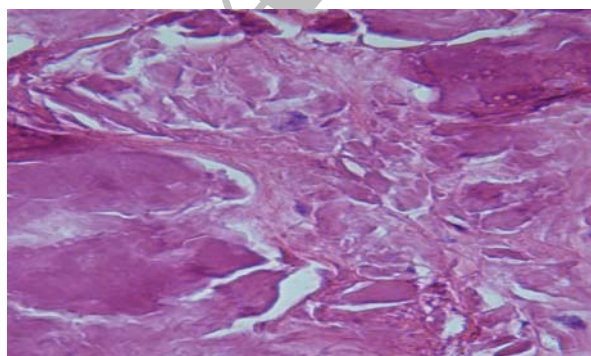


Fig. 2. Hyaline deposits with foci of calcification. H & E stain $\times 400$.

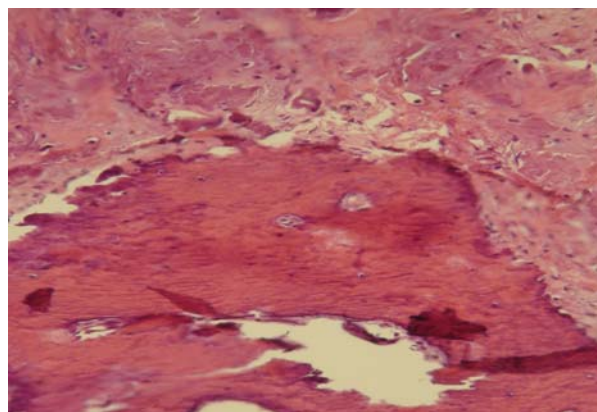


Fig. 3. Hyaline deposits with foci of ossification. H & E stain $\times 400$.

DISCUSSION

Primary localized amyloidosis of eyelid manifest as unilateral or bilateral solitary or multiple firm, rubbery, waxy appearing painless fusiform or polypoid elevations (1, 5-7). It can be found in young or middle-aged, and occasionally, elderly persons. It develops slowly and in some cases the conjunctiva is diffusely thickened and slightly hyperemic (1, 11-14). Ptosis occurs when the deposits involve the upper tarsal conjunctiva or the levator muscles (1, 7-9).

Histopathological findings in our case were compatible with amyloidosis. It seems that ossification and calcification were significant due to chronicity. Systemic examination and all laboratory tests were normal which excludes systemic amyloidosis. Also, the only localized symptom or sign was ptosis due to upper lid mass attached to tarsus, making the diagnosis of secondary amyloidosis unlikely.

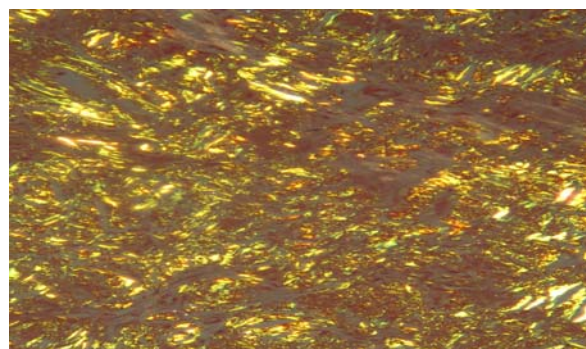


Fig. 4. Amyloid material with apple green birefringence in Congo-red staining.

REFERENCES

1. Spencer WH. Ophthalmic pathology: an atlas and textbook. 4th edition. Philadelphia: WB Saunders; 1996. P. 2367-2370.
2. Kosch G, Meyer-Rüsenberg HW. [Primary localized amyloidosis of the eyelid and conjunctiva]. *Klin Monatsbl Augenheilkd*. 1993 Jan; 202(1):56-59. German.
3. Mahajan D, Yadava U, Khurana N, Goyal JL. Primary localised nodular amyloidosis of the eyelid and conjunctiva: a case report. *Pathology*. 2006 Apr; 38(2):189-190.
4. Iijima S. Primary systemic amyloidosis: a unique case complaining of diffuse eyelid swelling and conjunctival involvement. *J Dermatol*. 1992 Feb;19(2):113-118.
5. Chaturvedi P, Lala M, Desai S, Sanghvi V. A rare case of both eyelids swelling: isolated conjunctival amyloidosis. *Indian J Ophthalmol*. 2000 Mar;48(1):56-57.
6. Roldrigues G, Sanghvi V, Lala M. Conjunctival amyloidosis of both eyelids. *Indian J Ophthalmol*. 2001 Jun; 49(2): 116-117.
7. Rodrigues G, Sanghvi V, Lala M. A rare cause of unilateral upper and lower eyelid swelling: isolated conjunctival amyloidosis. *Korean J Ophthalmol*. 2001 Jun; 15(1):38-40.
8. Laouissi N, Rais L, Zemiati S, Elbelhadji M, Alibou F, Bounkind E, Laraqi A, Zaghoul K, Amraoui A. [Isolated and primary palpebro-conjunctival amylosis. Apropos of 2 cases]. *J Fr Ophtalmol*. 1998 Feb; 21(2):152-155. French.
9. Hill VE, Brownstein S, Jordan DR. Ptosis secondary to amyloidosis of the tarsal conjunctiva and tarsus. *Am J Ophthalmol*. 1997 Jun;123(6):852-854.
10. Sainz-Esteban A, Saornil-Alvarez MA, Méndez-Díaz MC, Blanco-Mateos G. [Primary localized conjunctival amyloidosis: two case reports]. *Arch Soc Esp Oftalmol*. 2005 Jan;80(1):49-52. Spanish.
11. Demirci H, Shields CL, Eagle RC Jr, Shields JA. Conjunctival amyloidosis: report of six cases and review of the literature. *Surv Ophthalmol*. 2006 Jul-Aug; 51(4):419-433.
12. Shields JA, Eagle RC, Shields CL, Green M, Singh AD. Systemic amyloidosis presenting as a mass of the conjunctival semilunar fold. *Am J Ophthalmol*. 2000 Oct;130(4):523-525.
13. Blodi FC, Apple DJ. Localized conjunctival amyloidosis. *Am J Ophthalmol*. 1979 Sep;88(3 Pt 1):346-350.
14. Davis J, Grimmer D, Woosley JT. Amyloid plaque of the lower eyelid: a patient report and review of the literature. *Ann Plast Surg*. 1993 Apr;30(4):350-353.