

External Ocular Manifestation of Wolfram Syndrome

M Mehdizadeh^{1*}, M Mosallaei², A Borhani Haghghi³

¹Department of Ophthalmology, ²Comparative Medicine Research center, Department of Neurology, Shiraz University of Medical Sciences, Shiraz, Iran

Abstract

Wolfram syndrome is a neurodegenerative disorder usually diagnosed in childhood. The ocular manifestation of wolfram syndrome is mainly characterized by bilateral optic atrophy; however, pigmentary retinopathy has been reported in some cases. We present a case with new external ocular manifestation of wolfram syndrome not previously reported in the literature. A 22-year-old retarded man clinically diagnosed as having wolfram syndrome presented with ocular discomfort in his both eyes for a 4-year period, being aggravated recently. On examination, he was emmetrope with best corrected visual acuity of about two meter count finger in each eye. Pupillary response was sluggish but equal in both eyes. Ocular motility was normal and there was no considerable sign of nystagmus; however, there were disturbed blinking reflex, lagophthalmus, and poor bell's phenomenon. Slit lamp examination showed bilateral symmetrical saucer-like depression of the corneal surface adjacent to the limbos that is known to be deled formation. The result of Schemer test was out of the normal limit, in favor of dry eye. So, dry eye due to blinking disturbances in patients with wolfram syndrome as a neurodegenerative disorder may lead to external ocular manifestations, requiring conservative treatments.

Keywords: Wolfram syndrome; Neurodegenerative disorder; Dry eye; Dellen formation

Introduction

Wolfram syndrome is a neurodegenerative disorder usually diagnosed in childhood. Optic atrophy combined with diabetes mellitus, diabetes insipidus and deafness are the main features known by the acronym DIDMOAD (diabetes insipidus, diabetes mellitus, optic atrophy, deafness).^{1,2} Both mitochondrial and autosomal recessive patterns of inheritance have been pertained to this problem.³ The ocular manifestation of wolfram syndrome is typically but not invariably demonstrated by bilateral optic atrophy; however, other posterior segment involvements such as pigmentary retinopathy have been reported less frequently.⁴ Here, we present a case with new external ocular manifestation of wolfram syndrome which has not been previously reported in the literature.

Case Report

A 22-year-old mentally retarded man with growth retardation clinically diagnosed as having wolfram syndrome presented with the chief complaint of ocular discomfort in his both eyes for a 4-year period, being aggravated recently. He was also suffering from low vision which began when he was six years old. His medical history was also significant for subsequent onset of diabetes mellitus when he was 11. A recent history of hearing loss and neurological problems led to several episodes of hospital admissions. On examination, he was emmetrope with best corrected visual acuity of about two meter count finger in each eye. Pupillary response was sluggish but equal in his both eyes. Ocular motility was normal and there was no sign of nystagmus; however, there were disturbed blinking reflex, lagophthalmus and poor bell's phenomenon. Other neurological exams showed relative involvement of cranial nerves III, IV and VI as evidenced by mild hesitance of motion as well as delayed saccades. In addition, pure tone audiometry was in favor of moderate to severe high tone loss on ears. Slit lamp examination showed bilateral symmetrical 1×2 mm sized saucer-like depression of

*Correspondence: Morteza Mehdizadeh, MD, Assistant professor of Department of Ophthalmology, Khalili Hospital, School of Medicine, Shiraz University of Medical Sciences, Shiraz, Iran. Tel: +98-711-2302830, Fax: +98-711-2302830, e-mail: mehdizadeh@sums.ac.ir
Received: May 17, 2008 Accepted: November 9, 2008

the corneal surface adjacent to the limbus with overlying epithelium exhibition of punctuates irregularities. (Figure 1)

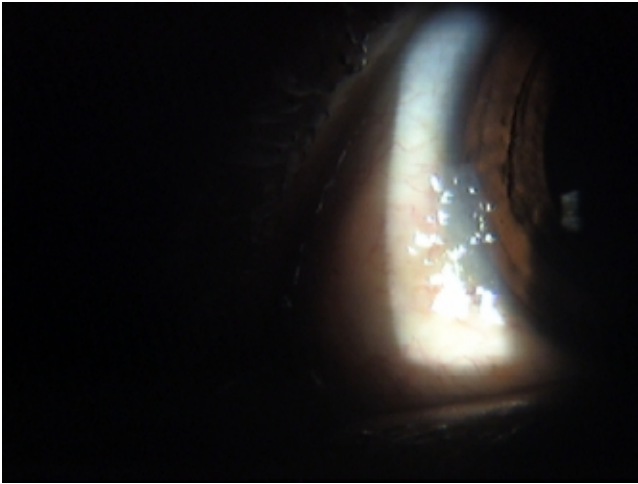


Fig 1: A 1×2 mm sized saucer like depression of corneal surface adjacent to the limbus with overlying epithelium exhibition of punctuates irregularities. (Dellen formation)

The result of Schermer test was out of normal limit (<5 mm). Fundus examination was in favor of bilateral symmetrical optic disk atrophy with partial absence of the normal neuroretinal rim. According to the clinical and paraclinical findings, dry eye was diagnosed, lubricant medication was prescribed, and the patient's symptoms were relieved within a few weeks.

Discussion

Wolfram syndrome is an extremely rare disorder of multiple endocrinological and also neurological problems which leads to progressive optic atrophy. This syndrome was initially believed to be caused by mitochondrial mutations but recently the genetic basis of this problem has been shown to be due to mutations in the gene mapped on chromosome 4 at a gene locus as well, producing a novel trans-membrane protein of the calcium channel in pancreatic B-cells and neurons.^{1,4}

Although it is mainly considered as a hereditary genetic disorder, the complex interrelationships between genomic expression and unknown environmental factors may alter the time of the onset of symptoms and the extent to which they are manifested. In other words, it has variable expressions due

to both genetic and environmental factors.³ As mentioned before, optic nerve atrophy and retinal pigmentary changes are known ocular manifestations of wolfram syndrome with variable expressions and time of onset;^{4,5} however, to our knowledge, there is nothing in the literature indicating the corneal involvement. Dry eye is a very common disorder of the tear film originating from either decreased tear production or excessive evaporation owing to blinking problem. While dry eye leads to progressive ocular surface problem, irregularities of the ocular surface can also make the tear film more unstable, creating a vicious cycle aggravating the condition.⁶⁻⁸ Blinking disorder is also one of the contributing factors in dry eye. As wolfram syndrome is a neurodegenerative disorder resulting in both peripheral and central nervous system problems, polyneuropathy and multiple cranial nerve involvements are one of the prominent features of this syndrome.⁹ However, the sequence of involvement is not predictable and may be influenced by many unknown factors. In the present case, the absence of nystagmus in the face of low vision was related to the later onset of optic atrophy which was about 5-6 years. Moreover, poor blinking reflex and lagophthalmus may originate from the pathology of both 5th and 7th cranial nerves as well as diabetes mellitus. As a result, in the present case moderate to severe dry eye and the subsequent irregularity of the ocular surface led to depression in the epithelium and subepithelial tissue just adjacent to the limbus. This corneal thinning of the stroma and epithelium, due to surface irregularities, is called Dellen formation as was the case here. Moreover, as expected, the bilateral and symmetrical manifestation of ocular problem could be explained only by its underlying systemic problem.⁸

In conclusion, since wolfram syndrome is a sophisticated entity according to its progressive and irreversible sequel, considering the best conservative management of patients' symptoms such as dry eye, should be considered as one of the main goals of treatment besides other visual rehabilitations.

Acknowledgment

The authors wish to thank the Ophthalmology Research Center for their cooperation.

Conflict of interest: None declared.

References

- 1 Esteban Bueno G, Gómez Trujillo FM. Clinical manifestations and diagnostic delay in Wolfram's syndrome. *Rev Clin Esp* 2006;**206**:332-5. [16831380] [doi:10.1157/13090481]
- 2 Shiono T, Noro M, Abe S. A long-term follow-up of a patient with DIDMOAD (Wolfram) syndrome. *Nippon Ganka Gakkai Zasshi* 1991;**95**:294-7. [1872208]
- 3 Smith CJ, Crock PA, King BR, Meldrum CJ, Scott RJ. Phenotype-genotype correlations in a series of wolfram syndrome families. *Diabetes Care* 2004;**27**:2003-9. [15277431] [doi:10.2337/diacare.27.8.2003]
- 4 Dhalla MS, Desai UR, Zuckerbrod DS. Pigmentary maculopathy in a patient with Wolfram syndrome. *Can J Ophthalmol* 2006;**41**:38-40. [16462870]
- 5 Medlej R, Wasson J, Baz P, Azar S, Salti I, Loiselet J, Permutt A, Halaby G. Diabetes mellitus and optic atrophy: a study of Wolfram syndrome in the Lebanese population. *J Clin Endocrinol Metab* 2004;**89**:1656-61. [15070927] [doi:10.1210/jc.2002-030015]
- 6 Fahnehjelm KT, Törnquist AL, Winiarski J. Dry-eye syndrome after allogeneic stem-cell transplantation in children. *Acta Ophthalmol* 2008;**86**:253-8. [18093259] [doi:10.1111/j.1600-0420.2007.01120.x]
- 7 Ng LH. Central corneal epitheliopathy in a long-term, overnight orthokeratology lens wearer: a case report. *Optom Vis Sci* 2006;**83**:709-14. [17041315] [doi:10.1097/01.opx.0000236813.39603.49]
- 8 Lazic SE, Goodman AO, Grote HE, Blakemore C, Morton AJ, Hannan AJ, van Dellen A, Barker RA. Olfactory abnormalities in Huntington's disease: decreased plasticity in the primary olfactory cortex of R6/1 transgenic mice and reduced olfactory discrimination in patients. *Brain Res* 2007;**1151**:219-26. [17400200] [doi:10.1016/j.brainres.2007.03.018]
- 9 Ito S, Sakakibara R, Hattori T. Wolfram syndrome presenting marked brain MR imaging abnormalities with few neurologic abnormalities. *AJNR Am J Neuroradiol* 2007;**28**:305-6. [17297000]