

Xerografting as a Novel Procedure in the Management of Syngnathia

Hamid Reza Foroutan¹, Behzad Rahsepar²,
Mohammad Hossin Eghbal³, Ali Rahimi²,
Ali Bahador¹, Afshin Amini³,
Seid Mohammad Vahid Hosseini¹,
Mohammad Sadegh Honarpisheh⁴,
Ali Foroutan⁵, Shahrbanoo Shahbazi³,
Seid Abbas Banani¹

Abstract

Congenital fusion of the maxilla and the mandible is a rare condition. The extent of the problem ranges from simple mucosal adhesion (synechia) to severe bony fusion (syngnathia). Here we present a patient with zygomatico-mandibular fusion who was treated at neonatal and infancy periods at three different stages without tracheostomy. Having had recurrence for two times, porcine grafting was performed as a novel procedure to increase the chance of success. Ultimately the patient had uneventful outcome for 6 months after the last operation.

Iran J Med Sci 2009; 34(1): 68-71.

Keywords • Syngnathia • congenital bony syngnathia • mandible • maxillomandibular

Case Report

A one-day-old full-term Afghani female (weight: 3500g) was referred to Nemazee hospital due to a congenitally closed mouth (figure 1). The upper and lower jaws were fused together with no visible slit anteriorly. The patient was irritable without respiratory distress. Heart and breathing sounds were normal, and the abdomen was soft. Blood gas analysis and serum electrolytes were normal. Nasogastric tube number 8 was passed easily. Three dimensional spiral computed tomography (CT) revealed zygomatico-mandibular fusion posteriorly. The temporomandibular joints (TMJ) were normal (figure 2). The patient had no other congenital anomalies.

The feeding by tube was continued for 10 days after which she was scheduled for operation.

Under deep sedation and analgesia with incremental midazolam [0.1 mg/kg intravenously (iv)] and fentanyl (1 µg, iv) nasal intubation with guide of fiberoptic bronchoscope was tried but failed due to instrumental defect. Then blind nasal intubation was tried but it failed as well. Subsequently, while oxygen saturation, heart rate, and blood pressure were fully monitored, incremental dose of midazolam and fentanyl was continued and lidocaine was injected locally. Thereafter, a nasopharyngeal tube was inserted through the nose into the hypopharynx for oxygenation and a suction catheter was inserted for prevention of aspiration. During operation, the vital signs were stable without any sign of hypoxia, bradycardia, or tachycardia. Examination of the mouth showed a very narrow slit anteriorly and complete bony fusion posteriorly. The fusions were separated by an osteotome. At this condition, the mouth could be well opened and the patient was intubated nasally. The patient tolerated the operation and was taken to neonatal intensive care unit (NICU). She was extubated after 24 hours.

¹Department of Pediatric Surgery,

²Maxillofacial Surgery,

³Anesthesiology, ⁴Otolaryngology,

⁵Medical Student, Namazee Hospital, Shiraz University of Medical Sciences, Shiraz, Iran.

Correspondence:

Hamid Reza Foroutan MD,
Department of Pediatric Surgery,
Shiraz University of Medical Sciences,
Shiraz, Iran.

Tel/Fax: +98 711 6125161

Email: foroutanh@sums.ac.ir

Submitted: 18 February 2008

Revised: 31 May 2008

Accepted: 30 November 2008

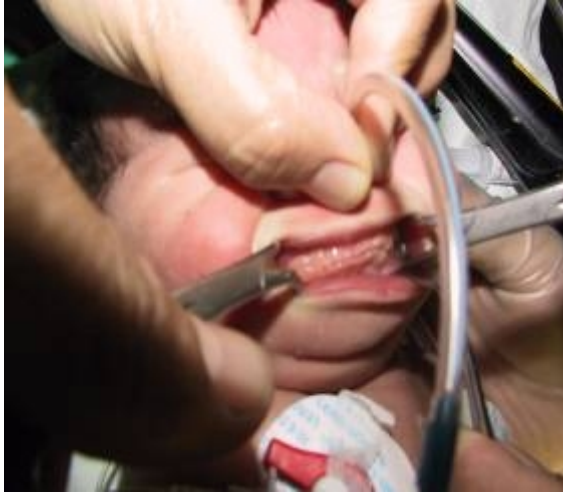

Figure 1: One-day-old boy with fused jaw.

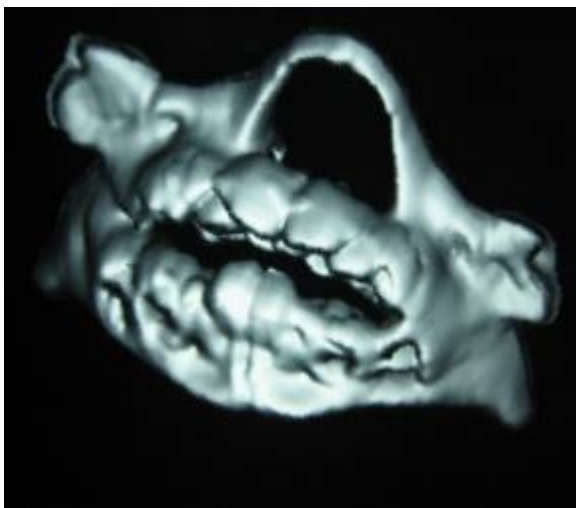
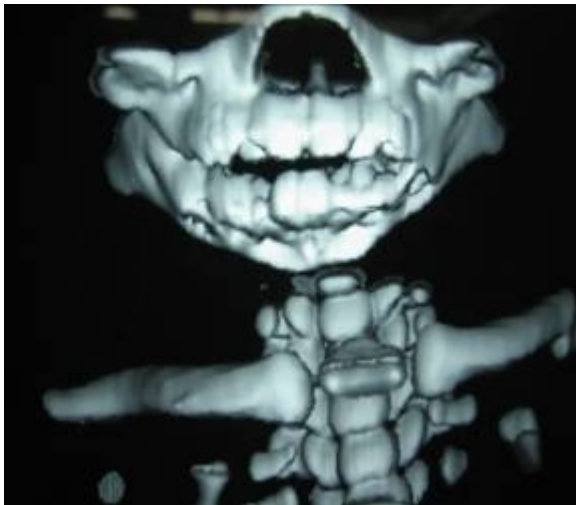

Figure 2: Three dimensional preoperative tomogram showing posterior maxillomandibular bony fusion.

Breast feeding was started 1 day later with good sucking and the patient was discharged. Three dimensional CT showed well separated jaws (figure 3).

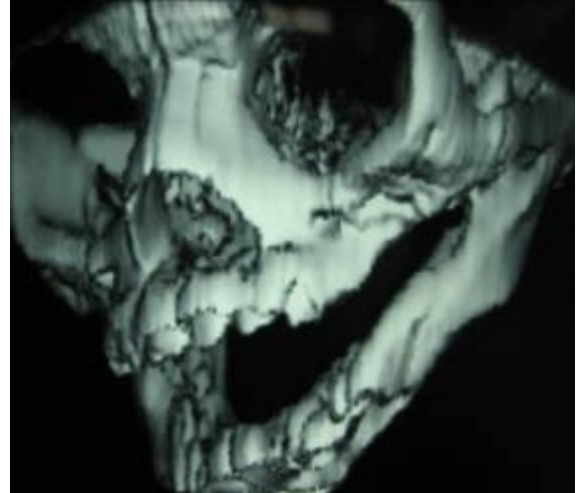

Figure 3: Postoperative three dimensional tomogram showing well separated jaws.

Three weeks later, the patient was brought back to the hospital because of difficulty in adequately opening the mouth as a result of re-fusion of the jaws. The patient was once again transferred to the operating room. She was easily intubated through the mouth. Thick bony re-fusion had occurred posteriorly. Thus re-osteotomy was performed. Two half cylinder tubes were sutured over the site of osteotomy on the mandible to prevent re-adhesion (figure 4).

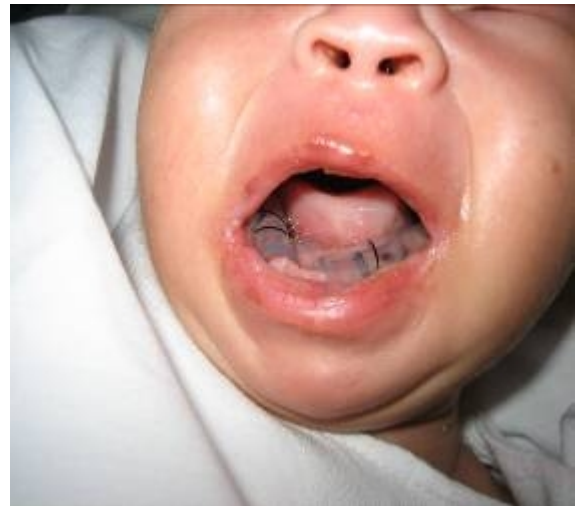

Figure 4: Postoperative appearance with full opening of the mouth. Rubbers were sutured to the mandible to prevent re-fusion of the jaws.

Daily mouth opening exercise was performed by finger and mouth gag induction to prevent re-fusion. Forceful manual opening was also performed once a week under general anesthesia for 2 months. At the age of 3 months, owing to decreased range of mouth opening (3 cm declining to 2 cm), excision of the fibrous tissues of the masseter muscles at the site of zygomatico-mandibular fusion was

performed. To prevent re-fusion, Xerograft was sutured over the bared area with 5-0 polydioxanone (PDS). At the latest regular follow up when she was 8 months old, the mouth could be opened up to 3 cm. Unfortunately, further follow-up was not possible as the parents returned to Afghanistan.

Discussion

Syngnathia (congenital fusion of jaws) is an extremely rare disorder. To date, less than 30 cases have been reported in the English-language literature. The fusion can be complete, unilateral, or similar to our patient, bilaterally fused posteriorly with an anterior slit. Soft tissue adhesion is more common than bony fusions. TMJs and muscles of mastication are generally normal,¹ although the presented case had some fibrous fusion of the masseter muscle. Associated anomalies may or may not be present. Our patient had no other anomaly. However, aglossia,²⁻⁴ agenesis or hypoplasia of proximal mandible,⁵ TM ankylosis, cleft palate,^{6,7} vertebral segmentation defect,⁸ eye anomalies, coloboma,^{9,10} and mental retardation,⁸ may accompany syngnathia. Furthermore, this condition may be associated with other syndromes including Van der Woude, popliteal pterygium, orofacial digital, and cleft palate lateral synechia.^{1,11,12}

The etiology of syngnathia is unknown. The theories include in growth of ectoderm or abnormal developmental process,¹³ abnormal stapedial artery,¹⁴ early loss of neural crest,¹⁵ teratogenic agents, or even trauma.¹⁶ Kamala and co-workers proposed that persistence of the bucco-pharyngeal membrane is the main mechanism of syngnathia while Verloes et al. believed in genetic etiology.^{17,8} Environmental insults, drugs such as meclizine or large doses of vitamin A are also additional causes.¹⁸

There have been different approaches to these patients for anesthesia. These include tracheostomy,¹⁹ intubation with the guide of fiberoptic bronchoscope,²⁰ or blind nasal intubation.¹² Fiberoptic bronchoscopy and blind nasal intubation were tried for our patient, which both failed. Therefore, the procedure had to be performed under local anesthesia while she was deeply sedated and a nasopharyngeal tube was also inserted for oxygenation. Patel et al. performed the procedure without anesthesia.²¹ However, this policy is not recommended by most surgeons.

Timing of surgical corrections in many reported cases is beyond infancy. Nonetheless, it has been occasionally performed in early infancy. During this time, before definitive proce-

sure, the patient would receive total parenteral nutrition or feeding by NG.^{22,23} However, owing to restrictive growth, this delay may cause major deformities of the mandible, which results to the need for multiple reconstructive procedures. The delay will also causes failure to thrive and severe malnutrition and dental deformities.²⁴

In addition, gastroesophageal reflux is also common in neonates and infants and regurgitation occurs frequently. Delaying the operation in the patients with complete closed mouth will endanger them to aspiration.

The presented case was operated at newborn age (10 days after birth) without tracheostomy. Early feeding started by mouth post-operatively. Despite daily mandibular manipulation by the mother, re-fusion occurred within 2 weeks. For this reason, re-osteotomy had to be performed to encounter with the problem. Therefore, due to limitation of mouth opening secondary to soft tissue refusion, the patient underwent re-operation for the third time for release and division of masseter muscle. To prevent re-adhesion of the jaws, as a novel procedure, xerografts were sutured to the mandible at the end of the last operative session. Furthermore, daily mouth opening was performed, followed by weekly forceful manipulation under general anesthesia resulting in ultimately excellent outcome. If the xerograft (porcine skin) had been used at the first or second operative session, the recurrence could probably have prevented.

In conclusion, operative management of syngnathia should not be delayed. Surgical intervention, particularly in the absence of major anomalies should preferably be performed at the neonatal period. If nasal intubation failed, tracheostomy can still be avoided. However, sedation and local anesthesia may be helpful. Close follow up, daily mouth opening exercise, and forceful manipulation under general anesthesia for few weeks are highly recommended if re-fusion is to be avoided. To prevent recurrence, xerograft particularly in those requiring osteotomy with low range of mouth opening (less than 2 cm) may be useful.

Conflict of Interest: None declared

References

- 1 Tomlinson JK, Liem NT, Savarirayan R, Meara JG. Isolated and Syndromic Syngnathism management, implications, and genetics. *Ann Plast Surg* 2006; 57: 231-5.
- 2 Alvarez GE. The aglossia-adactylia syndrome. *Br J Plast Surg* 1976; 29:175-8.
- 3 Arshad R, Goh CS. Hypoglossia congenita

- with anterior maxillomandibular fusion. *Br J Plast Surg* 1994; 47: 139-41.
- 4 Hoggins GS. Aglossia congenita with bony fusion of the jaws. *Br J Oral Surg* 1969; 7: 63-5.
 - 5 Brown DM, Marsh JL. Agnathia and associated malformations: a case report. *Cleft Palate J* 1990; 27: 415-8.
 - 6 Shah RM. Palatomandibular and maxillo-mandibular fusion, partial aglossia and cleft palate in a human embryo. Report of a case. *Teratology* 1977; 15: 261-72.
 - 7 Uğurlu K, Turan T, Urganci N, et al. Fusion of maxillary and mandibular alveolar process together with a median mandibular cleft: a rare congenital anomaly. *J Cranio-maxillofac Surg* 1999; 27: 105-8.
 - 8 Verloes, Raoul M, Genevieve D, et al. Bony syngnathia, vertebral segmentation defect, coloboma, microcephaly and mental retardation: confirmation of Dobrow syndrome and review of syndromal syngnathias. *Clinical Dysmorphology* 2004; 13: 205-11.
 - 9 Behnia H, Shamse MG. Congenital unilateral fusion of the mandibular and maxillary alveolar ridge, tempo romandibular joint, and coronoid process. *J Oral Maxillofac Surg* 1996; 54: 773-6.
 - 10 Goodacre TE, Wallace AF. Congenital alveolar fusion. *Br J Plast Surg* 1990; 43: 203-9.
 - 11 Hamamoto J, Matsumoto T. A case of facio-genito-popliteal syndrome. *Ann Plast Surg* 1984; 13: 224-229.
 - 12 Seraj MA, Yousif M, Channa AB. Anaesthetic management of congenital fusion of the jaws in a neonate. *Anaesthesia* 1984; 39: 695-8.
 - 13 Snijman PC, Prinsloo JG. Congenital fusion of the gums. Case report. *Am J Dis Child* 1966; 112: 593-5.
 - 14 Poswillo D. The pathogenesis of the first and second branchial arch syndrome. *Oral Surg Oral Med Oral Pathol* 1973; 35:302-28.
 - 15 Turvey TA, Hegtvedt AK. Surgical correction of craniofacial malformations. *J Oral Maxillofac Surg* 1993; 51: 69-81.
 - 16 Laster Z, Temkin D, Zarfin Y , Kushnir A. Complete bony fusion of the mandible to the zygomatic complex and maxillary tuberosity: case report and review. *Int J Oral Maxillofac Surg* 2001; 30: 75-9.
 - 17 Pillai KG, Kamath VV, Kumar GS, Nagamani N. Persistent buccopharyngeal membrane with cleft palate. A case report. *Oral Surg Oral Med Oral Pathol* 1990; 69: 164-6.
 - 18 Nanda R. Maxillomandibular ankylosis and cleft palate in rat embryos. *J Dent Res* 1970; 49: 1086-90.
 - 19 Simpson JR, Maves MD. Congenital syngnathia or fusion of the gums and jaws. *Otolaryngol Head Neck Surg* 1985; 93: 96-9.
 - 20 Alfery DD, Ward CF, Harwood IR, Mannino FL. Airway management for a neonate with congenital fusion of the jaws. *Anesthesiology* 1979; 51: 340-2.
 - 21 Patel V, Theroux MC, Reilly J. Popliteal pterygium syndrome with syngnathia. *Paediatr Anaesth* 2003; 13: 80-2.
 - 22 Salleh NM. Congenital partial fusion of the mandible and maxilla: report of the case. *Oral Surg Oral Med Oral Pathol* 1965; 20: 74-6.
 - 23 Spencer J, Daniels M. Congenital maxillo-mandibular fusion: a case report and review of the literature. *Journal of Cranio-Maxillofacial Surgery* 2004; 32: 135-9.
 - 24 Shams MG, Motamedi MH, Abad HL. Congenital fusion of the maxilla and mandible: brief case report. *Oral Surg Oral Med Oral Pathol Oral Radiol Endod* 2006; 102: e1-3.